

# Cardiovascular Research

Published since 1967

**Editor-in-Chief:**  
Tomasz J. Guzik

**Deputy Editors:**  
Charalambos Antoniades, UK  
Andrew Baker, UK  
Ali J. Marian, USA  
Karlheinz Peter, Australia  
Eva van Rooij, Netherlands

**Executive Deputy Editors:**  
Christopher Loughrey  
Pasquale Maffia  
Stuart Nicklin

EuroThrombosis & EuroVessels 2022

ESC Working Group on Thrombosis together with the ESC Working Group on Aorta and Peripheral Vascular Diseases

Member  
of the ESC  
Journal  
Family



**EuroThrombosis & EuroVessels 2022**

20-22 October | SANA LISBOA  
Lisbon, Portugal



# Cardiovascular Research

[academic.oup.com/cardiovasres](http://academic.oup.com/cardiovasres)

## Editor-in-Chief

Tomasz J. Guzik

## Deputy Editors

Charalambos Antoniades, UK  
Andrew Baker, UK  
Karlheinz Peter, Australia  
Eva van Rooij, Netherlands

## Reviews Deputy Editor

Ali J. Marian, USA

## Executive Deputy Editors

Christopher Loughrey  
Pasquale Maffia  
Stuart Nicklin

## Associate Editors

Elena Aikawa, USA  
Johann Bauersachs, Germany  
Erik Biessen, Netherlands  
Lothar Blatter, USA  
Giuseppina Caligiuri, France  
Daniela Carnevale, Italy  
Elisabetta Cerbai, Italy  
Sean Davidson, UK  
Christian Delles, UK  
Grant Drummond, Australia  
Annarita Di Lorenzo, USA  
Jie Du, China  
Dirk Duncker, Netherlands  
Jeanette Erdmann, Germany  
Paul Evans, UK  
Loren Field, USA  
Ingrid Fleming, Germany  
Mauro Giacca, Italy  
Sian Harding, UK

## Editorial Office

Senior Managing Editor  
Sarah K. Brown  
Glasgow, UK  
[Cardiovascular.Research@glasgow.ac.uk](mailto:Cardiovascular.Research@glasgow.ac.uk)

Assistant Editor  
Sean McLeod

Editorial Administrator  
Adam M. Sheikh

Cardiovascular Research Editorial Office  
Glasgow Cardiovascular Research Centre  
126 University Place  
Glasgow, G12 8TA  
United Kingdom

Email:  
[Cardiovascular.Research@glasgow.ac.uk](mailto:Cardiovascular.Research@glasgow.ac.uk);  
Tel: +44(0)141 330 2020/2485

## Senior Advising Editors

Barbara Casadei, UK  
Anna Dominiczak, UK  
Goran Hansson, Sweden  
Peter Libby, USA  
Joseph C. Wu, USA  
Salim Yusuf, Canada

## Past Editors-in-Chief

Karin R. Sipido, Belgium  
Hans Michael Piper, Germany\*  
David Garcia-Dorado, Spain\*  
Michiel J. Janse, Netherlands  
David J. Hearse, UK  
Peter Sleight, UK  
\*co-Editors-in-Chief

## ESC Journal Family Ethics Committee

Mat Daemen  
Kim M. Fox  
Christian Hamm

Ursula Ravens  
Maarten L. Simoons

## Guest Editor

Thomas F. Lüscher

## Consulting Editors

Lina Badimon, Spain  
Keith Channon, UK  
Francesco Cosentino, Sweden  
David Eisner, UK  
Steven Houser, USA  
Litsa Kranias, USA  
Giuseppe Lembo, Italy  
Ziad Mallat, UK  
Federica Marelli-Berg, UK

Henning Morawietz, Germany  
Elizabeth Murphy, USA  
Ryozo Nagai, Japan  
Matthias Nahrendorf, USA  
Jeremy D. Pearson, UK  
Silvia Priori, Italy  
Ajay Shah, UK  
Godfrey Smith, UK  
Alain Tedgui, France  
Christian Weber, Germany

## Joint Editors with European Heart Journal

Giovanni G. Camici  
Claudia Monaco  
Thomas Thum

## Onlife Editorial Team

Charalambos Antoniades  
Adam M. Sheikh  
Sarah K. Brown

## Editorial Board

Giuseppe Ambrosio, Italy  
Alexios Antonopoulos, Greece  
Ioanna Andreadou, Greece  
Reza Ardehali, USA  
Metin Avkiran, UK  
Jean-Luc Balligand, Belgium  
Colin Berry, UK  
George E. Billman, USA  
Christoph J. Binder, Austria  
Alex Bobik, Australia  
Jes-Niels Boeckel, Germany  
Reinier Boon, Germany  
George W. Booz, USA  
Chantal Boulanger, France  
Angela Bradshaw, UK  
Ralf Brandes, Germany  
Ana Briones, Spain  
Murray Clarke, UK  
Gianluigi Condorelli, Italy  
Daniel Conklin, USA  
Salvatore Cuzzocrea, Italy  
Mat J.A.P. Daemen, Netherlands  
Andreas Daiber, Germany  
Jan Danser, Netherlands  
Leon de Windt, Netherlands  
Mirela Delibegovic, UK  
Christopher Denning, UK  
Fabio Di Lisa, Italy  
Javier Diez, Spain  
Stefanie Dimmeler, Germany  
Dobromir Dobrev, Germany  
Agnieszka Dobrzyn, Poland  
Arnold von Eckardstein, Switzerland  
Øyvind Ellingsen, Norway  
Costanza Emanuelli, UK  
Thomas Eschenhagen, Germany  
Larissa Fabritz, UK  
Peter Ferdinandy, Hungary

Gemma Figtree, Australia  
Stefan Frantz, Germany  
Keiichi Fukuda, Japan  
David Fulton, USA  
Zbigniew Gaciong, Poland  
Elena Galkina, USA  
Pingjin Gao, China  
Meinrad Gawaz, Germany  
Christopher George, UK  
Sarah J. George, UK  
Jonathan Golledge, USA  
Ana M. Gomez, France  
Kathy Griendling, USA  
Asa Gustafsson, USA  
Stephane Hatem, France  
Anthony M. Heagerty, UK  
Deborah J. Henderson, UK  
Gerd Heusch, Germany  
Marcel van der Heyden, Netherlands  
Denise Hilfiker-Kleiner, Germany  
Joseph Hill, USA  
Yu Huang, China  
Yoshihiro Ishikawa, Japan  
Hiroshi Itoh, Japan  
Frederic Jaissier, France  
Jason Johnson, UK  
Thomas Kahan, Sweden  
Elissavet Kardami, Canada  
Christopher Kevil, USA  
Richard Kitsis, USA  
Andre G. Kleber, USA  
Mark Kohr, USA  
Yoshihiro Kokubo, Japan  
Wei Kong, China  
Jason Kovacic, Australia  
Patrick Lacolley, France  
Pablo Lamata, UK  
Ulf Landmesser, Germany

Roberto Latini, Italy  
Ulrich Laufs, Germany  
James Leiper, UK  
Gregory Lip, UK  
George Liu, China  
William E. Louch, Norway  
Kathy Lui, China  
Esther Lutgens, Netherlands  
Angela Maas, Netherlands  
Mandy MacLean, UK  
Kenneth Macleod, UK  
Rosalinda Madonna, Italy  
Maciej Malecki, Poland  
Francine Marques, Australia  
Alicia Mattiazzi, Argentina  
Pál Maurovich-Horvat, Budapest  
Philippe Menasché, France  
Daphne Merkus, Netherlands  
Joseph Miano, USA  
Jean-Baptiste Michel, France  
Evangelos Michelakis, Canada  
Augusto Montezano, UK  
Thomas Muenzel, Germany  
Rachel Myles, UK  
Andrew C. Newby, UK  
Antonio Nicoletti, France  
Tobias Ophthof, Netherlands  
Patrick J. Pagano, USA  
Zoltan Papp, Hungary  
Axel Pries, Germany  
Peter Psaltis, Australia  
Marlene Rabinovitch, USA  
Ursula Ravens, Germany  
Carol Ann Remme, Netherlands  
Llewelyn Roderick, UK  
Andrew Sage, UK  
Maurilio Sampaolesi, Belgium  
Gaetano Santulli, USA

Gabriele Schiattarella, USA  
Richard Schulz, Canada  
Sebastiano Sciarretta, Italy  
Mateusz Siedlinski, Poland  
Nicola Smart, UK  
Christopher Sobey, Australia  
Oliver Soehnlein, Germany  
Derek Steele, UK  
Charles Steenbergen, USA  
Konstantinos Stellos, UK  
Duncan Stewart, Canada  
Roland Stocker, Australia  
Mark Sussman, USA  
Cesare Terracciano, UK  
Maciej Tomaszewski, UK  
Dimitris Tousoulis, Greece  
Marcel Van der Hayden, Netherlands  
Jolanda van der Velden, Netherlands  
Jamie Vandenberg, Australia  
Richard S. Vander Heide, USA  
Andras Varro, Hungary  
Renee Ventura-Clapier, France  
Gemma Vilahur, Spain  
Johannes Waltenberger, Germany  
Xin Wang, UK  
Jeremy P.T. Ward, UK  
Neal Weintraub, USA  
Paul Welsh, UK  
Philip Wenzel, Germany  
Cornelia Weyand, USA  
Lorraine Work, UK  
Rui-ping Xiao, China  
Ying Yu, China  
Manuela Zaccolo, UK  
Alma Zernecke, Germany  
Andreas Zirlirk, Germany

# Aims and Scope

*Cardiovascular Research* is the international journal of the European Society of Cardiology for basic and translational research, across different disciplines and areas. The Journal aims to enhance insight in cardiovascular disease mechanisms and the perspective for innovation. The Journal welcomes submission of papers both at the molecular, sub-cellular, cellular, organ, and organism level, and of clinical proof-of-concept and translational studies. Manuscripts are expected to provide a significant contribution to the field with relevance for cardiovascular biology and diseases. Manuscripts may be submitted as Original Articles, Fast-track Communications, Research Letters or Reviews. Moreover, the Journal publishes Letters to the Editor and Editorials (the latter are usually invited), as well as comprehensive series of review as 'Spotlight Issues'.

*Cardiovascular Research* is Abstracted/Indexed in: *Biological Abstracts*; *Chemical Abstracts*; *Current Contents Life Sciences*; *Current Contents Clinical Medicine*; *Index Medicus: Journal Citation Reports*<sup>®</sup>, published by Thomson Scientific; *EMBASE/Excerpta Medica*; *NRN*; *Biotechnology Abstracts*; *Nutrition Abstracts*; *Index to Scientific Reviews*; *SIIC Data Bases*.

A subscription to *Cardiovascular Research* comprises 14 issues (includes *Cardiovascular Research Supplements*). All prices include postage, and for subscribers outside the UK delivery is by Standard Air. Advance Access contains papers that have reached corrected proof stage, but have not yet been included within an issue. Advance Access is updated daily.

**Annual subscription rate** (Volume 118, 14 issues, 2022)  
Subscription and single issue pricing information is available at <https://academic.oup.com/cardiovascres/subscribe>

There may be other subscription rates available, for a complete listing please visit <https://academic.oup.com/cardiovascres/subscribe>.

Full prepayment, in the correct currency, is required for all orders. Orders are regarded as firm and payments are not refundable. Subscriptions are accepted and entered on a complete volume basis. Claims cannot be considered more than FOUR months after publication or date of order, whichever is later. All subscriptions in Canada are subject to GST. Subscriptions in the EU may be subject to European VAT. If registered, please supply details to avoid unnecessary charges. For subscriptions that include online versions, a proportion of the subscription price may be subject to UK VAT. Personal rate subscriptions are only available if payment is made by personal cheque or credit card and delivery is to a private address.

The current year and two previous years' issues are available from Oxford University Press.

Previous volumes can be obtained from the Periodicals Service Company at <http://www.periodicals.com/oxford.html> or Periodicals Service Company, 11 Main Street, Germantown, NY 12526, USA. E-mail: [psc@peri-odicals.com](mailto:psc@peri-odicals.com). Tel: (518) 537-4700. Fax: (518) 537-5899.

**For further information, please contact:** Journals Customer Service Department, Oxford University Press, Great Clarendon Street, Oxford OX2 6DP, UK. E-mail: [jnls.cust.serv@oup.com](mailto:jnls.cust.serv@oup.com). Tel (and answerphone outside normal working hours): + 44 (0)1865 353907. Fax: + 44 (0)1865 353485. **In the US, please contact:** Journals Customer Service Department, Oxford University Press, 4000 CentreGreen Way, Suite 310, Cary, NC 27513, USA. E-mail: [jnorders@oup.com](mailto:jnorders@oup.com). Tel (and answerphone outside normal working hours): 800 852 7323 (toll-free in USA/Canada). Fax: 919 677 1714. **In Japan, please contact:** Journals Customer Services, Oxford Journals, Oxford University Press, 4-5-10-8F, Shiba, Minato-ku, Tokyo, 108-8386, Japan. E-mail: [cust.serv.jp@oup.com](mailto:cust.serv.jp@oup.com). Tel: + 81 3 5444 5858. Fax: + 81 3 3454 2929.

**Methods of payment.** Payment may be made: by cheque (to Oxford University Press, Cashiers Office, Great Clarendon Street, Oxford, OX2 6DP, UK); by bank transfer [to Barclays Bank Plc, Oxford Office, Oxford (bank sort code 20-65-18) (UK); overseas only Swift code BARC GB22 (GB£ Sterling Account no. 70299332, IBAN GB89BARC20651870299332; US\$ Dollars Account no. 66014600, IBAN GB27BARC20651866014600; EU€ EURO Account no. 78923655, IBAN GB16BARC20651878923655)]; or by credit card (Mastercard, Visa, Switch or American Express).

*Cardiovascular Research* (ISSN 0008-6363) is published 14 times a year, once a month but twice in March and July by Oxford University Press, Oxford, UK and distributed in the USA by Central Mailing Services c/o UKP Worldwide, 1637 Stelton Road B2, Piscataway, NJ 08854. Annual subscription price is £1467/US\$2934/€2201. Airfreight and mailing in the USA by agent named Central Mailing Services c/o UKP Worldwide, 1637 Stelton Road B1-2, Piscataway, NJ 08854. Periodicals Postage Paid at Piscataway, NJ and additional mailing offices.

US POSTMASTER: send address changes to *Cardiovascular Research*, Oxford University Press, Central Mailing Services c/o UKP Worldwide, 1637 Stelton Road B1-2, Piscataway, NJ 08854.

## Environmental and ethical policies

Oxford Journals, a division of Oxford University Press, is committed to working with the global community to bring the highest quality research to the widest possible audience. Oxford Journals will protect the environment by implementing environmentally friendly policies and practices wherever possible. Please see <https://academic.oup.com/journals/>

pages/autrs/ethics for further information on environmental and ethical policies.

## Supplements, reprints and corporate sales

For requests from industry and companies regarding supplements, bulk article reprints, sponsored subscriptions, translation opportunities for previously published material, and corporate online opportunities, please e-mail [special.sales@oup.com](mailto:special.sales@oup.com), fax + 44 (0)1865 353774 or visit <http://www.oupmediainfo.com/#/>.

## Digital object identifier (DOI)

For information about DOIs and to resolve them, please visit <http://www.doi.org/>

## Permissions

For information on how to request permissions to reproduce articles/information from this journal, please visit [https://academic.oup.com/journals/pages/access\\_purchase/rights\\_and\\_permissions](https://academic.oup.com/journals/pages/access_purchase/rights_and_permissions).

## Advertising

Advertising, inserts and artwork enquiries should be addressed to: Advertising and Special Sales, Oxford Journals, Oxford University Press, Great Clarendon Street, Oxford OX2 6DP, UK. Tel: + 44 (0)1865 354767; Fax: + 44 (0)1865 353774; E-mail: [jnlsadvertising@oup.com](mailto:jnlsadvertising@oup.com).

## Instructions for authors

Full instructions for manuscript preparation and submission can be found through the *Cardiovascular Research* home page at: <https://academic.oup.com/cardiovascres>.

## Drug disclaimer

The mention of trade names, commercial products or organizations, and the inclusion of advertisements in the journal does not imply endorsement by *Cardiovascular Research*, the editors, the editorial board, Oxford University Press or the organization to which the authors are affiliated. The editors and publishers have taken all reasonable precautions to verify drug names and doses, the results of experimental work and clinical findings published in the journal. The ultimate responsibility for the use and dosage of drugs mentioned in the Journal and in interpretation of published material lies with the medical practitioner, and the editors and publisher cannot accept liability for damages arising from any error or omissions in the journal. Please inform the editors of any errors.

## Material disclaimer

The opinions expressed in *Cardiovascular Research* are those of the authors and contributors, and do not necessarily reflect those of the European Society of Cardiology, the editors, the editorial board, Oxford University Press or the organization to which the authors are affiliated.

© The European Society of Cardiology 2022

All rights reserved; no part of this publication may be reproduced, stored in a retrieval system, or transmitted in any form or by any means, electronic, mechanical, photocopying, recording, or otherwise, without prior written permission of the Publishers, or a licence permitting restricted copying issued in the UK by the Copyright Licensing Agency Ltd, 90 Tottenham Court Road, London W1P 9HE, or in the USA by the Copyright Clearance Center, 222 Rosewood Drive, Danvers, MA 01923.

## Society

All members of national cardiac societies in Europe, ESC associations, Working Groups and councils, are automatically members of the European Society of Cardiology and are entitled to receive the journal at the special reduced rate.

For more details please visit: <https://www.escardio.org/The-ESC/Membership>.

Typeset by Nova Techset Limited, Chennai, India. Printed by Bell and Bain, Glasgow, UK on acid-free paper.

# **Cardiovascular Research**

## **EuroThrombosis & EuroVessels 2022 Abstracts**

This supplement is provided by the ESC Working Group on Thrombosis and the  
ESC Working Group on Aorta & Peripheral Vascular Diseases

### Oral Presentation No. 03

## Growth differentiation factor-15 and bleeding complication risk in patients with coronary artery disease, receiving combined antithrombotic therapy

E. Krivosheeva<sup>1</sup>†, A. Komarov<sup>1</sup>, A. Dobrovolsky<sup>1</sup>, E. Titaeva<sup>1</sup>, T. Balakhonova<sup>1</sup>, and E. Panchenko<sup>1</sup>

<sup>1</sup>National Medical Research Center of Cardiology Named After Academician E.I.Chazov

† The presenting author.

**Introduction:** Recent studies are aimed to find laboratory predictors of bleeding complications in patients receiving various regimens of antithrombotic therapy. One of these biomarkers is GDF-15.

**Purpose:** To study the significance of GDF-15 in relation to the development of bleeding outcomes in CAD patients with multifocal atherosclerosis, receiving combined antithrombotic therapy.

**Methods:** The data was obtained from the prospective registry REGATA-1 (NCT04347200). 122 patients (90 males), median age 69 [IQR 64; 76] yrs) with CAD and peripheral atherosclerosis of at least one vascular territory ( $\geq 50\%$ ), were enrolled. Half of the patients (47.5%) with sinus rhythm received acetylsalicylic acid in combination with rivaroxaban 2.5 mg bid. Other patients (52.5%) with concomitant atrial fibrillation received direct oral anticoagulants in combination with antiplatelet therapy after elective PCI. Median follow-up was 10 months [IQR 7.0;12.0]. The safety end point was BARC 2–5 bleedings. Plasma samples for GDF-15 identification were taken at the inclusion and analyzed using ELISA.

**Results:** Frequency of BARC 2–5 bleedings was 14%. Median GDF-15 level was 1248.5 pg/ml [947.8; 1791.0]. According to the quartile analysis, GDF-15 values in the top three quartiles of the distribution (cut-off value  $> 948$  pg/ml) were associated with higher frequency of bleeding events: 3.1% versus 17.8%,  $P = 0.0411$ . Bleeding-free survival in groups, formed depending on the level of GDF-15 ( $948 >$  and  $\leq 948$  pg/ml), was 96.7% vs. 82.2%, respectively, Log-Rank  $P = 0.0408$ .

**Conclusions:** Increase in GDF-15 level ( $> 948$  pg/ml) is associated with the development of BARC 2-5 bleedings in CAD patients with multifocal atherosclerosis, receiving combined antithrombotic therapy.

## Oral Presentation No. 006

### Postoperative Myocardial Injury due to Platelet Reactivity in Patients undergoing Vascular Surgery

K.L. Zheng<sup>1†</sup>

<sup>1</sup>St. Antonius Hospital, Nieuwegein, Netherlands

† The presenting author.

**Background:** Postoperative myocardial injury (PMI) after major vascular surgery, detected by elevated cardiac troponin (cTn), has been associated with morbidity and mortality. It is unclear whether the pathophysiology of PMI is determined by increased platelet activity.

**Objective:** To examine the relationship between platelet activation (P-selectin expression) and PMI(cTn release as continuum) in patients undergoing elective open abdominal aortic surgery in the early post-operative period.

**Methods:** This prospective, single-centre, observational, cohort study included 33 patients undergoing elective open abdominal aortic surgery between March 2018 and April 2021. Patients were routinely treated with aspirin. Unstimulated platelet activation was measured by platelet bound P-selectin expression (range 0–100%). Explorative coagulation measurements were: stimulated platelet aggregation measured with the VerifyNow® assay (aspirin cartridge), with the Multiplate® analyzer (ASPI, ADP and TRAP) and stimulated coagulation status evaluated by the TEG® Haemostasis Analyzer System (global haemostasis cartridge). The primary outcome was cTn release assessed by the fifth generation high-sensitive cTn assay. Multivariable generalized linear mixed models were used to evaluate the association between platelet function and cTn concentrations over time.

**Results:** Ten patients (29.4%) developed PMI. Increased P-selectin expression directly after surgery was associated with the cTn concentrations over 48 h ( $\beta = 1.39(1.1-1.75)$ ,  $P = 0.0064$ ). No association was found between P-selectin measured later (at 24 h or 48 h) after surgery and cTn concentrations. Furthermore, there was no association between the explorative coagulation parameters and cTn release.

**Conclusion:** Increased P-selectin expression measured directly after surgery is associated with elevated cTn concentrations in the early postoperative period in patients undergoing elective open abdominal aortic surgery.

## Oral Presentation No. 10

### Pharmacological therapy in patients with myocardial infarction with nonobstructive coronary arteries (MINOCA): long-term prognosis

Vanessa Lopes<sup>1</sup>†, Nádia Moreira<sup>1</sup>, Rafaela Fernandes<sup>1</sup>, Gil Cunha<sup>1</sup>, Gonçalo Costa<sup>1</sup>, Eric Monteiro<sup>1</sup>, Diogo Fernandes<sup>1</sup>, Joana Guimarães<sup>1</sup>, James Milner<sup>1</sup>, Vera Marinho<sup>1</sup>, Sílvia Monteiro<sup>1</sup>, Pedro Monteiro<sup>1</sup>, Francisco Gonçalves<sup>1</sup>, and Lino Gonçalves<sup>1</sup>

<sup>1</sup>Centro Hospitalar E Universitário De Coimbra

† The presenting author.

**Background:** The optimal management of myocardial infarction with nonobstructive coronary arteries (MINOCA) is still uncertain. This study sought to determine the association between pharmacological therapies after hospital discharge and the long-term prognosis of MINOCA patients.

**Material and methods:** We analyzed patients consecutively admitted to the coronary care unit with myocardial infarction (MI). Multivariate analysis was performed to determine which drugs were implicated in the prognosis of MINOCA patients. The primary endpoint was all-cause mortality at 5 years.

**Results and conclusions:** From a total of 3721 MI patients, MINOCA was identified in 11.6% ( $n=430$ ), of whom 56 (13.0%) experienced the primary endpoint. Median age was 66 years (IQR 19), and 51.6% ( $n=222$ ) of patients were male.

At discharge, 81.2% of MINOCA patients were prescribed aspirin, 87.4% a statin, 78.6% beta-blockers, and 66.7% angiotensin-converting enzyme inhibitors (ACEI). MINOCA patients were less likely to be prescribed these medications compared to patients with obstructive coronary artery disease (all  $P < 0.001$ ). 1.4% ( $n=6$ ) of MINOCA patients died in the hospital, and the 5-year mortality rate was 13.0% ( $n=56$ ). In multivariate Cox regression, treatment with ACEI at discharge was found to be independently associated with a 5-year mortality benefit (HR = 0.29, 95% CI 0.12–0.67, adjusted  $P=0.004$ ) in MINOCA patients.

In conclusion, compared with patients with obstructive CAD, patients with MINOCA are less likely to be treated with secondary prevention drugs and are at lower risk of all-cause mortality during long-term follow-up. Treatment with ACEI seems to provide an additional mortality benefit in MINOCA patients.

**Oral Presentation No. 019****Bi-directional cross talk between coagulation, fibrinolysis and inflammatory pathways in patients with ST-segment elevation myocardial infarction**

Rahim Kanji<sup>1</sup>†, Ying X Gue<sup>2</sup>, Mohammed F Farag<sup>3</sup>, Nicola J Mutch<sup>4</sup>, and Diana A Gorog<sup>1</sup>

<sup>1</sup>National Heart and Lung Institute, Imperial College London

<sup>2</sup>Liverpool Centre for Cardiovascular Science, University of Liverpool

<sup>3</sup>School of Life and Medical Sciences, University of Hertfordshire

<sup>4</sup>Aberdeen Cardiovascular & Diabetes Care, University of Aberdeen

† The presenting author.

**Background:** Impaired endogenous fibrinolysis is a risk factor for recurrent cardiovascular events in patients with acute coronary syndrome (ACS). Ongoing inflammation is also an adverse prognostic risk factor. While inflammatory markers are elevated in patients presenting with ST-segment elevation myocardial infarction (STEMI), whether there is a direct relationship between markers of inflammation at presentation, and the effectiveness of endogenous fibrinolysis in this setting, is unclear.

Our study aimed to assess the relationship between markers of inflammation, coagulation and fibrinolysis, in patients with STEMI.

**Material and methods:** We conducted a prospective, observational study in consecutive patients presenting with STEMI. Blood was drawn on admission after dual antiplatelet therapy loading, but before administration of anticoagulants. The sample was immediately tested to assess endogenous fibrinolysis using the point-of-care Global Thrombosis Test. In addition, blood samples were tested for leucocyte and neutrophil count, neutrophil-to-leucocyte ratio (NLR), platelet-to-leucocyte ratio (PLR), fibrinogen, standard coagulation markers and high sensitivity C-reactive protein (hs-CRP).

**Results and conclusions:** The cohort consisted of 129 patients (aged  $66 \pm 13$  years, 78% male). Whole blood endogenous fibrinolysis time correlated with fibrinogen ( $r = 0.300$ ,  $P = 0.001$ ) and hs-CRP ( $r = 0.236$ ,  $P = 0.011$ ). Hs-CRP correlated with fibrinogen ( $r = 0.631$ ,  $P < 0.001$ ). There was no relationship between whole blood lysis time and leucocyte count, NLR, PLR, international normalised ratio or activated partial thromboplastin time.

The effectiveness of endogenous fibrinolysis in whole blood is related to fibrinogen and hs-CRP levels. Our findings strengthen the evidence for bi-directional cross talk between coagulation, fibrinolysis and inflammatory pathways, providing mechanistic insights that could help guide pharmacological strategies to treat hypofibrinolysis.



**Oral Presentation No. 32****The interplay between VWF, ADAMTS13 and TSP1, and their relation to clinical endpoints**

Ellen Mathea Kirsch Warlo<sup>1</sup>†, Are A. Kalstad<sup>1</sup>, Peder L. Myhre<sup>2</sup>, Svein Solheim<sup>1</sup>, Harald Arnesen<sup>1</sup>, Arnljot Tveit<sup>3</sup>, Ingebjørg Seljeflot<sup>1</sup>, and Vibeke Bratseth<sup>1</sup>

<sup>1</sup>Oslo University Hospital

<sup>2</sup>Akershus University Hospital

<sup>3</sup>Vestre Viken Hospital Trust, Bærum Hospital

† The presenting author.

**Introduction:** ADAMTS13 cleaves von Willebrand Factor (VWF) into less active fragments. TSP1 binds to VWFs cleavage-site, protecting it from degradation. Low ADAMTS13 and high VWF have been associated with cardiovascular disease (CVD) and atrial fibrillation (AF).

We aimed to investigate the interplay between VWF, ADAMTS13 and TSP1, and assess any relation to endpoints.

**Materials and methods:** 1027 elderly with a recent myocardial infarction (MI) were followed for 2 years. ADAMTS13 antigen (ag) and activity (act), VWF ag and TSP1 were analyzed. The primary endpoint (MACE;  $n=210$ ) included MI, stroke, heart failure hospitalization, coronary revascularization and death. The secondary endpoint was new-onset AF ( $n=43$ ).

**Results:** ADAMTS13 ag and act were weakly correlated to VWF ( $r=0.10$ ,  $P=0.002$ , both). TSP1 did not correlate to ADAMTS13 or VWF. Patients experiencing a MACE had higher VWF and lower ADAMTS13(ag) at baseline ( $P<0.012$ , both), however not significant after adjusting for covariates. The association with MACE was mainly driven by death ( $n=40$ ), with an adjusted OR 2.4 ( $P=0.008$ ) for VWF Q4 vs. Q1-3 and OR 0.4 ( $P=0.012$ ) for ADAMTS13(ag) Q1 vs. Q2-4. VWF was lower (1.25 vs. 1.39 IU/mL,  $P=0.008$ ) and VWF/ADAMTS13(ag)-ratio was lower (1.81 vs.  $2.05 \times 10^{-3}$ ,  $P=0.009$ ) in patients with new-onset AF, and these associations persisted in adjusted models.

**Conclusion:** In elderly patients with a recent MI, levels of VWF, ADAMTS13 and TSP1 did not correlate. ADAMTS13 and VWF associated weakly with MACE, mainly driven by death. Low VWF and VWF/ADAMTS13-ratio were associated with new-onset AF in our population and needs further research.

## Oral Presentation No. 034

### A Case Series of patients with Pulmonary Embolism during post COVID-19 period

Elena Leonidou<sup>1</sup>†, Maria Ioannou<sup>1</sup>, Ioanna Chaziri<sup>2</sup>, and Angeliki Mouzarou<sup>3</sup>

<sup>1</sup>Department of Cardiology, General Hospital Limassol, State Health Organization Services, Limassol, Cyprus

<sup>2</sup>Department of Pneumology, NothernÄlvborg County Hospital, Trollhättan, Sweden

<sup>3</sup>Critical Care Unit COVID-19, General Hospital Limassol, State Health Organization Services, Limassol, Cyprus

† The presenting author.

**Background:** Over the past two years, Coronavirus Disease (COVID-19) and associated complications, including hypercoagulopathy, is a routine in our hospitals. We already know, that hospitalized critical ill patients with COVID-19 pneumonia, have an increased risk for Pulmonary Embolism (PE). However, only limited data refer to the potential risk in post-COVID-19 patients, and fewer, in patients who had mild disease. We define as mild COVID -19, cases that either didn't need hospitalization or they were hospitalized without respiratory complications. The incidence of PE in post-COVID-19 patients who had only mild symptoms remains unknown.

**Material and methods:** We are presenting a case series of five patients with mild COVID-19 infection, from our hospital, who presented with PE during the post COVID-19 infectious period. All of the patients presented mild symptoms during the infectious period. One among them needed a short duration of hospitalization for the COVID-19 infection and another one needed hospitalization due to an established stroke.

**Results and conclusions:** Our cases advocate that even mild COVID-19 could be considered a potential risk factor for PE, after the infectious period. According to our case series, the mean susceptible period in which post-COVID-19 patients may present PE is 21,6 days. However, the time frame in which these patients are more vulnerable to developing PE is not yet known. Nevertheless, the fact that PE occurs even in past mild disease, reinforces the idea that COVID-19 is an independent and cumulative risk factor predisposing to PE.

### Oral Presentation No. 41

## High plasma von Willebrand factor concentration is associated with the development of bleeding complications in patients with polyvascular disease receiving multicomponent antithrombotic therapy

E. Krivosheeva<sup>1</sup>†, A. Komarov<sup>1</sup>, A. Dobrovolsky<sup>1</sup>, V. Korobkova<sup>1</sup>, E. Titaeva<sup>1</sup>, M. Tripoten<sup>1</sup>, T. Balakhonova<sup>1</sup>, and E. Panchenko<sup>1</sup>

<sup>1</sup>National Medical Research Center Of Cardiology Named After Academician E.I.Chazov

† The presenting author.

**Background:** von Willebrand factor (VWF) is well known biochemical marker of endothelial dysfunction that increased may be associated with the development of thrombotic complications in patients with polyvascular disease (PD). We aimed to assess the relation of VWF to the development of bleeding outcomes in patients with PD receiving multicomponent antithrombotic therapy (MAT).

**Material and methods:** The data were obtained during the prospective register REGATA-1, NCT04347200. 95 patients (70 males), median age 67 [IQR 61; 72] with PD (coronary artery disease and peripheral atherosclerosis of at least one vascular territory  $\geq 50\%$ ) were enrolled. 61% of patients received acetylsalicylic acid in combination with rivaroxaban 2.5 mg bid, other (39%) with clopidogrel. Median follow-up was 10 months [IQR 8.0; 12.0]. The safety end point was major and clinically relevant bleedings (type 2–5) according to the BARC classification. Plasma samples for VWF were taken at the inclusion and analyzed using ELISA.

**Results:** Frequency of BARC 2–5 bleedings was 20%. The most frequent (79%) was gastrointestinal bleedings. Median VWF plasma concentration was 154% [116; 196]. According to the quartile analysis, VWF values in the top three quartiles distribution (cut-off value  $> 122\%$ ) were associated with a higher frequency of bleeding events: 3.7% versus 36.7%, OR 8.8; CI 1, 11–69.9,  $P = 0.0392$ . Bleeding-free survival in groups formed depending on the VWF plasma concentration ( $> 122\%$  and  $\leq 122\%$ ) was 96.2% vs. 73.9%, respectively, Log-Rank  $P = 0.0488$ .

**Conclusions:** Increase of VWF plasma concentration ( $> 122\%$ ) is associated with the development of major and clinically relevant bleedings in patients with PD receiving MAT.

## Oral Presentation No. 46

### The effect of covid-19 vaccine on the endothelial function

Ahmed Makni<sup>1</sup>†, Aiman Ghrab<sup>1</sup>, Rania Gargouri<sup>1</sup>, Salma Charfeddine<sup>1</sup>, Amine Bahloul<sup>1</sup>, Tarek Ellouze<sup>1</sup>, Rania Hammami<sup>1</sup>, Faten Triki<sup>1</sup>, Mariem Jabeur<sup>1</sup>, Souad Mallek<sup>1</sup>, and Leila Abid<sup>1</sup>

<sup>1</sup>Hedi Chaker university hospital Sfax

† The presenting author.

**Background:** Covid-19 vaccine was associated with several complications such as thromboembolic complications. The exact mechanism is not well established. Since covid 19 virus caused severe endothelial dysfunction, we suspect that the vaccine with a similar immunological response may cause this dysfunction.

**Aim:** To study the effect of covid-19 vaccine on endothelial function.

**Methods:** We conducted a prospective study. The endothelial function was clinically assessed using a post-occlusive reactive hyperemia protocol with finger thermal monitoring device. Endothelial quality index (EQI) was assessed at inclusion before the first dose of coronavirus vaccine and 30 days later.

**Results:** 20 patients were included in our study. Their mean age was 41 years old [23–65]. The sex ratio was 3/2. They were all healthy individuals. The Majority, 75% of our patients, have impaired their endothelial function 30 days after the first dose of covid-19 vaccine.

**Conclusion:** The Covid-19 vaccine effect on endothelial function may be responsible for its complications.

**Key words:** Covid-19 vaccine, endothelial dysfunction

**Oral Presentation No. 48**  
**Sex-based differences in patients with peripheral arterial disease admitted for acute coronary syndrome - Insights from a multicentre national registry**

Margarida Cabral<sup>1</sup>†, Carolina Gonçalves<sup>1</sup>, Sara Fernandes<sup>1</sup>, Mariana Carvalho<sup>1</sup>, Catarina Ruivo<sup>1</sup>, Sidarth Pernencar<sup>1</sup>, Maria Fátima Loureiro<sup>2</sup>, and João Morais<sup>1</sup> on Behalf of The National Registry of Acute Coronary Syndromes Investigators

<sup>1</sup>Cardiologia - CHLP - Hospital Santo André Epe – Leiria

<sup>2</sup>National Centre for Data Collection in Cardiology, Portuguese Society of Cardiology, Coimbra, Portugal

† The presenting author.

Atherosclerosis represents a systemic disease that can involve multiple vascular beds, including coronary artery disease and peripheral artery disease (PAD). Acute coronary syndrome (ACS) with concomitant PAD represents a high-risk subgroup that deserves special attention. In particular, sex-based differences in PAD treatment and outcomes have been discussed.

This study aimed to clarify the main differences in clinical outcomes between women and men with PAD admitted for ACS. The authors performed a retrospective analysis of adult patients with PAD, included in the Portuguese Registry on Acute Coronary Syndromes (ProACS) between October 2010 and July 2022. A *P-value* < 0.05 is statistically significant.

Of the total of 32 251 hospitalized patients admitted for ACS, 1588 (4.9%) had known PAD, of which 320 were women and 1268 men. Table 1 shows the most important baseline characteristics and differences between groups. After propensity score matching, with 640 patients, female gender appeared to be an independent factor for acute heart failure (OR 0.68, 95% CI [0.48, 0.96], *P-value* = 0.03) and in-hospital mortality (OR 0.36, 95% CI [0.17, 0.73], *P-value* < 0.01). However, there are no differences between sex for 1-year mortality (*P-value* = 0.70).

In conclusion, in this group of patients, PAD is less prevalent among women, and probably underdiagnosed. In addition, there is a significant difference in medication with fewer women taking acetylsalicylic acid, probably undertreated. Finally, women have more in-hospital complications, including mortality. Hence, additional efforts are needed in order to better understand sex-based differences in PAD and increase awareness of this condition in women.

### Oral Presentation No. 53

## Dose-related preprocedural patency of the infarct-related artery after zalunfiban (RUC-4) administration upon arrival at the catheterization laboratory in ST-elevation myocardial infarction: insights from the phase IIa study

Sem A.O.F. Rikken<sup>1†</sup>, WL Bor<sup>1</sup>, KL Zheng<sup>1</sup>, CM Gibson<sup>2</sup>, CB Granger<sup>3</sup>, BS Coller<sup>4</sup>, O Bentur<sup>4</sup>, R Lobatto<sup>5</sup>, S Postma<sup>6</sup>, AWJ Van 't Hof<sup>7</sup>, and JM Ten Berg<sup>1</sup>

<sup>1</sup>St. Antonius Hospital, Nieuwegein, Netherlands

<sup>2</sup>Boston Clinical Research Institute, Boston, USA

<sup>3</sup>Department of Cardiology, Duke University School of Medicine, Durham, USA

<sup>4</sup>Rockefeller University, Allen and Frances Adler Laboratory of Blood and Vascular Biology - New York - USA

<sup>5</sup>RP & L Consultancy B.V. - Wassenaar - Netherlands (The)

<sup>6</sup>Diagram B.V. - Zwolle - Netherlands (The)

<sup>7</sup>Cardiovascular Research Institute Maastricht (CARIM) - Maastricht - Netherlands (The)

† The presenting author.

**Background:** The importance of time to reperfusion after ST-elevation myocardial infarction (STEMI) is well established. Pre-hospital use of glycoprotein IIb/IIIa (GPIIb/IIIa) inhibitors improves pre-percutaneous coronary intervention (PCI) perfusion rates, but they require intravenous administration and continuous infusions and so are difficult for ambulance services to administer. Zalunfiban (RUC-4) is a novel, subcutaneously administered, GPIIb/IIIa inhibitor specifically developed to facilitate pre-hospital administration, thereby maximizing the chance for early reperfusion. This sub-analysis investigated the incidence of complete reperfusion (TIMI grade 3 flow) before primary PCI in patients treated with zalunfiban on arrival at the catheterization laboratory as a function of the dose of zalunfiban.

**Material and methods:** This was a prospective, single-centre, open-label, phase IIa study designed to assess the pharmacodynamics, pharmacokinetics, and tolerability of zalunfiban in patients with STEMI undergoing primary PCI. Zalunfiban was administered immediately upon arrival at the catheterization lab, which was ~10–15 minutes before the initial angiogram used to assess TIMI grade flow.

**Results and conclusion:** A total of 27 patients received a weight-adjusted subcutaneous injection of zalunfiban in escalating doses (0.075 mg/kg [ $n=8$ ], 0.090 mg/kg [ $n=9$ ], or 0.110 mg/kg [ $n=10$ ]). Of these, 25 patients were evaluable for angiographic analysis. TIMI flow grade 3 pre-PCI was observed in 1/7, 2/9 and 5/9 patients and showed a dose-related effect ( $P_{\text{trend}}=0.04$ ). The ongoing international, phase III, double-blinded, randomized, placebo-controlled, CELEBRATE trial is designed to assess whether a single, ambulance-based pre-hospital injection of zalunfiban results in improved clinical outcome.

**Funding:** This study was supported by CeleCor Therapeutics.

## Oral Presentation No. 55

### Is White Blood Count a Good Marker to Coronary Disease Risk?

Débora Sá<sup>1</sup>†, Roberto Palma Dos Reis<sup>2</sup>, Margarida Temtem<sup>1</sup>, Marina Santos<sup>1</sup>, Ana Célia Sousa<sup>1</sup>, Sónia Freitas<sup>1</sup>, Eva Henriques<sup>1</sup>, Mariana Rodrigues<sup>1</sup>, Sofia Borges<sup>1</sup>, Ilídio Ornelas<sup>1</sup>, António Drumond<sup>1</sup>, and Maria Isabel Mendonça<sup>1</sup>

<sup>1</sup>Hospital Dr. Nélio Mendonça

<sup>2</sup>Faculdade de Ciências Médicas de Lisboa / NOVA Medical School

† The presenting author.

**Background:** High white blood cells (WBC) count is a well-recognized indicator of inflammation. Previous research has considered it a risk factor for coronary artery disease (CAD). Other new inflammatory risk markers are expensive to test, are not readily available, lack standardization and have not been confirmed as risk markers by multiple prospective studies. We aim to investigate whether elevated WBC count represents an independent risk factor for CAD in our Portuguese population.

**Material and methods:** A case-control study with 3,160 individuals (mean age  $53.1 \pm 7.8$ ; 77.6% male), namely 1,723 coronary patients and 1,437 controls, was performed. Together with WBC, the following CAD risk factors were analyzed: smoking, hypertension, diabetes, dyslipidemia and obesity through bivariate analysis. Multivariate logistic regression evaluated the independent risk factors for CAD.

**Results and conclusions:** Comparing cases with controls, 47.2% were smokers vs. 23.8% ( $P < 0.0001$ ); 71.0% were hypertensive individuals vs. 52.3% ( $P < 0.0001$ ); 89.0% had dyslipidemia vs. 70.4% ( $P < 0.0001$ ); 33.8% had diabetes vs. 13.2% ( $P < 0.0001$ ) and 34.2% were obese patients vs. 28.9% ( $P = 0.001$ ). After multivariate regression, smoking (OR = 3.14,  $P < 0.0001$ ), diabetes (OR = 2.89,  $P < 0.0001$ ), dyslipidemia (OR = 2.72,  $P < 0.0001$ ), hypertension (OR = 1.95,  $P < 0.0001$ ) and WBC (OR = 1.05,  $P = 0.035$ ) remained as independent risk factors for CAD. Elevated white blood counts are associated with CAD risk in our population. This marker is inexpensive, widely available and may further predict inflammation and coronary artery disease risk.

**Oral Presentation No. 56****Elevated White Blood Cells Count and C-Reactive Protein as markers for coronary heart disease prognosis**

Débara Sá<sup>1</sup>†, Maria Isabel Mendonça<sup>1</sup>, Marina Santos<sup>1</sup>, Margarida Temtem<sup>1</sup>, Ana Célia Sousa<sup>1</sup>, Mariana Rodrigues<sup>1</sup>, Eva Henriques<sup>1</sup>, Sónia Freitas<sup>1</sup>, Sofia Borges<sup>1</sup>, Ilídio Ornelas<sup>1</sup>, António Drumond<sup>1</sup>, and Roberto Palma Dos Reis<sup>2</sup>

<sup>1</sup>Hospital Dr. Nélio Mendonça

<sup>2</sup>Faculdade de Ciências Médicas de Lisboa / NOVA Medical School

† The presenting author.

**Background:** White blood count (WBC) and C-reactive protein (CRP) elevation are well-recognized inflammation indicators and considered risk factors for coronary heart disease (CHD). Most of the other newly introduced inflammatory risk markers are expensive to test, are not readily available, lack standardization, and have not been confirmed by multiple prospective studies. Whether these classic inflammatory markers may predict major adverse coronary events (MACE) in CHD patients is controversial. We aimed to evaluate whether high WBC and CRP are independent risk factors for MACE occurrence in CHD patients with an extended follow-up.

**Material and methods:** A cohort of 1,713 CHD patients (mean age  $54.0 \pm 7.5$  years, 78.6% male) was prospectively followed during an extended time of  $4.9 \pm 3.4$  years (range 1 to 17 years). Bivariate and multivariate Cox regression with WBC, CRP and traditional risk factors (age, gender, smoking, family history, dyslipidemia, diabetes and BMI) analyzed those significantly associated with MACE.

**Results and conclusions:** MACE group presented a higher percentage of non-smokers ( $P = 0.006$ ); hypertension ( $P = 0.003$ ); dyslipidemia ( $P = 0.025$ ) and diabetes ( $P < 0.0001$ ). WBC ( $P = 0.048$ ) and CRP ( $P < 0.0001$ ) were also significantly higher in patients with MACE relatively to non-MACE patients. After multivariate Cox analysis, WBC and CRP remained significant risk factors for MACE, with diabetes and hypertension presenting as strong statistical value. As a conclusion, the inflammatory CRP and WBC factors are accurate to predict MACE in secondary prevention. These biomarkers are easily accessed, providing helpful information in the prognosis of cardiovascular patients.



**Oral Presentation No. 64****Elevated soluble glycoprotein VI, a specific predictor of bleeding risk in patients with chronic coronary syndromes undergoing percutaneous coronary intervention**

Shqipdona Lahu\*<sup>1</sup>†, Kristin Adler\*<sup>2</sup>, Gjin Ndrepepa<sup>1</sup>, Katharina Mayer<sup>3</sup>, Ralph Hein-Rothweiler<sup>4</sup>, Isabell Bernlochner<sup>5</sup>, Karl-Ludwig Laugwitz<sup>5</sup>, Adnan Kastrati<sup>3</sup>, Meinrad Gawaz<sup>6</sup>, Steffen Massberg<sup>4</sup>, and Götz Münch<sup>2</sup>

<sup>1</sup>Department of Cardiology, German Heart Center Munich; Technical University of Munich, Munich, Germany

<sup>2</sup>advanceCOR GmbH, Martinsried, Germany

<sup>3</sup>Department of Cardiology, German Heart Center Munich; Technical University of Munich, Munich, Germany; German Center for Cardiovascular Research (DZHK), Partner Site Munich Heart Alliance, Munich, Germany

<sup>4</sup>German Center for Cardiovascular Research (DZHK), Partner Site Munich Heart Alliance, Munich, Germany; Department of Cardiology, Medizinische Klinik und Poliklinik I, Klinikum der Universität München, Ludwig-Maximilians-Universität, Munich, Germany

<sup>5</sup>German Center for Cardiovascular Research (DZHK), Partner Site Munich Heart Alliance, Munich, Germany; Klinik und Poliklinik für Innere Medizin I, Klinikum rechts der Isar, Technische Universität München, Munich, Germany

<sup>6</sup>Department of Cardiology and Angiology, University Clinic Tübingen, Tübingen, Germany

† The presenting author.

**Background:** Whether plasma levels of soluble glycoprotein VI (sGPVI) are able to predict ischemic or bleeding risk in patients with chronic coronary syndrome (CCS) undergoing percutaneous coronary intervention (PCI) is not known. The objective of this study was to answer this question.

**Material and methods:** The present study included 317 patients out of 334 patients of the ISAR-PLASTER trial (randomized trial of 2 doses of revacept vs. placebo), who underwent PCI for CCS and had baseline plasma sGPVI levels available. Patients were categorized into three groups according to tertiles of sGPVI: low ( $n = 106$ ;  $sGPVI \leq 9.5$  ng/ml), intermediate ( $n = 106$ ;  $sGPVI \leq 16.2$  ng/ml) and high tertile of sGPVI ( $n = 105$ ;  $sGPVI \geq 16.5$  ng/ml). The composite of death and myocardial injury (MI) at 48 hours after randomization served as a measure of ischemic risk, and Bleeding Academic Research Consortium (BARC) type 1 to 5 bleeding at 30 days as a measure of bleeding risk.

**Results and conclusions:** Baseline plasma levels of sGPVI (before PCI and revacept administration) correlated with bleeding (bleeding incidence among low, intermediate and high sGPVI tertile: 11.8%, 13.6%, and 25.8%, respectively;  $P = 0.005$ ), but not with ischemic events (incidence of death/MI among low, intermediate and high sGPVI tertile: 25.0%, 21.9%, and 26.9%, respectively;  $P = 0.70$ ). Revacept did not interact with these associations. Elevated plasma sGPVI levels are associated with an increased risk of bleeding but not ischemic complications after PCI in patients with CCS.

**Funding:** German Center for Cardiovascular Research, Deutsches Herzzentrum München, Federal Ministry of Education and Research, and advanceCOR.

**Oral Presentation No. 67**  
**Thrombotic Events in COVID-19 Patients Admitted at Chinese General Hospital and Medical Center**

Joel Santos<sup>1</sup>† and Jenny Beltran<sup>1</sup>

<sup>1</sup>Other

† The presenting author.

**Background:** Thrombosis is among the most prominent and concerning complications associated with COVID-19. These thrombotic events have been associated in progression of ARDS and morbidity and mortality.

**Methodology:** Retrospective cohort study of 203 patients  $\geq 18$  years old with confirmed COVID-19 admitted on tertiary referral hospital from January to December 2021. All thrombotic events were established by clinical signs and symptoms, ultrasonography and CT scan.

**Results and conclusions:** Sixty five (32%) patients out of 203 developed thrombotic complications. The most common thrombotic event was pulmonary embolism (36%), followed by myocardial infarction (28%), cerebrovascular infarct (27%), DVT (25%), acute limb ischemia (7%) and lastly, mesenteric ischemia (6%). There were significant differences in demographic and clinical profile among COVID-19 patients with and without thrombotic events. Thrombosis was more commonly seen in advanced age ( $\geq 75$  years, 49.2% vs. 23.9%; RR2.06, CI1.4–3.03), severe infection (severe, 24.6% vs. 19.6%; RR1.2, CI0.8–1.9 and critical and 47.7% vs. 10.1%; RR3.2, CI2.2–4.6, respectively), ICU admission (20% vs. 3.6%; RR2.6, CI1.8–3.7). Other complications were acute respiratory syndrome (83% vs. 43.5%; RR3.8, CI2.1–6.9), acute kidney injury (50.8% vs. 19.6%; RR2.46, CI1.68–3.6), major bleeding (9.2% vs. 0%; RR2.07, CI1.83–2.34), clinically relevant non-major bleeding (30.8% vs. 10.1%; RR2.21, CI1.52–3.22), hospitalization  $> 21$  days (29.2% vs. 13%; RR1.85, CI1.24–2.76), and all-cause mortality (60% vs. 3.6%; RR5.42, CI3.76–7.82). Patients who developed thrombosis had prolonged duration of immobilization, higher Padua prediction and CURB 65 scores, with wall motion abnormality in 2D-echocardiography, elevated D-dimer and pro-BNP, reduced oxygen saturation an often received invasive and non-invasive ventilation and hemoperfusion. Majority of patients was given thromboprophylaxis in both groups; hence a significant difference was not found. An institutional thromboprophylaxis protocol is needed in managing COVID-19 patients at risk for thrombotic events.

**Oral Presentation No. 068**  
**Plasma fibrinogen independently predicts hypofibrinolysis in severe COVID-19**

Diana Schrick<sup>1</sup>†, Margit Tokés-Füzesi<sup>2</sup>, Barbara Réger<sup>3</sup>, and Tihamér Molnár<sup>1</sup>

<sup>1</sup>University of Pécs, Medical School, Clinical Centre, Department of Anaesthesiology and Intensive Care

<sup>2</sup>Szigetvár Hospital, Central Laboratory

<sup>3</sup>University of Pécs, Medical School, Clinical Centre, Department of Laboratory Medicine

† The presenting author.

High rates of thrombosis are present in patients with SARS-CoV-2 infection. Deeper insight into the prothrombotic state is essential to provide the best thromboprophylaxis care. We aimed to explore associations among platelet indices, conventional hemostasis parameters, and viscoelastometry data.

21 patients with severe COVID-19 and 21 age-matched controls were enrolled. Each patient received 100 mg aspirin therapy at the time of blood sampling. To monitor the aspirin therapy, a platelet function test from hirudin anticoagulated whole blood was performed using the ASPI test by Multiplate analyser. High on-aspirin platelet reactivity ( $n = 8$ ) was defined with an AUC > 40 cut-off value by ASPI tests. Furthermore, vitro viscoelastometric tests were carried out using a ClotPro analyser in COVID-associated thromboembolic events nor the survival rate showed significant associations with high on-aspirin platelet reactivity status.

Patients presented with higher levels of inflammatory markers, along with evidence of hypercoagulability by ClotPro. H-IPF (%) was significantly higher among non-survivors ( $n = 18$ ) compared to survivors ( $P = 0.011$ ), and a negative correlation ( $P = 0.002$ ) was found between H-IPF and plasminogen level in the total population. The platelet count was significantly higher among patients with high on-aspirin platelet reactivity ( $P = 0.03$ ). ECA-A10 ( $P = 0.008$ ), and ECA-MCF ( $P = 0.016$ ) were significantly higher, while the tPA-CFT ( $P < 0.001$ ) was significantly lower among patients with high on-aspirin platelet reactivity. However, only fibrinogen proved to be an independent predictor of hypofibrinolysis in severe COVID-19 patients.

Surprisingly, a faster developing, more solid clot formation was observed in aspirin taking COVID-19 patients. In conclusion, an individually tailored thromboprophylaxis is needed to prevent thrombotic complications, particularly in the hypofibrinolytic cluster.

## Oral Presentation No. 69

### Chronotropic incompetence: still a suitable indicator?

Isabel Cruz<sup>1</sup>†, Inês Oliveira<sup>1</sup>, Bruno Bragança<sup>1</sup>, Rafaela Lopes<sup>1</sup>, Rui Santos<sup>1</sup>, Conceição Queirós<sup>1</sup>, and Aurora Andrade<sup>1</sup>

<sup>1</sup>Centro Hospitalar Tâmega E Sousa E.P.E.

† The presenting author.

**Background:** Chronotropic incompetence (CI) is defined as the inability to increase heart rate (HR) in response to increased activity. It is common in patients (pts) with cardiovascular (CV) disease, being a predictor of major adverse CV events; however, its importance is often underestimated in clinical practice.

**Purpose:** Evaluate the prognostic value of CI in pts with known coronary artery disease (CAD) who performed Bruce protocol treadmill testing.

**Methods:** Unicentric, retrospective analysis of consecutive pts with known CAD who underwent Bruce protocol treadmill testing between 2009 and 2010. Chronotropic index (ChI) was calculated as:  $(\text{peak HR} - \text{resting HR}) / (220 - \text{age} - \text{resting HR})$ . CI was defined as  $\text{ChI} < 80\%$  ( $< 62\%$  in pts prescribed with beta-blockers). Pts were divided in two groups-G1: CI and G2: normal chronotropic response. Events were defined as: *de novo* heart failure (HF), CAD progression, myocardial infarction (MI), stroke, all-cause mortality and CV mortality.

**Results:** A total of 471 pts were included (87.3% male, mean age  $69 \pm 9.8$  years). Mean follow-up was 9.7 years. The groups were similar regarding sex, age, body mass index, diabetes, arterial hypertension, dyslipidemia, MI and left ventricle ejection fraction ( $P > 0.050$ ). CI was identified in 27.4% pts. Comparing G1 vs. G2, no differences were found related to all-cause mortality, *de novo* HF, CAD progression, MI and stroke ( $P > 0.050$ ). However, statistically significant differences were found regarding CV mortality ( $P = 0.028$ ).

**Conclusion:** CI is a simple and easily available parameter that shows a clear association with CV mortality in a long-term follow-up of pts with CAD.

## Oral Presentation No. 75

### Impact of thoracic aortic calcification measured by computed tomography in clinical outcomes in patients undergoing cardiac surgery

Margarida Cabral<sup>1†</sup>, Diana Carvalho<sup>2</sup>, Rita Veiga<sup>3</sup>, Mónica Carvalho<sup>4</sup>, Wilson Ferreira<sup>4</sup>, Rita Faria<sup>4</sup>, Ricardo Ladeiras-Lopes<sup>4</sup>, and Nuno Ferreira<sup>4</sup>

<sup>1</sup>Cardiologia - Chlp - Hospital Santo André Epe – LEIRIA

<sup>2</sup>Centro Hospitalar Baixo Vouga

<sup>3</sup>Hospital Distrital de Santarém

<sup>4</sup>Centro Hospitalar de Vila Nova de Gaia/Espinho

† The presenting author.

The presence of thoracic aortic calcification (TAC) has been shown to increase the risk of cardiovascular and cerebrovascular events. Few studies have evaluated the relationship between CT measured by computed tomography (CT) before cardiac surgery and clinical outcomes, and the relationship is still unclear.

This study aimed to analyse the impact on clinical outcomes of the presence of TAC in patients undergoing cardiac surgery. A retrospective unicentre analysis of patients undergoing a noncontrast CT prior to cardiac surgery was performed. TAC was quantified using a volume-rendering method. The percentiles of TAC volume (TACV) were used to determine the relative standing. Demographic data, risk factors and clinical outcomes were comparable between groups. A  $P$ -value  $< 0.05$  is statistically significant.

The mean TACV was  $2.45 \pm 2.79 \text{ cm}^3$ , and the median and 75th percentiles were 1.45 and  $4.06 \text{ cm}^3$ , respectively. Of the total of 121 patients, 26 (21.5%) had high TACV. Table 1 shows the baseline demographic and risk factors. There was no significant difference in risk factors and personal history between groups except for age ( $P$ -value = 0.02), hypertension ( $P$ -value = 0.04) and coronary artery disease ( $P$ -value  $< 0.01$ ). Regarding clinical outcomes, there was no significant difference in clinical outcomes except for acute kidney failure ( $P$ -value = 0.04), which was not significant in multivariate analysis.

In conclusion, aortic calcification is a recurrent finding, to which there seems to be a contribution from hypertension-related vascular damage, especially in older ones. In patients undergoing cardiac surgery, TACV appears not to be related to clinical outcomes in multivariate analysis. However, large-scale studies are needed to confirm these results.

**Oral Presentation No. 079****Quality of life in patients after pulmonary embolism. Correlation with echocardiographic and biochemical parameters**

OL. Kardakari<sup>1</sup>†, CH. Ballas<sup>1</sup>, LA. Lakkas<sup>1</sup>, SO. Giannou<sup>1</sup>, IL. Stamou<sup>1</sup>, IO. Samara<sup>1</sup>, PE. Kalogeras<sup>1</sup>, KO. Siaravas<sup>1</sup>, EF. Papaioannou<sup>1</sup>, BA. Mpouratzis<sup>1</sup>, SP. Sioros<sup>1</sup>, EK. Lambrinou<sup>2</sup>, GE. Dimakopoulos<sup>3</sup>, ATH. Konstantinidis<sup>4</sup>, KK. Naka<sup>1</sup>, LK. Michalis<sup>1</sup>, and CS. Katsouras<sup>1</sup>

<sup>1</sup>2nd Department of Cardiology, University Hospital of Ioannina, Ioannina, Greece

<sup>2</sup>Cyprus University of Technology, Medical Nursing & Specialties and Gerontology Nursing, Limassol, Cyprus

<sup>3</sup>BIOSTATS, Science and Technology Park, Ioannina, Greece

<sup>4</sup>Department of Respiratory Medicine, University Hospital of Ioannina, Ioannina, Greece

† The presenting author.

**Background:** Pulmonary embolism (PE) is the third most common cause of cardiovascular death worldwide, after stroke and heart attack. Our purpose was to evaluate the patient's health-related quality of life (HR-QoL) after Acute Pulmonary Embolism (APE) and its association with biochemical and novel echocardiographic parameters of assessment of right ventricle (RV).

**Material and methods:** Successive patients with diagnosis of APE in a tertiary hospital were included in the study. RV evaluation and biochemical markers, (including Brain Natriuretic Peptide (BNP)) were recorded during hospitalization. HR-QoL was evaluated with the Greek version of the Pulmonary Embolism Quality of Life questionnaire (PEmb-QoL), at 1 and 3 months after the APE. Repeated measures analysis was used to assess changes in the PEmb-QoL dimensions and Pearson correlations to assess the relationships between RV global longitudinal strain (RV GLS) and the dimensions of PEmb-QoL.

**Results and conclusions:** One hundred consecutive patients were screened; 14 patients were excluded. The study sample consisted of 86 individuals (47 women) aged  $69.7 \pm 13.4$  (mean  $\pm$  SD) years. The differences between the two time points were statistically significant ( $P < 0.001$ ) in all dimensions of HR-QoL. At 3 months, the dimensions of social limitations and intensity of complaints showed the highest rate of improvement. RV GLS values were correlated with quality of life in patient with APE (in 3 of the 6 dimensions of PEmb-QoL). While BNP, was related to the "intensity of complaints" dimension of PEmb-QoL, in patients with APE occurred during hospitalization for another reason (PE wasn't the cause of admission).

**Oral Presentation No. 81**  
**A STEMI case with sub-occlusive lesion and high thrombotic burden – discussing a tailored approach**

Maria Rita Lima<sup>1</sup>†, Luís Raposo<sup>1</sup>, Francisco Albuquerque<sup>1</sup>, Afonso Félix Oliveira<sup>1</sup>, Manuel Almeida<sup>1</sup>, João Abecasis<sup>1</sup>, and Miguel Mendes<sup>1</sup>

<sup>1</sup>Hospital Santa Cruz

† The presenting author.

A 57-year-old man was admitted with an anterior wall STEMI. The patient had a past medical history of pulmonary thromboembolism after an abdominal surgery and peripheral artery disease. After receiving loading doses of aspirin and unfractionated heparin, the patient underwent emergent coronary angiography (CA), that revealed a high thrombotic sub-occlusive lesion in the middle left anterior descending artery (mLAD), with TIMI 3 flow. At the time of CA, the ST elevation had disappeared, and the patient was asymptomatic. PCI had the risk of distal embolization and wiring of the false lumen if a dissection was present. Given the patient stability and absence of pain, the team decided to optimize anti-thrombotic therapy - aspirin + ticagrelor + enoxaparin - and repeat the CA within 72–96 h. The patient remained asymptomatic without angina or heart failure. Repeated CA showed a significant reduction of thrombus in the mLAD, maintaining TIMI 3 flow. A non-obstructive lesion was noted, being unclear if there was plaque rupture or localized dissection. Coronary CT angiography (CCTA) showed a coronary calcium score of 0 and an endoluminal flap in the mLAD, with a partial non-obstructive thrombosis. Echocardiography showed preserved LVEF without segmental abnormalities. Given the good results of anti-thrombotic therapy, the patient was discharged with aspirin, clopidogrel and rivaroxaban 2.5 mg 2id for 2 months and PCI was not performed. A follow-up CCTA within 2 months was scheduled. This case illustrates a complex STEMI case with a high thrombotic burden. The best strategy in such cases is open to debate.

## Oral Presentation No. 082

### Pre-treatment with Dual Antiplatelet Therapy in NSTEMI-ACS: not always, not ever

António Rocha de Almeida<sup>1</sup>†

<sup>1</sup>Hospital Espírito Santo-Évora

† The presenting author.

**Background:** Decision of which antithrombotic therapy strategy for non-persistent ST-segment elevation acute coronary syndromes (NSTEMI-ACS) remains controversial. European Cardiology Society guidelines ceased recommending pretreatment with P2Y<sub>12</sub> receptor inhibitor in NSTEMI-ACS, based on *Accoast Trial*, which demonstrated absence of ischemic benefits and higher bleeding risk. However, sample studied didn't illustrate Portuguese reality.

**Material and methods:** Cohort of 2194 NSTEMI-ACS patients from a multicenter national registry, treated according standard of care, between 2010–2019, was compared with *Accoast Trial* 1996 results of patients no pretreatment sample.

**Results and conclusions:** There was no statistically significant difference on age, sex distribution, aspirin or antithrombin therapy. 96.5% of Portuguese sample were pretreated with dual antiplatelet therapy (DAPT). Trial's sample had median time to coronary angiography (CA) of 4.2 hours and femoral access in 57.0% and Portuguese group had a median time of 12 h-36 h till CA, and femoral access in 11.6%. Just 0.7% had urgent surgery in Portuguese sample. There was more cardiovascular caused deaths, myocardial infarction, stroke, urgent revascularization, or glycoprotein IIb/IIIa bailout (9.8%) on trial sample, against only 5.0% on ours. Pretreatment group had slighter increase of TIMI major bleeding (1.8% vs. 1.4%), with median timing 3.5 days after.

Earlier CA may explain trial's absence of ischemic benefits. Later bleeding complications might be associated with DAPT strategy itself, and not with timing. Due to lack availability, surgery wasn't done before 5 days. Hence, DAPT pretreatment shouldn't be for all NSTEMI-ACS, nevertheless, can be valid option, according to bleeding and ischemic risk, CA timing, access, or surgery availability.



## Oral Presentation No. 083

### Coronary Aspiration Thrombectomy: bringing back the old kid on the block

António Rocha de Almeida<sup>1</sup>†, David Neves<sup>1</sup>, Marta Figueiredo<sup>1</sup>, Miguel Carias Sousa<sup>1</sup>, Francisco Cláudio<sup>1</sup>, Rita Rocha<sup>1</sup>, and Manuel Trinca<sup>1</sup>

<sup>1</sup>Hospital Espírito Santo-Évora

† The presenting author.

**Background:** Traditionally, routine thrombus aspiration during primary percutaneous coronary intervention (PCI) was performed to prevent distal embolization and protect microvascular perfusion. However, recent trials showed no clinical benefits (except if high thrombotic burden). Despite not being routinely recommended, thrombus aspiration should still be considered in highly thrombotic circumstances.

**Material and methods:** Prospective cohort of 50 patients admitted to primary PCI, with aspiration thrombectomy (AT), between 2019–2022, was analyzed. In evidence of high thrombotic burden, AT was performed, if technically possible. Success was evaluated angiographically and by TIMI flow improvement. Safety was assessed by neurologic evaluation, verified CT-scan, in 30 days follow-up.

**Results and conclusions:** 50 patients were analyzed, with mean age of  $59,6 \pm 1,8$  years, being 22% women ( $n = 11$ ). 88% ( $n = 44$ ) presented ST-segment elevation myocardial infarction Killip 1, 2% ( $n = 1$ ) Killip 3 and 10% ( $n = 5$ ) Killip 4. There was thrombus aspiration angiographic evidence in 76% ( $n = 38$ ) and TIMI flow increase in 82% ( $n = 41$ ) cases with median improvement of 2 [IR 1,3]. In 20% ( $n = 10$ ) cases, stent wasn't implanted. There was significant statistical association between no stent PCI and angiographical thrombus reduction ( $P < 0,05$ , OR 3,86). There were no deaths, major adverse cardiovascular events (MACE), or neurologic complications in any patient ( $n = 0$ ) within 30 days.

Routine coronary AT shouldn't be performed. It is useful, however, in selected cases with evidence of angiographic thrombus aspiration and TIMI flow improvement. Successful AT was associated with no stent PCI. Regarding safety, there was no statistically significant increase of death of any cause, MACE, or stroke.

## Oral Presentation No. 84

### Initial clinical experience with 6-hour enoxaparin regimen in opiate-treated patients undergoing primary percutaneous coronary intervention

Nadir Elamin<sup>1†</sup>, Kok Weng Ow<sup>1</sup>, William A.E Parker<sup>1</sup>, Thomas A Nelson<sup>2</sup>, Janet Middle<sup>3</sup>, Jessica Hanson<sup>4</sup>, Bethany Moyle<sup>4</sup>, Arvindra Krishnamurthy<sup>3</sup>, David Barmby<sup>3</sup>, Kenneth Morgan<sup>5</sup>, Zulfiquar Adam<sup>3</sup>, Alexander Rothman<sup>1</sup>, Paul Morris<sup>1</sup>, Javaid Iqbal<sup>3</sup>, Ian Hall<sup>3</sup>, Dwayne Conway<sup>3</sup>, James Richardson<sup>1</sup>, Julian P Gunn<sup>1</sup>, and Robert F Storey<sup>1</sup>

<sup>1</sup>Sheffield Teaching Hospitals; University of Sheffield

<sup>2</sup>Sheffield teaching hospitals; University of Sheffield

<sup>3</sup>Sheffield Teaching Hospitals

<sup>4</sup>University of Sheffield

<sup>5</sup>Sheffield teaching hospitals

† The presenting author.

**Background:** Opioid treatment delays the onset of oral P2Y<sub>12</sub> inhibitors in patients with acute ST-segment elevation myocardial infarction (STEMI), leading to suboptimal antithrombotic therapy during primary percutaneous coronary intervention (PPCI).

**Material and methods:** We retrospectively compared using a prolonged enoxaparin regimen (0.75 mg/kg bolus followed by 6-hour intravenous infusion) to using unfractionated heparin (UFH) with or without tirofiban in opioid-treated patients with STEMI who underwent PPCI. We compared the proportions of acute stent thrombosis (AST) and bleeding events according to the bleeding academic research consortium (BARC) within 24 hours post-PPCI.

**Results:** 270 opioid-treated patients with a mean age of 63 [SD ± 12] years were enrolled, of which 49 (18%) were with diabetes mellitus (DM). 90 (34%) patients (mean age 61 [SD ± 11] years) received enoxaparin, 110 (41%) (mean age 65 [SD ± 14] years) UFH with tirofiban, and 69 (25%) (mean age 63 [SD ± 12] years) UFH only. Compared to the other strategies, a higher proportion of DM was observed in the enoxaparin-treated group (21%). No AST was associated with enoxaparin compared to 2 (1.8%) events in UFH with tirofiban and 1 (1.4%) in UFH only. The rate of severe bleeding events (BARC 2 and 3) was significantly lower in the enoxaparin-treated patients than in UFH with tirofiban (0 (0%) vs. 8 (7%), *P* = 0.01). 3 enoxaparin-treated patients needed switching to tirofiban as a bailout strategy due to distal vessel embolisation.

**Conclusions:** The novel 6-hour enoxaparin regimen is safe during PPCI and was associated with fewer bleeding events than UFH with tirofiban.

**Oral Presentation No. 089****Vascular access computed tomography angiography-derived iliofemoral calcium volume in the evaluation of vascular and bleeding complications after transfemoral TAVI**

Mariana Ribeiro Silva<sup>1</sup>†, Joana Oliveira<sup>2</sup>, Inês Rodrigues<sup>2</sup>, Cláudio Guerreiro<sup>1</sup>, Gualter Santos Silva<sup>1</sup>, Mariana Brandão<sup>1</sup>, Wilson Ferreira<sup>1</sup>, Nuno Ferreira<sup>1</sup>, Gustavo Pires-Morais<sup>1</sup>, Bruno Melica<sup>1</sup>, Lino Santos<sup>1</sup>, Alberto Rodrigues<sup>1</sup>, Pedro Braga<sup>1</sup>, Francisco Sampaio<sup>1</sup>, and Ricardo Fontes-Carvalho<sup>1</sup>

<sup>1</sup>Centro Hospitalar Vila Nova De Gaia / Espinho E.P.E.

<sup>2</sup>Faculdade de Medicina da Universidade do Porto

† The presenting author.

**Background:** We aimed to assess the impact of iliofemoral calcium volume and distribution, as evaluated by computed tomography angiography (CTA), in vascular (VC) and bleeding (BC) complications after transfemoral (TF) TAVI.

**Material and methods:** Patients (pts) who underwent TF TAVI in 2017 (fluoroscopy-guided access) and between 2018 and 2019 (echo-guided access) were included. All pts underwent iliofemoral CTA prior to the procedure and classical CTA-derived data and iliofemoral calcium volume ipsilateral to the puncture site were collected to evaluate its impact on VC and BC, which were defined by VARC-2 criteria.

**Results and conclusions:** We included 221 pts. VC occurred in 22,2% pts (18,6% minor, 3,6% major) and BC in 16,3% pts (13,6% minor, 2,2% major, 0,5% life-threatening). There was a significant lower prevalence of VC (16,4% vs. 28,6%,  $P=0,029$ ) and BC (8,6% vs. 24,8%,  $P=0,001$ ) in the echo-guided group.

Univariate analysis showed that external iliac artery (EIA) and common femoral artery (CFA) luminal minimal diameter and area, CFA maximal luminal diameter were significantly smaller in pts with VC and BC. Sheath to external iliac artery ratio (SEIAR) and sheath to femoral artery ratio (SFAR) were higher in pts with VC and BC.

There were no significant differences in CTA-derived total iliofemoral calcium volume, EIA and CFA calcium volume between pts with or without VC and BC.

In conclusion, iliofemoral calcium volume was not associated with VC and BC after TAVI, while other classical CTA-derived factors such as SEIAR, SFAR, EIA and CFA minimal diameter and area were.

**Oral Presentation No. 090****Pleiotropic effect of antiplatelet ticagrelor: expression of CYP4F2 in HUVEC and HepG2**

Ieva Ciapiene<sup>1</sup>†, Ugne Meskauskaite<sup>1</sup>, Silvija Andruskeviciute<sup>1</sup>, Vaiva Lesauskaite<sup>1</sup>, and Vacis Tatarunas<sup>1</sup>

<sup>1</sup>Institute of Cardiology, Lithuanian University of Health Sciences

† The presenting author.

**Background:** Ticagrelor is a first drug of a new chemical class cyclopentyltriazolopyrimidines and a third-generation P2Y<sub>12</sub> inhibitor that targets and directly binds platelet P2Y<sub>12</sub> receptors. It is recommended to be given as a dual antiplatelet therapy (DAPT) with aspirin for the prevention of thrombotic events and the following ischemic heart disease. Ticagrelor is also known to have pleiotropic effects of unknown mechanisms. It is questioned whether ticagrelor could influence the expression of cytochrome P450 4F2 (CYP4F2) enzyme involved in the resolution of inflammation and biosynthesis of pro-inflammatory eicosanoids. This study aimed to investigate if ticagrelor could alter the expression of CYP4F2 and its encoded protein concentration in both endothelial cells (human umbilical vein endothelial cells, HUVEC) and the metabolism of various xenobiotics performing, CYPs-rich liver cells (HepG2).

**Material and methods:** The expression of CYP4F2 was determined in HUVEC and HepG2 cell lines by qPCR on real time thermal cycler ABI 7900HT (Applied Biosystems, USA). CYP4F2 protein concentration was determined with sandwich enzyme immunoassay kit for CYP4F2 (Cloud-Clone Corp., USA).

**Results and conclusions:** Ticagrelor was observed to reduce the expression of CYP4F2 in HUVEC and HepG2 cell lines. It also reduced CYP4F2 protein levels in HUVEC cells. Thus, ticagrelor may have a protective role in endothelial cells and reduce vascular inflammation.

**Funding sources:** This work was supported by the Research Council of Lithuania under Grant 09.3.3.-LMT-K-712-16-0187.

**Key words:** ticagrelor, CYP4F2, HUVEC, HepG2, ischemic heart disease

## Oral Presentation No. 91

### Valve-in-valve TAVI for treatment of degenerated surgical aortic bioprosthesis

Mariana Ribeiro Silva<sup>1</sup>†, Alberto Rodrigues<sup>1</sup>, Cláudio Guerreiro<sup>1</sup>, Gualter Santos Silva<sup>1</sup>, Pedro Ribeiro Queirós<sup>1</sup>, Mariana Brandão<sup>1</sup>, Diogo Santos-Ferreira<sup>1</sup>, Gustavo Pires-Morais<sup>1</sup>, Bruno Melica<sup>1</sup>, Lino Santos<sup>1</sup>, Pedro Braga<sup>1</sup>, and Ricardo Fontes-Carvalho<sup>1</sup>

<sup>1</sup>Centro Hospitalar Vila Nova De Gaia / Espinho E.P.E.

† The presenting author.

**Background:** We aimed to assess periprocedural and short-term outcomes in patients (pts) undergoing valve-in-valve TAVI for degenerated surgical aortic bioprosthetic (BP) valves.

**Material and methods:** Single-centre retrospective study of consecutive pts undergoing ViV TAVI for failed surgical aortic BP valves between 2007 and 2019. Data were analysed regarding periprocedural events according to the VARC-2 criteria and 30-day and 1-year outcomes.

**Results and conclusions:** TAVI was implanted in 705 pts, of which 43 (6,1%) were ViV TAVI procedures. Prior surgical aortic BP were implanted for a mean  $8,0 \pm 3,2$  years with a label size  $\leq 21$  mm in 66% pts. Surgical BP dysfunction was due to regurgitation (AR), stenosis or a combination of both in 21 (48,8%), 18 (41,9%) or 4 pts (9,3%), respectively.

All pts were treated via transfemoral approach, the majority (84%;  $n = 36$ ) with self-expandable TAVI. ViV TAVI procedural success rate was 98%. Intraprocedural coronary artery obstruction occurred in one pt. Periprocedural adverse events included major vascular complication (7%), major bleeding (7%), stroke (7%), acute kidney injury (19%) and permanent pacemaker implantation (PPI) (2,5%). There was 1 in-hospital death due to cardiogenic shock because of left main coronary artery obstruction.

At discharge, mean aortic gradient (MAVG) was  $20,4 \pm 10$  mmHg, with 45% of the pts presenting  $MAVG \geq 20$  mmHg and 12% AR grade  $\geq$  II. At 30-day follow-up, no death or heart failure hospital admission was reported. One-year mortality was 7,1%.

In conclusion, ViV TAVI in degenerated surgical aortic BP was a safe procedure with persistence of favourable clinical results in this high-risk population.

## Oral Presentation No. 093

### Assessing different noncoding RNAs as markers of platelet reactivity

Clemens Gutmann<sup>1†</sup>, Temo Barwari<sup>1</sup>, Christian Schulte<sup>1</sup>, Bhawana Singh<sup>1</sup>, Konstantinos Theofilatos<sup>1</sup>, Abhishek Joshi<sup>1</sup>, Anna Zampetaki<sup>1</sup>, Melissa V Chan<sup>2</sup>, Paul C Armstrong<sup>2</sup>, Stefan Kiechl<sup>3</sup>, Johann Willeit<sup>3</sup>, Timothy D Warner<sup>2</sup>, and Manuel Mayr<sup>1</sup>

<sup>1</sup>King's British Heart Foundation Centre, King's College London, United Kingdom

<sup>2</sup>The Blizard Institute, Barts and The London School of Medicine and Dentistry, Queen Mary University, London, United Kingdom

<sup>3</sup>Department of Neurology, Medical University Innsbruck, Austria

† The presenting author.

**Background:** Antiplatelet therapy (APT) has improved cardiovascular outcomes, but some patients develop thrombosis despite APT. Adjusting APT to platelet reactivity with conventional platelet reactivity tests has proven unsuccessful. Many circulating noncoding RNAs (ncRNAs) are derived from platelets and could serve as novel platelet function markers.

**Material and methods:** Platelet reactivity was assessed using light transmission aggregometry (LTA) in the Bruneck 2015 study ( $N=338$ ), using the agonists arachidonic acid, adenosine diphosphate, collagen, TRAP-6 amide and U46619. LTA platelet releasates were then used for RT-qPCR of five platelet-enriched microRNAs, three circular RNAs and two long non-coding RNAs. Platelet-poor plasma (PPP) was used as negative control.

**Results and conclusions:** Platelet agonists induced aggregation and ncRNA release, with aspirin takers ( $N=155$ ) showing lower ncRNA release than individuals not on aspirin ( $N=183$ ). Agonist responsiveness differed among ncRNAs, with miR-150 being hyperresponsive to adenosine diphosphate and miR-21 being hyperresponsive to arachidonic acid, whereas other ncRNAs were most strongly released to collagen, suggesting a selective release mechanism. In individuals not on aspirin, the inflammation markers C-reactive protein and granulocyte counts correlated positively with platelet-derived ncRNAs in PPP, while they correlated inversely with platelet-derived ncRNAs in releasates. These correlations were not present in aspirin takers. Higher PPP levels and lower releasate levels of platelet-derived ncRNAs in inflammation suggest platelet exhaustion *ex vivo* due to platelet pre-activation *in vivo*.

**Funding sources:** British Heart Foundation, VASCage (Centre for Promoting Vascular Health in the Ageing Community) of the Austrian Research Promotion Agency FFG (COMET program - Competence Centers for Excellent Technologies).

**Oral Presentation No. 096**  
**Impact of Inflammatory and Hematological Factors to The Left Ventricle Function, Remodeling, and Clinical Outcomes after The First Myocardial Infarction**

Nina Korac<sup>1</sup>† and Milica Dekleva<sup>2</sup>

<sup>1</sup>Blood Transfusion Institute of Serbia

<sup>2</sup>University Clinical Center Zvezdara

† The presenting author.

**Background:** It is known that hematological and inflammatory factors can affect the prognosis of patients with AMI, but the interpretations are different.

**Material and methods:** The study included 182 patients with their first AMI age < 70 years. Inflammatory (CRP, Sedimentation and Leukocytes), hematological factors (Platelets, Iron, Hct) and coronary status were obtained at admission. Doppler echocardiography was performed two days after admission and after 6 months. The degree of heart failure was assessed by clinical examination.

**Results and conclusions:** Remodeling of LV, measured by LV volume increase and Sphericity index was closely related to Sedimentation level ( $P=0.013$ ;  $P=0.028$ ). Sedimentation was related to systolic function measured by LVEF ( $P=0.011$ ) and with diastolic dysfunction measured by E/e ratio ( $P<0.001$ ). A significant impact of CRP on LVEF ( $P=0.028$ ) and degree of diastolic dysfunction ( $P=0.024$ ) was estimated. Iron level had an effect on LVEF ( $P=0.017$ ), while E/e was negatively correlated with Iron ( $P=0.005$ ). The degree of heart failure was positively correlated with the level of Iron and Sedimentation. Sedimentation level of 22.5 cut off had a sensitivity of 75%, a specificity of 52% in predicting NYHA III and IV. Iron level of 8.1 has a sensitivity of 72.4%, specificity of 57.9% in predicting NYHA III and IV. There were no significant correlations between coronary status and inflammation parameters. Inflammatory hematological status of patients is associated with changes in the morphology and function of the LV after the first MI. The sedimentation level and CRP contribute to a better risk stratification for the severity of heart failure.

**Oral Presentation No. 105**  
**Endothelial dysfunction and alterations in erythrocyte function in a murine model of chronic heart failure**

Tasnim Mohaisen<sup>1†</sup>

<sup>1</sup>Jagiellonian Centre for Experimental Therapeutics (JCET)

† The presenting author.

Endothelial dysfunction (ED) and red blood cell distribution width (RDW) are both prognostic factors in heart failure (HF), but the relationship between them is not clear. In this study, we used a unique mouse model of HF to characterize the relationship between the development of peripheral ED and the occurrence of structural nanomechanical and biochemical changes in red blood cells (RBCs).

**Methods and results:** Systemic ED was detected in vivo in 8-month-old Tg $\alpha$ \*44 mice, as evidenced by impaired acetylcholine-induced vasodilation in the aorta. ED in the aorta was associated with impaired nitric oxide (NO) production in the aorta and diminished systemic NO bioavailability (characterized by increased superoxide and eicosanoid production). In 4- to 6-month-old Tg $\alpha$ \*44 mice, RBC size and membrane composition displayed alterations that did't result in significant changes in their nanomechanical and functional properties. However, 8-month-old Tg $\alpha$ \*44 mice presented accentuated structural, size changes and increased RBC stiffness. In 12-month-old Tg $\alpha$ \*44 mice, the erythropathy was featured by altered RBC shape and elasticity, increased RDW, impaired RBC deformability. Moreover, RBCs taken from 12-month-old Tg $\alpha$ \*44 mice, coincubated with aortic rings from FVB mice, induced impaired endothelium-dependent vasodilation and this effect was partially reversed by arginase inhibitor.

**Conclusion:** In the Tg $\alpha$ \*44 murine model of HF, systemic ED accelerates erythropathy and, conversely, erythropathy may contribute to ED. These results suggest that erythropathy may be regarded as a marker and a mediator of systemic ED in HF. RBC arginase and possibly other RBC-mediated mechanisms may represent novel therapeutic targets for systemic ED in HF.



**Oral Presentation No. 107****Achieving higher efficacy without compromising safety with Factor XI inhibitors versus low-molecular-weight heparin for the prevention of venous thromboembolism in major orthopedic surgery – Systematic Review and Meta-Analysis**João Presume<sup>1</sup>†, Jorge Ferreira<sup>1</sup>, Regina Ribeiros<sup>1</sup>, and Miguel Mendes<sup>1</sup><sup>1</sup>Hospital Santa Cruz

† The presenting author.

**Background:** In recent years, many important advances have been seen in anticoagulation therapy. However, bleeding risk is still a major concern. Factor XI inhibition has emerged as a potential advantageous target to minimize this risk.

**Objectives:** We conducted a systematic review and meta-analysis of current evidence on factor XI inhibitors for thromboprophylaxis in major orthopedic surgery.

**Methods:** We performed a systematic search of electronic databases (Pubmed, CENTRAL, and Scopus) until May of 2022. Studies were considered eligible if they were RCTs evaluating factor XI inhibitors in thromboprophylaxis vs. low-molecular-weight heparins (LMWH). For analysis purposes, we considered efficacy (Venous Thromboembolism [VTE], symptomatic VTE) and safety (major and clinically relevant non-major [CRNM] bleeding events; major bleeding events; blood transfusion necessities; adverse events; major adverse events) outcomes.

**Results:** Overall, 4 RCTs were included, with a total of 2269 patients, 372 VTE events, and 50 major or CRNM bleeding events. Regarding efficacy outcomes, factor XI inhibitors were associated with a significant reduction in the incidence of VTE events (OR 0.50; 95%CI [0.36, 0.69]). Concerning safety outcomes, factor XI inhibitors significantly reduced major or CRNM bleeding events (OR 0.41 [0.22; 0.75]). It was also associated with a lower percentage of patients needing a blood transfusion, despite not meeting statistical significance (OR 0.69; 95%CI [0.32; 1.48]). Incidence of adverse events and major adverse events were similar between groups.

**Conclusion:** Factor XI inhibitors showed a significant reduction in the incidence of VTE and bleeding events among patients submitted to major orthopedic surgery.

## Oral Presentation No. 112

### Treatment of pulmonary embolism after paradoxical stroke

Mariana Martinho<sup>1</sup>†, Nuno Cotrim<sup>2</sup>, Melanie Ferreira<sup>1</sup>, Rita Calé<sup>1</sup>, Filipa Ferreira<sup>1</sup>, Vilma Grilo<sup>1</sup>, Eugeniu Gisca<sup>1</sup>, Ana Glória Fonseca<sup>1</sup>, Ana Gomes<sup>1</sup>, Tiago Judas<sup>1</sup>, Hélder Pereira<sup>1</sup>, and Francisca Delerue<sup>1</sup>

<sup>1</sup>Hospital Garcia De Orta, E.P.E.

<sup>2</sup>Hospital Distrital de Santarém, E.P.E.

† The presenting author.

**Introduction:** A patent foramen ovale (PFO) is often diagnosed in cryptogenic strokes and concurrent pulmonary embolism (PE) may be associated. Although often asymptomatic and with low recurrence risk, the best therapy is controversial.

**Purpose:** To study the results of oral anticoagulation (OAC) in this population.

**Methods:** Retrospective single-centre study (2015–2020) of pts with asymptomatic PE diagnosed after a paradoxical stroke due to a PFO.

**Results:** Forty pts were included. Mean age was  $56 \pm 11$  years and 55% were female. At diagnosis, 27.5%, 50.0%, 17.5% and 5.9% had none, weak, moderate and strong predisposing factors for PE, respectively. Most pts had peripheral events: 60.0% subsegmental, 37.5% segmental and 2.5% lobar.

Regarding treatment, 97.5% initiated OAC (90.0% direct OAC, 7.5% vitamin K antagonist); 1 pt single antiaggregation; 30% had percutaneous PFO closure.

Mean clinical follow-up (FUP) was  $32 \pm 22$  months. There was 1 recurrent PE and 1 non-cardiovascular death. Mean time under OAC (TUOAC) was  $27 \pm 26$  months. The only predictor of OAC suspension was PFO closure (17.9% vs. 50.0%,  $P=0.037$ ). Of these pts, 50.0% suspended OAC after the procedure (TUOAC  $23.2 \pm 17.9$  months); the remaining had a TUOAC of  $28.9 \pm 29.9$  months. Age or PE predisposing factors were not associated with OAC suspension or TUOAC. There were 3 clinically relevant haemorrhagic events (1 BARC3a, 1 BARC3b, 1 BARC3c). TUOAC was neither associated with bleeding ( $P=0.307$ ) nor with perfusion defects resolution in FUP scintigraphy ( $55.5$  vs.  $16.0$  months,  $P=0.172$ ).

**Conclusions:** TUOAC was not associated with perfusion defects resolution, ischemic or bleeding events. Management of these pts needs more evidence and consensus.

## Oral Presentation No. 114

### Small-bore aspiration thrombectomy versus catheter-directed thrombolysis in intermediate-high risk acute Pulmonary Embolism

Mariana Martinho<sup>1</sup>†, Rita Calé<sup>1</sup>, Ana Rita Pereira<sup>1</sup>, Filipa Ferreira<sup>1</sup>, Sofia Alegria<sup>1</sup>, Gonçalo Morgado<sup>1</sup>, Cristina Martins<sup>1</sup>, Melanie Ferreira<sup>1</sup>, Ana Gomes<sup>1</sup>, Tiago Judas<sup>1</sup>, Filipe Gonzalez<sup>1</sup>, Corinna Lohmann<sup>1</sup>, Débora Repolho<sup>1</sup>, Pedro Santos<sup>1</sup>, Ernesto Pereira<sup>1</sup>, Maria José Loureiro<sup>1</sup>, and Hélder Pereira<sup>1</sup>

<sup>1</sup>Hospital Garcia De Orta, E.P.E.

† The presenting author.

**Introduction:** Catheter-directed thrombolysis (CDT) and mechanical thrombectomy (MT) are treatment options in intermediate-high risk pulmonary embolism (IHRPE).

**Purpose:** Compare the efficacy and safety of CDT and MT in IHRPE.

**Methods:** Retrospective single-centre study of consecutive IHRPE patients (pts) since 2018, treated with CDT (5Fr Cragg-McNamara device) or MT (Indigo MT system, Penumbra 8Fr). Clinical success at 48h was defined as survival and haemodynamic (HD) stabilization, oxygenation improvement or decrease in pulmonary hypertension (PH)/right heart strain. MACE during follow-up (FUP) was a composite endpoint of cardiovascular mortality, PE recurrence, chronic thromboembolic PH and heart failure hospitalization. Safety endpoint was defined as Major bleeding (BARC3).

**Results:** Of 25 pts, 60% were submitted to MT and 40% to CDT. Age ( $68.6 \pm 15.6$  vs.  $62.7 \pm 16.4$ ,  $P=0.381$ ), Charlson Comorbidity Index ( $4.2 \pm 1.9$  vs.  $2.9 \pm 2.0$ ,  $P=0.121$ ) and PESI score ( $103.2 \pm 40.6$  vs.  $119.8 \pm 46.2$ ,  $P=0.410$ ) were similar. MT had increased fluoroscopy time ( $43.0 \pm 19.1$  vs.  $10.1 \pm 6.2$  min,  $P < 0.001$ ) and procedure time ( $115 \pm 63$  vs.  $45 \pm 18$  min,  $P=0.009$ ). Success at 48h was similar (80% MT vs. 90% CDT;  $P=0.626$ ). Severe adverse events related with the technique happened in 2 pts in MT (1 death, 1 macroembolization) and 1pt in CDT developed HD instability. Haemoglobin fall was higher in MT ( $1.8 \pm 1.3$  vs.  $0.7 \pm 0.8$  g/dL,  $P=0.018$ ), but BARC3 and transfusion were identical. In-hospital mortality was 8% (2 pts in MT,  $P=0.229$ ). Mean FUP was  $229 \pm 147$ days, with higher MACE in MT (40% vs. 0%,  $P=0.051$ ).

**Conclusions:** Despite similar efficacy at short-term, adverse events related to the procedure seemed higher in MT group. CDT was less time consuming.

**Oral Presentation No. 121**  
**Aortic stiffness descriptors by cardiac magnetic resonance are correlated with mechanical testing of ex-vivo aortic aneurysms specimens**

Aroa Ruiz Muñoz<sup>1</sup>†, Andrea Guala<sup>1</sup>, Myriam Cilla<sup>2</sup>, Miguel Martínez<sup>2</sup>, Lydia Dux-Santoy<sup>1</sup>, Gisela Teixidó-Turà<sup>1</sup>, Juan Garrido-Oliver<sup>1</sup>, Laura Galian<sup>1</sup>, Augusto Sao-Aviles<sup>1</sup>, Arturo Evangelista<sup>1</sup>, Ignacio Ferreira-Gonzalez<sup>1</sup>, Estefania Peña<sup>2</sup>, and Jose Rodriguez-Palomares<sup>1</sup>

<sup>1</sup>Hospital Universitari Vall Hebron

<sup>2</sup>Universidad de Zaragoza

† The presenting author.

**Background:** Aortic stiffness independently predicts mayor adverse cardiovascular events and mortality in the general population. Cardiovascular magnetic resonance (CMR) permits the assessment of a number of parameters theoretically linked to aortic stiffness, such as distensibility (AD), pulse wave velocity (PWV) and proximal aorta longitudinal strain. However, no previous study validates these parameters as descriptors of aortic wall stiffness against ex-vivo mechanical testing.

**Materials and methods:** Ascending aorta (AAo) specimens were collected from 20 patients undergoing AAO replacement for aneurysms. Patients underwent a CMR protocol in the days leading to the surgery, including 4D flow CMR. Two 15×5 mm specimens (one oriented in the circumferential and the other in the longitudinal aortic direction) were extracted during surgery, and later tested controlling for extension force. Elongation was measured by laser video extensometer and the tangent of the stress-strain curve at diastolic pressure was extracted. AAO PWV and the Eh product (E being Young modulus and h wall thickness) were measured from 4D flow CMR while AD and AAO longitudinal were quantified from cine images.

**Results and conclusions:** Marked correlations were found between circumferential elastic modulus and AAO AD ( $R = -0.502$ ), PWV ( $R = 0.652$ ) and Eh ( $R = 0.602$ ). Similarly, strong correlation was identified between AAO longitudinal strain and longitudinal elastic modulus ( $R = -0.513$ ). In conclusion, PWV and the Eh product are positively related to aortic wall stiffness while aortic distensibility and strain show negative relationships. Thus, these biomarkers are a reliable expression of aortic wall stiffness.

**Funding:** PI17/00381, SEC/FEC-INV-CLI20/015, LCF/BQ/PR22/11920008.

**Oral Presentation No. 125****Relation of non-invasively measured ankle-brachial index and pulse-wave velocity towards all-cause mortality in unselected emergency department patients - a prospective cross-sectional study**Sebastian Schnaubelt<sup>1</sup>, Felix Eibensteiner<sup>1</sup>, Julia Oppenauer<sup>1</sup>, Hans Domanovits<sup>1</sup>, and Oliver Schlager<sup>1</sup>†<sup>1</sup>Medical University of Vienna, Vienna (Austria)

† The presenting author.

**Background:** Increased pulse-wave velocity (PWV) and decreased ankle-brachial index (ABI) are related to an increased risk of all-cause- as well as cardiovascular mortality. Aim of this study was to assess the predictive value of PWV and ABI in an emergency department (ED) setting.

**Methods:** We assessed ABI-, brachial-ankle (ba) PWV-, and carotid-femoral (cf) PWV in patients presenting to a high-volume tertiary care ED. Primary outcome was all-cause mortality in the long-term follow-up of these patients, which was evaluated via Austria's federal statistical office.

**Results:** We included 1,041 patients ( $60 \pm 17$  years; 56.6% males) with various chief complaints (e.g., chest pain, dyspnea, atrial fibrillation). ABI and cfPWV could be measured in 952 (91.5) and 910 (87.4%), respectively. Values of ABI ( $1.03 \pm 0.13$ ) and cfPWV ( $10.1 \pm 2.9$  m/s) were found to be pathological in 13.4% and 44.8%, respectively. Median follow-up time was 540 [344–877] days. During this observational period, 8.1% of patients had died; the majority of deaths was classified as cardiovascular events. Overall mortality differed significantly between patients with pathological ABI or elevated cfPWV ( $P < 0.001$ ) compared with those patients without pathological alterations. Even after multivariate cox-proportional hazard analysis (including age(-groups), sex, BMI and comorbidities), a pathological ABI (HR 0.07 [0.01–0.56],  $P = 0.01$ ) and cfPWV (HR 1.13 [1.04–1.23],  $P = 0.003$ ) were associated with overall mortality risk.

**Conclusion:** In unselected ED patients a pathological ABI or PWV are independent predictors for long-term mortality and may be used as an additional risk stratification tool in the emergency setting.

## Oral Presentation No. 126

### NOACs safety and efficacy in Adult Congenital Heart Disease

Ricardo Jorge Reis Alves Pinto<sup>1</sup>, Miguel Martins Carvalho<sup>1</sup>, Tânia Proença<sup>1</sup>, Catarina Costa<sup>1</sup>, Ana Filipa Amador<sup>1</sup>, João Calvão<sup>1</sup>, Catarina Marques<sup>1</sup>, André Cabrita<sup>1</sup>, Luís Santos<sup>1</sup>, Cátia Oliveira<sup>1</sup>†, Ana Pinho<sup>1</sup>, Cristina Cruz<sup>1</sup>, and Filipe Macedo<sup>1</sup>

<sup>1</sup>Centro Hospitalar São João E.P.E.

† The presenting author.

**Introduction:** Adult Congenital Heart Disease (ACHD) patients are an increasing population with known high risk for thromboembolic events. Validated scores are uncertain in this population. Although apparently safe, data is scarce about the use of NOAC.

**Purpose:** To evaluate all patients on-NOAC followed in an ACHD outpatients clinic and observe its safety and efficacy during a median follow-up of 34 months (IQR 7–60 months). Major bleeding was defined according to types 3 to 5 in BARC scale. Adverse event was defined as  $\geq 1$  of the follows: death, stroke, myocardial infarction, systemic embolism or major bleeding.

**Results:** A total of 65 patients were included, with a mean age of  $52 \pm 14$  year-old, 66% female. Most frequent ACHD were atrial septal defect (22%) and tetralogy of Fallot (22%), followed by atrioventricular septal defect (17%) and transposition of great arteries (9%). Most patients had preserved biventricular function, 20% presented systemic ventricle systolic dysfunction and 12% subpulmonic ventricle systolic dysfunction. Atrial fibrillation or atrial flutter (AF/AFL) were the major reasons for anticoagulation (94%); the remaining were on NOAC due to previous ischaemic stroke, intra-cardiac thrombus or deep venous thrombosis. At the time of NOAC initiation, 49% had a CHA<sub>2</sub>DS<sub>2</sub>-VASc score  $\geq 2$  (median 1, IQR 1-3) and median HAS-BLED score was 0 (IQR 0-2); 43% were medicated with apixaban, 29% with rivaroxaban, 22% with edoxaban and 6% with dabigatran. During a median follow-up of 34 months, none had ischaemic complications or major bleeding and one patient died after pulmonic prosthesis dysfunction surgery. Concerning time-to-adverse-event analysis, all patients kept uneventful after 2 years and more than 95% continued event-free after 8 years on-NOAC.

## Poster No. 004 Cardiovascular and metabolic effects of ovarian suppression as adjuvant therapy for early breast cancer: a systematic review and meta-analysis

Ying Gue<sup>1†</sup>

<sup>1</sup>University of Liverpool

† The presenting author.

**Background:** Adjuvant endocrine therapy is key treatment in early oestrogen receptor positive breast cancer (BC). In premenopausal BC ovarian function suppression (OFS) in combination with tamoxifen or aromatase inhibitor (AI) is commonly used, particularly in high-risk patients who have received chemotherapy. The profound suppression of circulating oestradiol associated with OFS could have adverse cardiovascular and metabolic effects. We aim to evaluate the reported adverse effects within randomised phase III trials in premenopausal women with BC.

**Methods:** A systematic search of online databases was conducted to identify randomised control trials (RCTs) involving OFS which reported adverse events (hypertension, weight gain, thrombosis, cardiac ischemia, glucose intolerance and hyperglycemia). Pooled odds ratios (OR) with 95% confidence interval (CI) were estimated using a random-effects model.

**Results:** Four RCTs were included in the meta-analysis with a total of 7808 patients, separated into 3 main treatment groups: Tamoxifen, OFS plus Tamoxifen and OFS plus AI. We found that OFS increased risk of hypertension when compared to Tamoxifen alone (7.6% vs. .4.8%, OR 1.49, 95%CI 1.09–2.01;  $P=0.01$ ). Tamoxifen with OFS increased risk of thrombosis when compared to AI with OFS (1.7% vs. .0.7%, OR 2.87, 95%CI 1.19–6.9;  $P=0.02$ ).

**Conclusions:** This highlights the possible impact of OFS in premenopausal women as it increases risk of developing hypertension which may require closer monitoring and initiation of early treatment. There appears to be a protective effect of AI when compared to Tamoxifen in terms of thrombosis. Further studies are needed to explore the impact of these drugs on the cardiovascular health of these young women with BC.

## Poster No. 005 Platelet Thromboxane Inhibition by Low-Dose Aspirin in Polycythemia Vera: Ex Vivo and In Vivo Measurements and In Silico Simulation

Giovanna Petrucci<sup>1†</sup>, Alberto Giaretta<sup>2</sup>, Paola Ranalli<sup>3</sup>, Viviana Cavalca<sup>4</sup>, Alfredo Dragani<sup>3</sup>, Benedetta Porro<sup>4</sup>, Duaa Hatem<sup>1</sup>, Aida Habib<sup>5</sup>, Elena Tremoli<sup>6</sup>, Carlo Patrono<sup>1</sup>, and Bianca Rocca<sup>1</sup>

<sup>1</sup>Department of Safety and Bioethics, Section of Pharmacology, Catholic University School of Medicine, Rome, Italy

<sup>2</sup>Department of Pathology, University of Cambridge, Cambridge, UK

<sup>3</sup>Department of Hematology, S. Spirito Hospital, Pescara, Italy

<sup>4</sup>Centro Cardiologico Monzino, IRCCS, Milano, Italy

<sup>5</sup>Department of Basic Medical Sciences, QU Health, Qatar University, Doha, Qatar

<sup>6</sup>Maria Cecilia Hospital, Cotignola, Italy

† The presenting author.

**Background:** Low-dose aspirin is currently recommended for patients with polycythemia vera (PV), a myeloproliferative neoplasm with increased risk of arterial and venous thromboses. Based on aspirin pharmacodynamics in essential thrombocythemia, a twice-daily regimen is recommended for PV patients deemed at particularly high thrombotic risk.

**Methods:** We investigated the effects of low-dose aspirin on platelet cyclooxygenase activity and *in vivo* platelet activation in 49 PV patients, as assessed by serum thromboxane (TX)<sub>2</sub> and urinary TXA<sub>2</sub>/TXB<sub>2</sub> metabolite (TXM) measurements, respectively. A previously described pharmacokinetic-pharmacodynamic *in silico* model was used to simulate the degree of platelet TXA<sub>2</sub> inhibition by once-daily and twice-daily aspirin, and to predict the effect of missing an aspirin dose during qd and bid regimens.

**Results:** Serum TXB<sub>2</sub> averaged 8.2 [1.6–54.7] ng/ml and significantly correlated with the platelet count ( $\rho = 0.39$ ) and urinary TXM ( $\rho = 0.52$ ) in multivariable analysis. One-third of aspirin-treated PV patients displayed less-than-maximal platelet TXB<sub>2</sub> inhibition, and were characterized by significantly higher platelet counts and platelet-count corrected serum TXB<sub>2</sub> than those with adequate inhibition. Eight PV patients were sampled again after  $12 \pm 4$  months, and had reproducible serum TXB<sub>2</sub> and urinary TXM values. The *in silico* model predicted complete inhibition of platelet-derived TXB<sub>2</sub> by bid aspirin, a prediction verified in a PV patient with the highest TXB<sub>2</sub> value while on aspirin qd and treated short-term with a bid regimen.

**Conclusions:** In conclusion, one in three PV patients on low-dose aspirin display less-than-maximal inhibition of platelet TXA<sub>2</sub> production. A personalized approach to antiplatelet therapy can be guided by serum TXB<sub>2</sub> measurements.



## Poster No. 009 In-hospital bleeding in acute coronary syndrome: new antithrombotics, old problems

Vanessa Lopes<sup>1</sup>†, Nádia Moreira<sup>1</sup>, Rafaela Fernandes<sup>1</sup>, Gil Cunha<sup>1</sup>, José Pedro Sousa<sup>1</sup>, João Lopes<sup>1</sup>, James Milner<sup>1</sup>, Vera Marinho<sup>1</sup>, Sílvia Monteiro<sup>1</sup>, Pedro Monteiro<sup>1</sup>, Francisco Gonçalves<sup>1</sup>, and Lino Gonçalves<sup>1</sup>

<sup>1</sup>Centro Hospitalar E Universitário De Coimbra

† The presenting author.

**Background:** Progress in decreasing ischemic complications in acute coronary syndrome (ACS) has come at the expense of increased risk of bleeding. This study sought to determine the incidence, predictors, and prognosis of in-hospital bleeding (IHB) in ACS patients.

**Material and methods:** We retrospectively analyzed patients consecutively admitted to the coronary care unit (CCU) with ACS. Patients who suffered clinically significant IHB were compared to the remaining ACS patients. The primary endpoint was all-cause in-hospital death.

**Results and conclusions:** From a total of 1032 ACS patients, clinically significant IHB was identified in 5.6% ( $n = 58$ ) of patients, of whom 13 patients presented serious bleeding. Patients with IHB were older ( $P = 0.003$ ), more often female ( $P = 0.012$ ), were more likely to have prior heart failure ( $P = 0.007$ ) and chronic kidney disease ( $P = 0.001$ ). At admission, they presented more often with Killip-Kimball class  $> I$  ( $P = 0.001$ ), lower hemoglobin ( $P = 0.013$ ), lower eGFR ( $P = 0.005$ ), and a higher CRUSADE score ( $P < 0.001$ ). In multivariate logistic regression, female sex (OR = 2.26, 1.17–4.38,  $P = 0.023$ ), acute kidney injury (OR = 2.23, 1.12–4.45,  $P = 0.028$ ), and non-radial access in coronary angiography (OR = 2.04, 1.08–3.87,  $P = 0.028$ ), were identified as independent predictors of IHB.

The primary endpoint occurred in 5.8% of ACS patients. Patients who suffered IHB were at higher risk of death during hospitalization (OR = 2.39, 95% CI 1.03–5.51,  $P = 0.042$ ), but not during the 2-year follow-up ( $P = 0.429$ ).

In conclusion, IHB is not an uncommon complication in ACS patients and is associated with an increased risk of in-hospital mortality.

## Poster No. 012 Premature myocardial infarction: a decade-long analysis of patients admitted to a single-center coronary care unit

Vanessa Lopes<sup>1</sup>†, Nádia Moreira<sup>1</sup>, Rafaela Fernandes<sup>1</sup>, Gil Cunha<sup>1</sup>, Gonçalo Costa<sup>1</sup>, Eric Monteiro<sup>1</sup>, Diogo Fernandes<sup>1</sup>, Joana Guimarães<sup>1</sup>, João Ferreira<sup>1</sup>, James Milner<sup>1</sup>, Vera Marinho<sup>1</sup>, Sílvia Monteiro<sup>1</sup>, Pedro Monteiro<sup>1</sup>, Francisco Gonçalves<sup>1</sup>, and Lino Gonçalves<sup>1</sup>

<sup>1</sup>Centro Hospitalar E Universitário De Coimbra

† The presenting author.

**Background:** Despite being primarily a disease of older patients, acute myocardial infarction (AMI) has been increasingly recognized in young individuals. This study sought to characterize and determine the prognosis of AMI in patients aged  $\leq 45$  years old.

**Methods:** We retrospectively analyzed patients consecutively admitted to the coronary care unit with AMI. Two groups were identified: patients aged  $\leq 45$  and  $> 45$  years old.

**Results and conclusions:** A total of 5696 AMI patients were included in the analysis: median age of 70 (IQR 19) years and 68.6% ( $n = 3906$ ) were male; 5.6% ( $n = 318$ ) of patients were aged  $\leq 45$  years old.

In contrast to the older patients, those aged  $\leq 45$  years old were more likely to be male ( $P < 0.001$ ), presented more often with a history of smoking ( $P < 0.001$ ), and family history of premature coronary artery disease ( $P < 0.001$ ), but less often hypertension, hyperlipidemia, and diabetes.

In coronary angiography, most younger patients presented a single-vessel disease (57.1%), more commonly affecting the left anterior descending artery (51.7%); left main involvement was rare (0.8%); and 14.2% presented MINOCA (vs. 11.4% of older patients).

Regarding prognosis, 6.4% ( $n = 366$ ) of patients died in the hospital and 24.2% ( $n = 1380$ ) died during the 5-year follow-up. Younger patients had a lower risk of in-hospital mortality (OR 0.22, 95% CI 0.09–541,  $P = 0.001$ ) and 5-year mortality (OR 0.12, 95% CI 0.06–0.201,  $P < 0.001$ ), compared to the older patients.

In conclusion, patients with premature AMI have a different proportion of risk factors, less extensive coronary artery disease, and more commonly present MINOCA, compared to the older patients.

## Poster No. 013 Development of Small and Wide Angle X-ray Scattering to Investigate the Stability of Atherosclerotic Plaque

Rebecca Mackley<sup>1</sup>† and Tara Schiller<sup>1</sup>

<sup>1</sup>University of Warwick

† The presenting author.

Atherosclerosis is often described as a single disease entity however the size and composition of each plaque is unique to the individual. Thus, the field currently lacks a technique that can discriminate stable from unstable plaques to identify those being at risk of suffering a thromboembolic event in the near future. There exists a perfect opportunity to develop a non-invasive imaging technique or device that would be able to discriminate between different plaques at multiple locations in an artery. Such a device requires extensive chemical, structural, and spatial information available on the different plaque components to define the stability of the plaque. With informed consent and approved ethics, human carotid endarterectomy specimens were collected, fixed and mounted in Kapton tape, which is an ideal substrate for use with x-rays. Small-angle x-ray scattering was used to gather information on the size, shape and structure of the constituents of a plaque such as collagen and lipid-based materials. Then wide-angle x-ray scattering was used to readily determine the crystalline materials such as crystalline cholesterol and hydroxyapatite. Results currently indicate that this technique can discriminate between crystalline cholesterol, cholesteryl esters, phospholipids, collagen, elastin, hydroxyapatite and other calcium-based salts. This technique can map across the face of the plaque indicating the co-location of materials. In particular, for the crystalline materials, the crystalline planes can be indexed showing how the material grows in the plaque. Relating this information back to patient data can help identify features of a vulnerable plaque.

**Funding sources:** Medical Research Council, UK.

## Poster No. 014 Diurnal and weekly variation in thrombotic and fibrinolytic status in healthy individuals

Vassilios P. Memtsas<sup>1</sup>†, Ying X. Gue<sup>2</sup>, Rahim Kanji<sup>1</sup>, and Diana A. Gorog<sup>1</sup>

<sup>1</sup>National Heart and Lung Institute, Imperial College London

<sup>2</sup>University of Liverpool

† The presenting author.

**Background:** Studies assessing individual enzymatic markers of fibrinolysis in healthy volunteers and patients with coronary artery disease indicate circadian variation. This is thought to be primarily attributable to changes in plasma plasminogen activator inhibitor-1 (PAI-1). It is unknown, whether elevated PAI-1 levels in plasma translate into a global impairment of fibrinolysis.

**Methods:** A single centre, prospective, observational study was conducted in 50 healthy volunteers. Native, non-anticoagulated whole blood samples were obtained at two different time points on the same day, 8–12 hours apart. Furthermore, global thrombotic and fibrinolytic status over time was assessed by obtaining samples from 20 volunteers weekly, at the same time of day, for 4 weeks. The Global Thrombosis test was used to assess time taken to form an occlusive thrombus under high shear (occlusion time) and time taken for spontaneous restart of flow as a measure of endogenous fibrinolysis (lysis time).

**Results:** There was no significant difference between the morning and evening thrombotic occlusion time (delta  $-25.6[\pm 100.7]$  sec,  $P=0.079$ ) or between the morning and evening endogenous fibrinolysis time (delta  $82.5[|QR-272-307]$ sec,  $P=0.397$ ). Over the course of 4 weeks there was no statistically significant variation in occlusion time ( $P=0.542$ ) or lysis time ( $P=0.562$ ) between the different weekly visits within individuals.

**Conclusion:** Assessment of global thrombotic and fibrinolytic function in *whole blood* does not appear to exhibit diurnal variation in healthy volunteers. These measurements appear to be stable over time, making this a potentially suitable method for assessing the thrombotic/fibrinolytic status of an individual over time.

## Poster No. 017 Cardioembolic Stroke at Prosthetic valve endocarditis

Eneida Hoxha<sup>1†</sup>, Elvana Rista<sup>2</sup>, Somida Kuka<sup>1</sup>, Ledio Collaku<sup>1</sup>, Jona Musabelliu<sup>1</sup>, Jorida Djamandi<sup>2</sup>, and Margarita Gjata<sup>1</sup>

<sup>1</sup>University Hospital Center “Mother Theresa” Tirana, Albania

<sup>2</sup>Hygeia Hospital Tirana

† The presenting author.

**Background:** Embolic events are frequent and life-threatening complications of infective endocarditis (IE), related to the migration of cardiac vegetations. Risk of embolism is very high in IE, with embolic events occurring in 20–50% of patients. The brain and spleen are the most common sites of embolism in left-sided IE. Stroke is a severe complication and is associated with increased morbidity and mortality rates.

**Case presentation:** A 73-year-old male presented to the Emergency Department, in May 2022 with right hemiparesis, aphasia and fever (38° C). He reported of a two day history of recurrent fever. His pre-existing comorbidities included Diabetes Mellitus, Arterial Hypertension, and Atrial Fibrillation on anticoagulation therapy with Acenocoumarole and INR levels within normal range. His past medical history was significant for an Aortic Valve Replacement, in September 2021 and a subsequent hospitalization in January 2022 with Prosthetic Valve Endocarditis. At the time, he presented with recurrent fever up to 38.8°C, no significant findings in the transthoracic echocardiogram (TTE) and positive blood cultures for *Enterococcus faecalis*. He was started on antibiotic therapy.

Laboratory and imaging studies in his latest admission revealed a cardioembolic stroke.

**Conclusion:** Infective endocarditis can present with a wide variety of symptoms and early diagnosis can be challenging. Establishing the diagnosis early in the course of the disease, would enable a prompt implementation of empiric antibiotic therapy, potentially preventing serious complications. Keeping a high index of suspicion when evaluating patients at high risk for IE, might lead to more favorable outcomes of major complications associated with it.

## Poster No. 018 Association of Cytochrome P450 2C19 polymorphisms with ischemic and bleeding risk in patients with atrial fibrillation undergoing percutaneous coronary intervention

Diona Gjermeni<sup>1</sup>†, Sofia Szabo<sup>1</sup>, Viktoria Anfang<sup>1</sup>, Hannah Theresa Vetter<sup>1</sup>, Carina Juelch<sup>1</sup>, Dr. Stefan Leggewie<sup>1</sup>, Dr. David Hesselbarth<sup>1</sup>, Prof. Dr. Dietmar Trenk<sup>1</sup>, Prof. Dr. Daniel Duerschmied<sup>2</sup>, and PD Dr. Christoph B. Olivier<sup>1</sup>

<sup>1</sup>Department of Cardiology and Angiology, Heart Center Freiburg University, Faculty of Medicine, University of Freiburg, Freiburg, Germany

<sup>2</sup>Department of Cardiology, Angiology, Haemostaseology and Medical Intensive Care, University, Medical Center Mannheim, Medical Faculty Mannheim, Heidelberg University, Germany

† The presenting author.

**Introduction:** Patients with atrial fibrillation (AF) after percutaneous coronary intervention (PCI) receive clopidogrel and direct oral anticoagulation. Platelet inhibition by clopidogrel varies according to *CYP2C19* genotype. This study aimed to investigate the association of *CYP2C19* genotype with antiplatelet effect of clopidogrel and ischemic and bleeding risk.

**Methods:** In this prospective observational study, patients with AF after PCI were grouped according to *CYP2C19*\*2 and \*17 diplotypes: \*2/non-17\* or \*2/\*2 as reduced metabolizers (RM), non-\*2/\*17 or \*17/\*17 as increased metabolizers (IM), and the remaining as normal metabolizers (NM). Platelet aggregation [U] was quantified by multiple electrode aggregometry. The primary outcome was time to death, myocardial infarction, or stroke (MACE) at 6 months. The secondary outcome was time to non-major clinically relevant (NMCR) or major bleedings.

**Results:** 156 patients were enrolled between May 2020 and May 2021. The median age was 78 years (interquartile range, IQR 71–82) and 109 (70%) were male. 31 patients (20%) were RM, 74 patients (47%) NM and 51 patients (33%) IM. The median ADP-induced platelet aggregation was not significantly different across these groups (RM: 12.8 [U]; NM: vs. 12.8 [U]; IM: 11.7 [U];  $P=0.39$ ). The primary outcome occurred in 11 (7%) patients (RM: 1 [3%]; NM: 7 [9%]; IM 3[6%]). The secondary outcome occurred in 3 RM (10%) and in 20 (16%) with NM + IM subtypes (HR 0.65 [95% CI 0.19–2.18],  $P=0.485$ ).

**Conclusion:** In this analysis reduced metabolizers were not at excessively increased risk of MACE. A trend for less bleeding was observed in carriers of loss-of-function allele *CYP2C19*\*2.

## Poster No. 020 Increasing transvalvular gradient related to effectiveness of endogenous fibrinolysis in patients with severe aortic stenosis

Rahim Kanji<sup>1†</sup>, Vasileios F Panoulas<sup>2</sup>, Alison Duncan<sup>3</sup>, Simon W Davies<sup>3</sup>, Thomas F Luscher<sup>3</sup>, Saeed S Mirsadraee<sup>3</sup>, Deepa RJ Arachchillage<sup>3</sup>, and Diana A Gorog<sup>1</sup>

<sup>1</sup>National Heart and Lung Institute, Imperial College London

<sup>2</sup>Royal Brompton and Harefield NHS Foundation Trust

<sup>3</sup>Royal Brompton and Harefield NHS Foundation Trust

† The presenting author.

**Background:** Patients with severe aortic stenosis (AS) are at risk of both bleeding and thrombotic events. The high shear and flow rates across the stenotic aortic valve (AV) degrade von Willebrand factor high molecular weight multimers increasing bleeding risk, but can also lead to platelet activation. The overall effect on thrombotic and endogenous fibrinolytic status remains unclear. We aimed to assess the relationship between AS severity and thrombotic and fibrinolytic profile.

**Materials and methods:** In a prospective, observational study, thrombotic and thrombolytic status was assessed in venous blood taken from patients with severe AS using the Global Thrombosis Test. This point-of-care technique measures the time for occlusive thrombus formation under high shear (OT), and the time for spontaneous lysis of the thrombus (LT). We related these parameters to indices of AS severity.

**Results and conclusions:** Our cohort comprised of 86 patients (age  $79 \pm 9$  years, 58% male), of whom 25% were on single and 28% on dual antiplatelet medication, 47% on no antithrombotic therapy, and 1% on oral anticoagulation.

Lysis time was inversely related to AV peak ( $r = -0.242$ ,  $P = 0.04$ ) and mean ( $r = -0.286$ ,  $P = 0.012$ ) gradients. The severity of AS, by gradient or valve area, was not related to OT, although OT was inversely related to platelet count ( $r = -0.248$ ,  $P = 0.029$ ). Heterogeneity in antithrombotic medications may have masked a relationship between AS severity and OT.

We report that increasing severity of AS is related to more effective endogenous fibrinolysis, which may contribute to the increased propensity to bleeding.

## Poster No. 021 Correlation of Inflammation and Coagulation Serum Markers with The Incidence of Deep Vein Thrombosis in High-Risk Thrombosis Cancer Patients

Widi Budiarto<sup>1†</sup> and Budi Setiawan<sup>1</sup>

<sup>1</sup>Dr. Kariadi General Hospital, Semarang

† The presenting author.

**Background:** Deep vein thrombosis (DVT) is a frequent complication and the second leading cause of death in cancer patients. Cancer patients have numerous exposure to pro-inflammatory stimuli due to the mechanism of the tumor progression and chemotherapy effects. The objective is to evaluate the correlation between inflammatory cytokines and coagulation markers with the incidence of DVT in high-risk thrombosis cancer patients

**Material and methods:** This study was a cross-sectional study at Dr. Kariadi General Hospital. Serum proinflammatory cytokines (IL6, CRP, TNF- $\alpha$ ) and coagulation markers (TF, D-dimer) were evaluated in newly diagnosed high-risk thrombosis cancer patients (Khorana score  $\geq 2$ ). Screening of DVT were performed with color duplex sonography.

**Results and conclusions:** From January-November 2021, 83 subjects were eligible and 8 subjects (9.63%) had DVT. The median age was 49.5 y.o (min-max, 23–60) for DVT and 42 y.o (19–60) for non-DVT;  $P=0.046$  respectively. D-dimer serum was found higher in DVT subjects 6.020  $\mu\text{g/L}$  (2.090–20.000) vs. non-DVT 1.940  $\mu\text{g/L}$  (270–20.000);  $P=0.005$ . There were no significant differences in IL-6, CRP, TNF-alpha and TF serum in both groups. From multivariate analysis only age and D-dimer serum were significantly correlated with the incidence of DVT;  $p$  0.020, RR 1.593 (1.076–2.359) and  $P=0.028$ , RR 1.001 (1.000–1.001) respectively.

Age and serum D-dimer levels remain significant variables in the incidence of DVT in high-risk thrombotic cancer patients. Although there were no significant inflammatory changes between DVT and non-DVT subjects, further research is needed to understand the role of immune and inflammatory systems in the pathogenesis of VTE.



## Poster No. 022 Partial atresia of the inferior vena cava associated with deep vein thrombosis – case report

Stoia Oana<sup>1†</sup>, Cristina Zagoni<sup>1</sup>, Andreea Puia<sup>1</sup>, Bianca Catrina<sup>1</sup>, and Minodora Teodoru<sup>1</sup>

<sup>1</sup>The County Emergency Clinical Hospital

† The presenting author.

**Background:** Atresia of the inferior vena cava (IVC) is a congenital anomaly associated with partial or total absence and increases the risk of deep vein thrombosis (DVT) by up to 10 times due to venous stasis.<sup>1</sup> Although it occurs in 5% of cases of DVT without risk factors favoring<sup>2</sup>, a prevalence of 1% of general population is estimated.<sup>3</sup>

**Material and methods:** We present the case of a 30-year-old patient, smoker, professional truck driver, who addressed the ED for pain, edema and functional impotence in the lower left limb. One month ago, the patient suffered a trauma to the limb, with a closed tibial fracture that required a plaster cast and then orthosis. After two weeks, he has edema in his lower limb, reason why he started antithrombotic therapy (acenocoumarol). The paraclinical examinations performed revealed an overdose of oral anticoagulants with INR over the therapeutic limit, biological inflammatory syndrome, and vascular ultrasound revealed a deep venous thrombosis in the left ilio-femoral vessel. The investigations also revealed partial atresia of the IVC with collateral circulation and multiple supra- and infra-diaphragmatic shunts, and the iliac veins were drained by collaterals from the azygos / hemiazygos system.

**Results and conclusions:** Most patients with IVC atresia remain asymptomatic until the onset of a trigger factor (ex. immobilization of the lower limb) or until the third decade of life. The evolution of symptoms under treatment with parenteral anticoagulants (fondaparinux 7.5 mg) and then oral (apixaban 2x5 mg) was favorable with significant remission of edema.

## Poster No. 023 Indian Consensus for the Utilisation of Combination of Dual Antiplatelet (DAPT) and Statin therapy for the Stratified Treatment of Acute Coronary Syndrome (ACS)

Jay Shah<sup>1†</sup>, Prashant Kharche<sup>2</sup>, Ajeya Mundhekar<sup>3</sup>, Pradeep R Kumar<sup>4</sup>, Soumik Chaudhuri<sup>5</sup>, Joy Sanyal<sup>6</sup>, Sukriti Bhalla Singh<sup>7</sup>, Omer Mustafa Hasan<sup>8</sup>, Saikat Kanjilal<sup>9</sup>, Ameya Mt<sup>10</sup>, MD Sadiq Azam<sup>11</sup>, VSR Bhupal<sup>12</sup>, and STRATIFY Consensus Group<sup>13</sup>

<sup>1</sup>Krish Heart Centre, Ahmedabad, India

<sup>2</sup>Koshaleya Hospital, Mumbai

<sup>3</sup>Healthway Hospital, Goa

<sup>4</sup>JP Hospital, Rourkela

<sup>5</sup>Peerless Hospital, Kolkata

<sup>6</sup>Nivedita Health Care Center, Siliguri

<sup>7</sup>Aakash Hospital, Delhi

<sup>8</sup>Allahabad Heart Center, Prayagraj

<sup>9</sup>Manipal Hospital, Kolkata

<sup>10</sup>Tirur Nursing Home, Tirur, Kerala

<sup>11</sup>KIMS Hospital, Hyderabad

<sup>12</sup>Capital Hospitals, Vijaywada

<sup>13</sup>National

† The presenting author.

**Objective:** To formulate a consensus statement for utilisation combination of DAPT and statin combination based on evidence and real-world experiences.

**Methods:** A virtual collaborative educational initiative was convened in June 2022 through a series of nationwide ( $n = 16$ ) meetings with 275 cardiologists (cumulative experience of 2,200-man years) at forefront of ACS management, who rated their level of agreement for 10 questions (6 Likert scale, 4 objective choice). This was preceded by evidence-based discussion of combination of DAPT and statin. Consensus was predefined as  $> 60\%$  agreeing/disagreeing on any given item.

**Results:** Highest agreement was for the concurrence for clinical relevance of concept of stratified treatment of ACS (95.4%). Agreement score (%) for that DAPT- statin combination is underutilised was 83.8%, followed by the need for optimal management of ACS (75.5%), relevance of BATTLE AMI hypothesis (74.6%), clopidogrel preferred for de-escalated DAPT approach (72.1%), De-escalation therapy is part of optimisation approach (61.8%) ( $P < 0.0001$ ). Participants opined that: ischemic risk is the most important factor to choose DAPT (67.6%), other ongoing therapy is an important determinant of DAPT adherence (59.5%), patients with high CV risk are the best suited for prolonged DAPT therapy (46.5%), DAPT should be continued for atleast 1 year (50%).

**Conclusions:** There was a high preference for combination of DAPT and statin for stratified treatment of ACS, associated with a high level of perceived effectiveness based on the recent clinical trials. Combination of DAPT and high potent statin, like rosuvastatin is distinctive in the therapeutic armamentarium for optimal management of ACS.

## Poster No. 025 Survival in octogenarians receiving implantable cardiac defibrillators: a single centre experience

Nitish Behary Paray<sup>1</sup>†, Nikolaos Spinthakis<sup>1</sup>, Mohammad Saddam Jeelani<sup>1</sup>, and Jebby Kuriakose<sup>1</sup>

<sup>1</sup>Royal Devon University Healthcare NHS Foundation Trust

† The presenting author.

Although the efficacy of implantable cardiac defibrillator (ICD) in preventing sudden cardiac death is well established in studies, patients  $\geq 80$  years are poorly represented, causing a paucity of data on outcomes in this subgroup.

In our single-centre retrospective study, data pertaining to patients  $\geq 80$  years of age at device implant ( $n = 95$ ) between January 2010 and January 2022 was extracted from device databases and clinical notes. Categorical variables were compared using Fisher's exact test. A Kaplan-Meier survival analysis with logrank test was performed. A Multivariable Cox Hazard regression model was used to analyse survival adjusting for QRS duration, left ventricular ejection fraction and device type.

Mean age of the cohort was  $83.1 \pm 3$  years, with 85% ( $n = 81$ ) being male. 73% ( $n = 69$ ) of the population had ischaemic cardiomyopathy and 43% ( $n = 41$ ) met the primary prevention indications. Median survival time post device implantation was 27 months. Survival at 5 years was 80%. The difference in survival rates between primary and secondary prevention groups was not statistically significant. Inappropriate shocks were delivered in 2 patients while 14 patients were successfully treated with appropriate therapy. Complications were encountered in 9% ( $n = 9$ ) of cases, with a fatal outcome on one occasion.

ICD therapy is a well-tolerated intervention and may confer survival benefits in elderly patients, provided careful selection criteria are implemented. Advanced chronological age alone should not unduly influence the decision for ICD selection for survival benefit. There is an imperative for greater representation of this cohort in future trials.

## Poster No. 026 Prognostic value of cardiac biomarkers in acute pulmonary embolism: can it add something?

Fabiana Duarte<sup>1</sup>†, M. Inês Barradas<sup>1</sup>, Luís Oliveira<sup>1</sup>, Inês Coutinho Dos Santos<sup>1</sup>, Carina Machado<sup>1</sup>, Raquel Dourado<sup>1</sup>, Anabela Tavares<sup>1</sup>, and Dinis Martins<sup>1</sup>

<sup>1</sup>Hospital Divino Espirito Santo | Ponta Delgada

† The presenting author.

**Background:** Acute pulmonary thromboembolism (PE) is a life-threatening disease. Cardiac biomarkers like lactate, NT-proBNP and troponin I have been reported to predict prognosis of acute PE however, the prognostic importance of these factors on long-term mortality is not known.

**Objectives:** To assess the prognostic role of biomarkers lactate, NT-proBNP and troponin I in acute PE.

**Methods:** We retrospectively assessed 131 consecutive patients diagnosed with acute PE. Prognostic impact of both lactate, NT-proBNP and troponin was assessed.

**Results:** Out of 131 patients with acute PE, the median age was  $67.6 \pm 15.3$  years and 71.0% were female. Mean follow-up was  $44.8 \pm 37.3$  months. Overall in-hospital mortality was 8.4%, 30-day mortality 13.0% and 1-year mortality 20.6%.

Twenty-six patients (19.8%) had a recent hospitalization and 21 (16.0%) a medical history of active cancer.

ROC curves shown that lactate has a good discriminatory power for in-hospital mortality, with an area under the curve (AUC) of 0.84 and p-value 0.001, unlike NT-proBNP (AUC 0.45, p-value 0.76) and troponin (AUC 0.64, p-value 0.12). Serum lactate equal or superior to 2.05 mmol/L were associated with higher in-hospital mortality (odds ratio [OR] 23.1, 95% confidence interval (CI) 2.8–187.7), when compared with lower levels. The impact of this parameter was independent of hypotension, tachycardia or active neoplasia (p-value 0.006, OR 21.3, 95% CI 2.4–187.3).

**Conclusions:** This study revealed that lactate has a better discriminatory power when compared to NT-proBNP and troponin in predicting prognosis in acute PE patients. Its routinely addition to current stratification tools could be of interest.

## Poster No. 027 Clinical, echocardiographic, analytic and anatomical parameters: which are the main prognostic factors in hospitalized patients with acute pulmonary embolism?

Fabiana Duarte<sup>1†</sup>, M. Inês Barradas<sup>1</sup>, Luís Oliveira<sup>1</sup>, Inês Coutinho Dos Santos<sup>1</sup>, Carina Machado<sup>1</sup>, Raquel Dourado<sup>1</sup>, and Dinis Martins<sup>1</sup>

<sup>1</sup>Hospital Divino Espirito Santo | Ponta Delgada

† The presenting author.

**Background:** Acute pulmonary embolism (PE) is a life-threatening disease and an early diagnosis and therapy are crucial. Several parameters for risk stratification have been evaluated and it's important to assess their impact on clinical practice.

**Objective:** We assessed four different parameters (clinical, echocardiographic, analytical and anatomical imaging parameters) - PESI class; PESI-Echo score; lactate and troponin I values and central or peripheral thrombi location. We determined a composite outcome of adverse events: shock, acute ventilatory failure, severe bleeding events or in-hospital mortality.

**Methods:** Retrospective single center analysis including 131 patients admitted for PE.

**Results:** Mean age of  $67.6 \pm 15.3$  years-old and 71% patients were female. Eighty patients (63.4%) had arterial hypertension, 27.4% had a recent hospitalization or surgery and 16% an active neoplasm disease. According to the PESI classification, 29.8% of the patients were in class V, 26.7% in class III and 17.6% in class II. This classification had a weak positive correlation with the outcome ( $P < 0.001$ ;  $r = 0.37$ ) as PESI-Echo score ( $p = 0.018$ ;  $r = 0.36$ ). The majority (72.2%) of the in-hospital adverse events occurred in PESI class V patients. Analytic parameters determined at hospital admission had a good discriminative power to predict the outcome, mainly lactate value (AUC 0.864;  $P < 0.001$ ). PESI-Echo score presented the best discriminative power (AUC 1.0), followed by PESI class (AUC 0.925) and lactate (AUC 0.856). The cut-off value for PESI-Echo was 211.

**Conclusion:** The association of clinical and echocardiographic parameters was superior as a predictor of adverse events when compared with their isolated use.

## Poster No. 028 Sex differences in cardiac operations: Are we being fair to our female patients?

Catherine A Fitton<sup>1</sup>† and Jill JF Belch<sup>1</sup>

<sup>1</sup>University of Dundee

† The presenting author.

**Introduction:** Research suggests that whilst men have a higher cardiovascular disease (CVD) rate, women are more likely to suffer a poor prognosis following CVD, possibly due to incorrect diagnosis and treatments. A question infrequently asked is whether this inequality is due to sex bias when selecting patients for operation.

**Methods:** Patients who had been admitted to hospital with a cardiovascular diagnosis within the Scottish Heart Health Extended Cohort (SHHEC) were studied. Participants were recruited between 1984–1995 and followed up until 2017 via data linkage to NHS hospital records. Using propensity score nearest neighbour matching, admissions for women were matched with men within the cohort on a 1:1 basis. Admissions were matched for common CVD risk factors and generalised logistic mixed models were used to estimate Odds Ratios (OR) and 95% Confidence Intervals (95% CI).

**Results and conclusions:** A total of 25,318 admissions to hospital for cardiac reasons were recorded over the study period (20,520 following matching). Women were less likely to have a cardiac procedure (4.57% males, 2.77% females; OR 0.59; 95% CI 0.50–0.70). Women were significantly less likely to have a cardiac operation (2.65% males, 1.47% females; OR 0.55; 95% CI 0.45–0.67), but not endovascular procedures (1.89% males, 1.30% females; OR 0.66; 95% CI 0.37–1.16) following hospital admission. Within the SHHEC cohort, a matched cohort of 20,520 admissions to hospital over a 30-year period, demonstrated that women were less likely to undergo surgical procedures, even when matched with men on common CVD risk factors.

## Poster No. 030 Young patient with hyperhomocysteinemia and multiple atherosclerotic vascular lesions

Stoia Oana<sup>1†</sup>, Catrina Bianca<sup>1</sup>, Puia Andreea<sup>1</sup>, and Bitea Ioan Cornel<sup>1</sup>

<sup>1</sup>The County Emergency Clinical Hospital

† The presenting author.

**Background:** Hyperhomocysteinemia is usually defined as an elevation of plasma tHcy > 15 μmol/L with a prevalence ranging around 5–10% in the adult general population. In the last years, studies have demonstrated that moderate hyperhomocysteinemia is a frequent and independent risk factor for premature vascular disease in the coronary, cerebral, and peripheral arteries by impairing endothelium-dependent vasomotor responses in a way that increases risk for complications of atherosclerosis.

**Material and methods:** We present the case of a 45 years old man, without significant pathological history, who has a marked weight loss and diffuse abdominal pain. The patient is investigated, and following a CT scan of the abdomen, the diagnosis of mesenteric ischemia was made with severe stenosis of the superior mesenteric artery and celiac trunk in the proximal segments. Two drug-active stents were implanted at the level of both the celiac trunk and the superior mesenteric artery. Following the investigations, coronary heart disease is established by monovascular damage and significant carotid atheromatosis.

After one year the abdominal pain returns, and the control angiography reveals severe intrastent restenosis in the superior mesenteric artery and occlusive restenosis and fracture of the stent implanted in the celiac trunk (modifications in context of cessation of treatment and abdominal traumatism). More detailed investigation revealed moderate hyperhomocysteinemia. After successful treatment he returns one year later with the same symptoms and occlusions of mesenteric artery.

**Conclusion:** In young patients presenting with multiple vascular damage hyperhomocysteinemia must be thought as it is an independent cardiovascular risk factor.

## Poster No. 031 Anti-inflammatory potential of cannabinoid extracts

Martin Maly<sup>1†</sup>, Jitka Viktorová<sup>2</sup>, Tomáš Ruml<sup>2</sup>, and Milena Stránská<sup>2</sup>

<sup>1</sup>Institute for Clinical and Experimental Medicine

<sup>2</sup>University of Chemistry and Technology Prague

† The presenting author.

Inflammation plays a substantial role in the process of atherosclerosis. The key players are monocytes transformed to macrophages. Limited experience with anti-inflammatory drugs is described – antibodies for IL-1 (CANTOS) and colchicine (COLCOT, LoDoCo-2 trial). Cannabis extracts are known to have profound anti-inflammatory effect in diseases associated with chronic inflammation, e.g. rheumatoid arthritis. Human monocytic cell line THP-1 was differentiated into macrophages by incubation in the presence of phorbol-12-myristate-13-acetate, which leads to a macrophage-like phenotype characterized by changes in morphology and adhesion. Macrophages were polarized toward M1 pro-inflammatory phenotype responsible for production of several cytokines, esp.  $\text{TNF}\alpha$  and IL-6. The ability of cannabinoids to decrease production of pro-inflammatory cytokines in polarized macrophages was measured by ELISA. The viability of macrophages after the treatment was verified by resazurin assay. Cannabigerol (CBG) and cannabidiol (CBD) significantly decreased the production of  $\text{TNF}\alpha$  in dose-dependent manner. 7.5 mg/L of CBG and 1 mg/L of CBD decreased the production of  $\text{TNF}\alpha$  by 32 and 34%, respectively. CBD, cannabidivarin (CBDV), cannabichromene (CBC), and cannabinol (CBN) significantly decreased also IL-6 production. 7.5 mg/L of CBDV and CBC decreased the production of IL-6 by 38 and 62%, respectively. 2 mg/L of CBD and CBN decreased the production of IL-6 by 33% (both). The concentration of the most potent cannabinoid (CBC) inhibiting IL-6 production by half (IC<sub>50</sub>) was determined to be  $6.7 \pm 0.1$  mg/L, which is two-times better treatment potential than colchicine ( $13.4 \pm 0.8$  mg/L). Cannabinoids might be promising substance in the treatment of subclinical inflammation associated with atherosclerosis.

The project was funded by the Grant No 22–20860S of The Czech Science Foundation.



## Poster No. 040 Traversing boundaries inside the heart

Inês Pereira Oliveira<sup>1</sup>, Isabel Cruz<sup>1</sup>†, Rafaela Lopes<sup>1</sup>, Bruno Bragança<sup>1</sup>, Inês Campos<sup>1</sup>, João Azevedo<sup>1</sup>, and Aurora Andrade<sup>1</sup>

<sup>1</sup>Centro Hospitalar Tâmega E Sousa E.P.E.

† The presenting author.

An 84-year-old man with previous pulmonary embolism (PE) was admitted to hospital for acute dyspnea. He was normotensive, but tachypneic and tachycardic. Non-relevant findings on auscultation. ECG showed sinus tachycardia and blood tests depicted elevated D-dimers and troponin I. Angio-CT diagnosed a PE. Echocardiogram (echo) showed an enlarged right ventricle with depressed function, a flattened septum with paradoxical movement, preserved left ventricular function, no intracavitary masses. Enoxaparin was started. Days later he developed new left sided hemiparesis. Acute ischemic cerebral lesion on CT scan. Echo disclosed a new hyperechogenic highly mobile mass attached to the interatrial septum moving from the right to the left atrium, suggestive of thrombus. Anticoagulation was maintained and on new echo evaluation days later there were no intracardiac masses. Agitated saline echo testing disclosed the presence of a patent foramen ovale, supporting the previous notion that a thrombus was moving between interatrial chambers. Oncological screening and prothrombotic evaluation were not completed due to unfavorable clinical evolution.

Paradoxical embolism (PaE) is usually a presumptive diagnosis. It is rarely found in clinical practice, though its prevalence may be underestimated due to the transient nature of the phenomenon and the difficulty in identifying a venous thrombus-in-transit through a cardiac defect and subsequent arterial embolism. The presence of a thrombus-in-transit modifies the treatment strategy, requiring urgent management due to the impending risk of PaE, with treatment options comprising anticoagulation, thrombolysis and thrombectomy. Although no consensus exists regarding optimal strategy, surgical embolectomy is the favored approach in most published cases.

## **Poster No. 043 A Case of Post Thrombotic Syndrome and AV Fistula arising from Recurrent DVT Secondary to May – Thurner Syndrome (MTS) in an Elderly Woman**

Angeline UY Lim<sup>1†</sup>, Marilou de Jesus<sup>2</sup>, Fabio Enrique Posas<sup>1</sup>, and Marvin Martinez<sup>1</sup>

<sup>1</sup>St. Luke's Medical Center - Global City

<sup>2</sup>St. Luke's Medical Center- Global City

† The presenting author.

May-Thurner Syndrome (MTS) remains to be an overlooked condition wherein the right common iliac artery compresses the left common iliac vein. Rarely reported, MTS has other different variants with the iliac vein being compressed by an ipsilateral artery. Iliofemoral DVT poses a significant impact because of venous claudication and DVT recurrence. MTS usually occurs in women, ages 20–40 y/o, and is thus rarely included in differential diagnosis of DVT in elderly patients presenting with persistent unilateral leg swelling. Treatment of DVT alone with anticoagulation is insufficient to address thrombotic MTS. Failure to address the mechanical compression leads to poor quality of life due to high predisposition to recurrent DVT, and at times to other complications such as post-thrombotic syndrome and formation of AV fistulas.

We present a case of an 89 year old woman, hypertensive, non-smoker, no history of cancer, presenting with progressive left lower extremity swelling with erythema, violaceous discoloration, varicosities, telangiectatic skin lesions, hyperpigmentation and calf tenderness. Ultrasound revealed DVT at common iliac vein extending to the popliteal veins. CT studies showed a left common iliac artery compressing the left common iliac vein with early enhancement of the common femoral vein, indicating presence of fistula. Peripheral angiography and venography findings were consistent with CT scan findings, with incidental findings of multiple small AV fistulas.

Anti-coagulation was given and IVC filter was inserted. An attempt to do catheter-directed thrombolysis was unsuccessful. Subsequently, she underwent Palma's surgery which provided significant improvement and was sent home ambulatory.

## Poster No. 044 Cardiovascular risk factors and coronary heart disease in the young – a single centre analysis

Carolina Miguel Gonçalves<sup>1</sup>†, Margarida Cabral<sup>1</sup>, Mariana Carvalho<sup>1</sup>, Adriana Vazão<sup>1</sup>, Sara Fernandes<sup>1</sup>, Rita Carvalho<sup>1</sup>, Fátima Saraiva<sup>1</sup>, and João Morais<sup>1</sup>

<sup>1</sup>Hospital de Leiria

† The presenting author.

**Background:** Cardiovascular events in the young appear to be increasing. Conversely, this is not the tendency reported in older adults. Identifying risk factors is of the uttermost importance to improve cardiovascular prevention.

**Material and methods:** Retrospective, single-centre analysis of patients with less than 45 years and suspected coronary heart disease who were subjected to cardiac catheterization in our centre during a 5-year period.

**Results and conclusions:** A total of 171 patients were included with a median age of  $42 \pm 6$  years of which 82% were male. Overweight (73%), smoking (61%) and dyslipidemia (42%) were the most prevalent cardiovascular risk factors. Coronary heart disease was diagnosed in 67% of patients. After univariate analysis, gender ( $P=0.049$ ), age ( $P=0.005$ ), smoking ( $P=0.032$ ), low-density lipoprotein cholesterol ( $P=0.005$ ) and total cholesterol ( $P=0.003$ ) were significantly associated with disease in coronary angiography. After multivariate logistic regression, only age (OR = 1.123; CI 95% [1.036–1.217];  $P < 0.005$ ) and low-density lipoprotein cholesterol (OR = 1.016; CI 95% [1.004–1.028];  $P = 0.009$ ) remained as independent factors of coronary heart disease.

It is known that awareness regarding a healthy lifestyle should be raised in the general population. As several modifiable risk factors have an impact on cardiovascular disease, there is an urgent need to improve primary prevention. Conversely, a more thorough investigation is needed in the cases where no significant coronary disease is found.

According to our analysis, age and low-density lipoprotein cholesterol appear to have a stronger relevance in this young population.

## Poster No. 045 The role of 24-h Holter monitoring in thrombosis – a single-centre subanalysis in the young

Carolina Miguel Gonçalves<sup>1†</sup>, Adriana Vazão<sup>1</sup>, Mariana Carvalho<sup>1</sup>, Sara Fernandes<sup>1</sup>, Margarida Cabral<sup>1</sup>, Rita Carvalho<sup>1</sup>, Hélia Martins<sup>1</sup>, Fátima Saraiva<sup>1</sup>, and João Morais<sup>1</sup>

<sup>1</sup>Hospital de Leiria

† The presenting author.

**Background:** Undercovering the etiology responsible for pathologic states is of the uttermost importance, especially regarding young people. Arterial and venous thromboembolism may have an impact on morbidity and mortality, enhancing the need to prevent recurrences.

**Material and methods:** Retrospective, single-centre analysis of 24-h Holter monitoring in patients with thrombotic events and less than 40 years during a 5-year period, using IBM® SPSS® software to perform descriptive analysis.

**Results and conclusions:** Thrombosis was the reason for requesting 24-h Holter monitoring in 7% ( $n = 41$ ) from a total of 581 exams screened – 68.3% had a stroke, 6% a transient ischemic stroke, 4.9% a pulmonary embolism, 4.9% an intestinal ischemia and 2.4% had both pulmonary embolism and deep vein thrombosis. Patients had a median age of  $35 \pm 6$  years, 63.7% were male and past medical history consisted of cardiovascular risk factors, particularly smoking (36.6%), high blood pressure (19.5%) and dyslipidemia (12.2%).

Merely 4.9% had a diagnostic finding – atrial flutter and second-degree atrioventricular block Mobitz II. On the other hand, autoimmune tests were altered in 12.2% and echocardiogram revealed patent foramen ovale, atrial septum aneurysm and interatrial septum bulging with shunt in 9.8%, 2.4% and 2.4%, respectively. Regarding management, 78% were medicated with aspirin or anticoagulant and 4.9% were submitted to percutaneous closure of patent foramen ovale.

Despite low prevalence of diagnostic findings, Holter monitoring is an important complementary exam that can have therapeutic implications in these cases and, consequently, in preventing new events.

## Poster No. 047 A comparative study of high-intensity statin therapy in post-acute coronary syndrome patients undergoing a cardiac rehabilitation program

Margarida Cabral<sup>1†</sup>, Mariana Carvalho<sup>1</sup>, Rita Santos<sup>2</sup>, José Bernardo Ferreira<sup>2</sup>, Catarina Ruivo<sup>1</sup>, Filipa Januário<sup>2</sup>, Alexandre Antunes<sup>1</sup>, and João Morais<sup>1</sup>

<sup>1</sup>Cardiologia - CHLP - Hospital Santo André EPE - Leiria

<sup>2</sup>Centro Hospitalar De Leiria, E.P.E.

† The presenting author.

Aggressive lipid lowering has been shown to be a crucial part of secondary prevention after acute coronary syndrome (ACS). The selection of the best lipid-lowering agents is controversial, with some trials showing rosuvastatin as more efficacious in improving lipid profile compared to atorvastatin, others showing no difference. Another concern is the impact of statin therapy on the reduction of muscle oxidative capacity, and, consequently, on functional capacity.

This study aimed to analyse the differences in lipid profile and physical capacity in post-ACS patients undergoing a cardiac rehabilitation program (CPR), medicated with rosuvastatin versus atorvastatin.

A retrospective analysis of patients in phase 2 of CRP between 2017 and 2020 was performed. Two groups were created: group 1 for patients under atorvastatin 40 mg and group 2 under rosuvastatin 20 mg. Variables were analysed at the beginning and the end of phase 2, 12 weeks later. A *P-value* < 0.05 is statistically significant.

A total of 98 patients completed phase 2 of CRP, of which 14 are part of group 1, 67 of group 2, and 17 users of other lipid-lowering drugs. Table 1 shows the main characteristics. Univariate (table 2) and multivariate analyses show no differences regarding lipid profile or functional activity between groups.

In conclusion, in this group of patients, high-intensity rosuvastatin and atorvastatin in secondary prevention post-ACS had a comparable impact on lipidic profile, without a significant difference in functional activity, independently of age, sex or comorbidities. Larger randomized prospective trials, including phase 3 of CRP, are needed to confirm these results.

## Poster No. 049 Cardiopreventive influence of Klotho protein on antioxidant and anti-apoptotic mechanisms in heart injured by ischemia/reperfusion

Agnieszka Olejnik<sup>1</sup>†, Marta Banaszkiwicz<sup>1</sup>, Anna Radajewska<sup>1</sup>, and Iwona Bil-Lula<sup>1</sup>

<sup>1</sup>Department of Medical Laboratory Diagnostics, Division of Clinical Chemistry and Laboratory Haematology, Faculty of Pharmacy, Wrocław Medical University, Wrocław

† The presenting author.

**Background:** Ischemia/reperfusion injury (IRI) of heart involves activation of oxidative and apoptotic pathways. Klotho protein has potential protective activity since it supports redox balance and metabolic functions of cardiomyocytes. This study aimed to evaluate effect of Klotho protein on oxidative stress and apoptosis in hearts subjected to IRI.

**Material and methods:** Isolated rat hearts perfused with the Langendorff method were subjected to ischemia, followed by reperfusion, in presence or absence of Klotho protein. Heart mechanical function and factors involved in the activation of insulin-like growth factor 1 receptor (IGFR-1)/phosphoinositide 3-kinase (PI3K) signaling pathway were evaluated.

**Results:** Infusion supply of Klotho significantly increased ( $P=0.001$ ) mechanical function of hearts injured by IRI. IRI caused activation of IGFR-1/PI3K signalling pathway ( $P=0.004$ ;  $P=0.003$ ), while Klotho suppressed phosphorylation of IGFR-1 ( $P=0.208$ ) and PI3K ( $P=0.022$ ). Transcriptional activity of forkhead box protein O1 (FOXO1) and FOXO3 was reduced ( $P=0.002$ ;  $P<0.001$ ) in IRI hearts. Administration of Klotho decreased phosphorylation of FOXO1 ( $P=0.587$ ) and FOXO3 ( $P=0.027$ ) in IRI + Klotho group, while activity of glutathione peroxidase and superoxide dismutase was increased ( $P=0.045$ ;  $P=0.006$ ), and level of hydrogen peroxide and lipid peroxidation was slightly decreased ( $P=0.502$ ;  $P=0.436$ ), as compared to IRI hearts. Klotho protein contributed to reduction in caspase-9 level ( $P=0.009$ ) during IRI.

**Conclusion:** Administration of Klotho resulted in full preservation of heart mechanical function, and suppression of oxidative stress and apoptosis in IRI hearts. Thus, Klotho can be recognized as a novel cardiopreventive agent in ischemic damage.

**Funding:** Ministry of Science and Higher Education in Poland [grant number SUBK.D010.22.035].

## Poster No. 050 Klotho protein supports mechanical function and prevents MMP-mediated injury of heart during ischemia/reperfusion

Agnieszka Olejnik<sup>1</sup>†, Anna Krzywonos-Zawadzka<sup>1</sup>, Marta Banaszkiwicz<sup>1</sup>, and Iwona Bil-Lula<sup>1</sup>

<sup>1</sup>Department of Medical Laboratory Diagnostics, Division of Clinical Chemistry and Laboratory Haematology, Faculty of Pharmacy, Wrocław Medical University, Wrocław

† The presenting author.

**Background:** The injury of the myocardium during ischemia/reperfusion (IRI) involves metabolic, morphological, and contractile disorders. Klotho is a membrane or soluble anti-aging protein. Recent studies have proven the correlation between Klotho deficiency and the occurrence and development of cardiovascular diseases. The study aimed to evaluate the effect of Klotho protein on hearts subjected to IRI.

**Material and methods:** Isolated Wistar rat hearts perfused with the Langendorff method were subjected to ischemia, followed by reperfusion, in the presence or absence of Klotho protein. Hemodynamic parameters and the levels of nuclear factor kappa-light-chain-enhancer of activated B cells (NF- $\kappa$ B), nitrate/nitrite, inducible nitric oxide synthase (iNOS), asymmetric dimethylarginine (ADMA), matrix metalloproteinase 2 (MMP-2), MMP-9 and tissue inhibitor of MMP type 4 (TIMP-4) were evaluated.

**Results:** Infusion supply of Klotho during IRI resulted in the recovery of contractile function ( $P=0.031$ ) and heart rate ( $P=0.02$ ). IRI activated MMP-2 ( $P=0.042$ ) and MMP-9 ( $P=0.041$ ) in hearts, as compared to aerobic control. Klotho contributed to increase in iNOS level ( $P=0.02$ ), and decreased levels of NF- $\kappa$ B ( $P=0.006$ ), ADMA ( $P=0.007$ ), nitrate/nitrite ( $P=0.022$ ), MMP-2 ( $P=0.024$ ) and MMP-9 ( $P<0.001$ ), as compared to IRI group.

**Conclusions:** Klotho protein preserved heart mechanical function and reduced the level of proteolytic enzymes in the heart. Thus, Klotho can be recognized as a novel cardiopreventive/cardioprotective agent in ischemic damage.

This work was supported by the National Science Centre, Poland [grant number 2019/33/N/NZ3/01649].

## Poster No. 051 Is primary prevention with ASA a protective factor in acute coronary syndromes?

Marta Paralta de Figueiredo<sup>1</sup>†, Bruno Piçarra<sup>1</sup>, João Pais<sup>1</sup>, and Ana Rita Santos<sup>1</sup>

<sup>1</sup>Hospital do Espírito Santo de Évora

† The presenting author.

**Background:** This study aims to characterize the influence of primary prevention with ASA in the presentation of acute coronary syndromes (ACS) and morbimortality.

**Methods:** Out of a population of 745 patients admitted with an ACS (D), we selected those without previous ACS or angioplasty (N = 488) and divided them in groups: with primary prevention with ASA (D1) and without (D2). Age, sex, personal history, clinical and ECG presentation, LVEF, coronary angiography and angioplasty were documented. These complications were defined: heart failure, cardiogenic shock, reinfarction, mechanical complications, stroke, major haemorrhage and need for blood transfusion. Intra-hospital mortality was compared between groups.

**Results:** D1 consisted of 16.3% of the population. They were older ( $70,9 \pm 12,3$  years vs.  $65,6 \pm 14,3$ ,  $P = 0,002$ ), had a higher prevalence of hypertension (90,0% vs. 65,6%;  $P < 0,001$ ), diabetes (45,2% vs. 26,9%,  $P = 0,008$ ), dyslipidemia (67,5% vs. 45,8%,  $P = 0,001$ ), chronic kidney disease (16,3% vs. 8,0%;  $P = 0,03$ ) and stroke (12,5% vs. 5,3%,  $P = 0,03$ ), but lower prevalence of smoking (20,0% vs. 33,8%,  $P = 0,02$ ) when compared to D2. They presented less frequently with STEMI (26,3% vs. 50,8%,  $P = 0,001$ ), but more with unstable angina (13,8% vs. 4,4%,  $P = 0,003$ ) and NSTEMI (17,5% vs. 4,6%,  $P = 0,001$ ). The number of coronary angiograms and angioplasties and the access site were similar. D1 revealed higher incidence of heart failure (20,0% vs. 7,5%,  $P = 0,001$ ) and non-invasive ventilation (6,3% vs. 0,8%,  $P = 0,002$ ), but no differences in LVEF, other complications or mortality.

**Conclusions:** Primary prevention with ASA seems to condition clinical and electrocardiographical presentation and relate to the development of heart failure.



## Poster No. 052 The Influence of the CYP2C9 polymorphisms on the treatment with clopidogrel: combined data from the POPular Genetics & POPular AGE trials

Drs. W. W.A. Van Den Broek<sup>1</sup>†, Drs. N. Mani<sup>1</sup>, Drs. J. Azzahafi<sup>1</sup>, and Prof. Dr. J. Ten Berg<sup>1</sup>

<sup>1</sup>St. Antonius Hospital, Nieuwegein, Netherlands

† The presenting author.

**Background:** The CYP2C9-enzym plays a role in the metabolization of clopidogrel. In patients treated with clopidogrel, carriage of a CYP2C9 loss-of-function (LoF) allele has been associated with attenuated pharmacokinetics leading to a diminished pharmacodynamic response and increased risk for stent thrombosis.

**Material and methods:** We aimed to determine the effect of the CYP2C9\*2 and \*3 LoF-alleles on thrombotic events and clopidogrel treatment discontinuation. A post-hoc analysis was performed in patients with available CYP2C9 genotype status included in the POPular Genetics and POPular Age trials, which enrolled patients with ST-elevation myocardial infarction and non-ST-elevation myocardial infarction, respectively. The primary thrombotic outcome was a composite of cardiovascular death, myocardial infarction or stroke.

**Results:** The CYP2C9 genotype was available in 2,257 patients, of which 878 were treated with clopidogrel (352 [40%] CYP2C9 LoF-allele carriers and 526 [60%] CYP2C9 LoF-allele noncarriers). There were no significant differences between CYP2C9 LoF-allele carriers and noncarriers for the combined thrombotic outcome (6.3% vs. 5.9%, HR 1.17 [0.67–2.03],  $P=0.58$ ), and the individual thrombotic outcomes. No differences were seen in clinically relevant bleeding (Bleeding Academic Research Consortium [BARC] 2–5 bleeding) as well as major bleeding (BARC 3 or 5 bleeding). Discontinuation rates for clopidogrel due to side-effects were numerically lower in CYP2C9 LoF carriers compared noncarriers (1.4% vs. 3.2%, HR 0.54 [0.26–1.13],  $P=0.10$ ), however this difference was not statistically significant.

**Conclusions:** Carriage of the CYP2C9 \*2 or \*3 LoF-alleles did not show an association with an increased thrombotic risk in patients treated with clopidogrel.

**Funding:** ZonMW.

## Poster No. 054 Genetic variation in the TCF21 gene is associated with the severity of coronary artery disease

Débora Sá<sup>1†</sup>, MI. Mendonça<sup>1</sup>, M. Santos<sup>1</sup>, M. Temtem<sup>1</sup>, AC. Sousa<sup>1</sup>, M. Rodrigues<sup>1</sup>, E. Henriques<sup>1</sup>, S. Freitas<sup>1</sup>, S. Borges<sup>1</sup>, G. Guerra<sup>1</sup>, AI. Freitas<sup>1</sup>, I. Ornelas<sup>1</sup>, A. Drumond<sup>1</sup>, and R. Palma Dos Reis<sup>2</sup>

<sup>1</sup>Hospital Dr. Nélio Mendonça

<sup>2</sup>New University of Lisbon, Faculty of Medical Sciences

† The presenting author.

**Introduction:** In vitro studies demonstrated that targeted deletion of the transcription factor encoding gene TCF21, was associated with vascular smooth muscle cell disruption. Recent research showed that TCF21 expression contribute to fibrous cap formation, preventing heart attacks.

**Purpose:** Analyse the TCF21 rs12190287 gene and evaluate its association with atherosclerosis severity measured according to the coronary angiogram patients' data. **Methods:** Prospective study with 1,639 coronary artery disease (CAD) patients (mean age  $53.4 \pm 7.8$  years). Two age groups (< 55 and > 55 years) were stratified and analyzed. TCF21 rs12190287 G > C was genotyped in all patients. The severity of CAD was graded according to the number of obstructed coronary arteries with at least 70% narrowed lumen. Chi-squared tests and multivariate logistic regression models were analysed.

**Results:** The CC genotype was associated with > 70% obstructive lesions (vascular disease rate, 48.1%). Contrariwise, the GG wild genotype was associated with less severe obstructive disease (19.5%) ( $P = 0.003$ ). When we stratified the TCF21 genotypes per age group (55 years), the CC genotype in the younger group had more obstructed disease (47.4%) when compared with GG (18.8%) ( $P = 0.012$ ), but this effect was not significant in the older group. Multivariate analysis (logistic regression) showed that the CC genotype had a high risk of multivessel coronary disease (OR = 2.88;  $P = 0.001$ ) than GG.

**Conclusion:** This work shows that the TCF21 wild genotype protects against CAD severity. In contrast, the CC genotype is associated with an increased risk of CAD severity.

## Poster No. 071 Application of artificial intelligence in coronary CT angiography: a potential gatekeeper strategy?

José Miguel Viegas<sup>1†</sup>, João Ferreira Reis<sup>1</sup>, Rita Teixeira<sup>1</sup>, Sofia Jacinto<sup>1</sup>, Tiago Mendonça<sup>1</sup>, Ruben Ramos<sup>1</sup>, Hugo Marques<sup>1</sup>, Luísa Figueiredo<sup>1</sup>, James Earls<sup>2</sup>, and Rui Cruz Ferreira<sup>1</sup>

<sup>1</sup>Centro Hospitalar Lisboa Central E.P.E.

<sup>2</sup>Cleerly Inc.

† The presenting author.

**Introduction:** Medical artificial intelligence (AI) is rapidly developing and moving from the research field to daily clinical practice. AI algorithms have demonstrated high performance and computational efficiency, reducing the degree of manual input and processing time.

**Objectives:** This study aimed to determine the impact of an AI-enabled coronary computed tomography angiography (CCTA) analysis for comprehensive evaluation in patients (P) with suspected coronary artery disease (CAD).

**Methods:** We analysed 100 CCTA exams from a cohort of symptomatic P with mild-to-moderately abnormal non-invasive ischemia test. Stenosis severity was assessed by level III experts (manual evaluation, MEv). A novel AI-based software tool (automatic evaluation, AEv) was also used to quantify coronary stenosis and characterize plaque phenotype. In P later referred for invasive coronary angiography (ICA), diagnostic and revascularization yields of MEv and AEv were compared.

**Results:** 100P, 52% male, mean age  $68 \pm 10$  years, one-third had typical angina. Prevalence of obstructive CAD determined by MEv and AEv was 25% and 21%, respectively, with a significant association between both assessments ( $P < 0.001$ ).

Based upon MEv, referring physician decided to proceed to ICA in 22P (21P with significant stenosis). For those undergoing ICA, 13P also had obstructive CAD established by AEv. Diagnostic yields for MEv and AEv-guided ICA was 82% and 60%, and revascularization yields 73% and 60%, respectively.

AEv atherosclerosis quantification revealed significant differences between P who did not undergo ICA, P referred for ICA without significant stenosis and P with obstructive CAD on ICA: total ( $126$  vs.  $312$  vs.  $518$  mm<sup>3</sup>,  $P < 0.001$ ), calcified ( $23$  vs.  $197$  vs.  $222$  mm<sup>3</sup>,  $P < 0.001$ ), non-calcified ( $71$  vs.  $112$  vs.  $252$  mm<sup>3</sup>,  $P < 0.001$ ) and low-density plaque volume ( $1.1$  vs.  $3.0$  vs.  $4.4$  mm<sup>3</sup>,  $P = 0.042$ ).

**Conclusion:** A diagnostic strategy using AI-based analysis of coronary stenosis severity on CCTA had a similar performance compared to MEv. In addition, risk prediction can be enhanced by AI assessment of plaque composition. This study is an example of the potential role of AI in the CCTA workflow.

## Poster No. 072 The profile of rhythm disorders in women with ischemic heart disease in a Romanian hospital

Irimie Diana Andrada<sup>1</sup>, Zdrengea Dumitru<sup>1†</sup>, Fringu Florina<sup>1</sup>, Popescu Mircea Ioachim<sup>2</sup>, and Pop Dana<sup>1</sup>

<sup>1</sup>5th Department of Internal Medicine, Faculty of Medicine, "Iuliu Hațieganu" University of Medicine and Pharmacy, 400012 Cluj-Napoca, Romania. Department of Cardiology, Clinical Rehabilitation Hospital, 400347 Cluj-Napoca, Romania

<sup>2</sup>Department of Medical Disciplines, Faculty of Medicine and Pharmacy, University of Oradea, 410073 Oradea, Romania. Cardiology Department, Clinical County Emergency Hospital of Oradea, 410169 Oradea, Romania

† The presenting author.

**Background:** In Europe, the mortality secondary to ischemic heart disease is an important cause of death among women. Rhythm disorders are frequently encountered in the context of this pathology. The aim of the study is to evaluate the profile of rhythm disorders in women with microvascular and obstructive coronary heart disease.

**Materials and methods:** We included in the study a number of 150 patients with ischemic heart disease documented by coronary angiography, with an average age of  $63.24 \pm 10.09$  years, admitted in the Cardiology Department of the Clinical Rehabilitation Hospital, Cluj-Napoca, Romania. The diagnosis of ischemic heart disease was established according to the recommendations of the 2019 ESC guideline.

**Results:** 66.6% of patients presented with microvascular angina, and 33.33% with obstructive coronary heart disease. Women with microvascular angina were younger ( $61.07 \pm 9.68$  vs.  $67.60 \pm 9.55$  years). Atrial arrhythmias were the most frequent arrhythmias diagnosed - 64.66%. The percentage of rhythm disorders was similar in the two groups, without statistically significant differences: atrial fibrillation (21 vs. 22%), other supraventricular arrhythmias (39 vs. 52%), ventricular extrasystoles (42 vs. 44%), sustained/nonsustained ventricular tachycardia (4 vs. 4%). This finding shows us that not only obstructive coronary artery disease, but also microvascular angina presents an arrhythmogenic risk. At the same time, there were no significant differences regarding the administration of antiarrhythmics, namely amiodarone and betablockers in the two forms of ischemic heart disease.

**Conclusions:** Women with microvascular angina present significant arrhythmias, therefore they must be carefully evaluated and treated accordingly.

## Poster No. 080 Relationship between triglyceride glucose index, MACE and nephropathy in type 2 diabetes

Mercea Delia<sup>1†</sup>, Mociran Mihaela<sup>2</sup>, Ianos Raluca<sup>1</sup>, Sitar-Taut Adela<sup>3</sup>, D Sporis<sup>3</sup>, A Ganea<sup>3</sup>, A Lazar<sup>3</sup>, V Malinescu<sup>4</sup>, and A Cozma<sup>3</sup>

<sup>1</sup>Cardioplus Center SRL

<sup>2</sup>Euromedica Hospital SA

<sup>3</sup>University of Medicine Iuliu Hatieganu Cluj Napoca

<sup>4</sup>University Of Medicine Iuliu Hatieganu Cluj Napoca

† The presenting author.

**Background:** The triglyceride glucose (TyG) index, a simple surrogate estimate of insulin resistance, has been demonstrated to predict cardiovascular disease morbidity and mortality in the general population. To explore the relationship between TyG index, MACE (major adverse cardiovascular events) and diabetic nephropathy in type 2 diabetes, we evaluated TyG index for 3 consecutive years.

**Material and methods:** This was a cross-sectional observational study that examined 172 subjects with T2DM. The mean age of the study participants was  $61.71 \pm 13.16$  years, and 90 were female. The primary outcomes included the occurrence of MACE, defined as all-cause death, non-fatal myocardial infarction and non-fatal stroke. Subjects underwent a detailed standard evaluation to detect diabetic nephropathy (defined as urinary albumin excretion  $\geq 30$  mg/24 h). The TyG index was calculated as  $\ln(\text{fasting triglycerides} \times \text{fasting glucose}/2)$  and stratified into 4 quartiles (TyG-Q). The baseline characteristics of the study population in the four TyG-Q (Q1 ( $\leq 8.95$ )  $n=43$ , Q2 ( $> 8.95$  to  $\leq 9.27$ )  $n=43$ , Q3 ( $> 9.27$  to  $\leq 9.7$ )  $n=43$ , and Q4 ( $> 9.7$ )  $n=43$ ) were analysed.

**Results and conclusions:** Higher TyG-Q correlated with the presence of nephropathy ( $p=0.028$ ), age ( $p=0.0172$ ), HbA1c levels ( $p=0.001$ ) and the presence of arterial hypertension ( $p=0.032$ ). The optimal TyG index cut-off for predicting MACE was 9.271 (sensitivity 54.0%; specificity 54%; area under the curve 0.532). The TyG index was significantly associated with MACE, suggesting that the TyG index may be a valid marker for risk stratification and prognosis in patients with T2DM.

## Poster No. 092 The impact of pre-existing right bundle brunch block on short and mid-term outcomes after transcatheter aortic valve implantation

Mariana Ribeiro Silva<sup>1</sup>†, Gualter Santos Silva<sup>1</sup>, Pedro Ribeiro Queirós<sup>1</sup>, Mariana Brandão<sup>1</sup>, Diogo Santos-Ferreira<sup>1</sup>, Cláudio Guerreiro<sup>1</sup>, Marco Oliveira<sup>1</sup>, Helena Gonçalves<sup>1</sup>, João Primo<sup>1</sup>, Gustavo Pires-Morais<sup>1</sup>, Bruno Melica<sup>1</sup>, Lino Santos<sup>1</sup>, Alberto Rodrigues<sup>1</sup>, Pedro Braga<sup>1</sup>, and Ricardo Fontes-Carvalho<sup>1</sup>

<sup>1</sup>Centro Hospitalar Vila Nova De Gaia / Espinho E.P.E.

† The presenting author.

**Background:** We aimed to evaluate whether pre-existing right bundle brunch block (RBBB) is associated to higher risk of permanent pacemaker implantation (PPI) and short and mid-term all-cause mortality in patients (pts) undergoing transfemoral TAVI.

**Material and methods:** pts who underwent TAVI between 2016 and 2018 were included and those with prior PP, non-transfemoral approach and valve-in-valve procedures were excluded. ECG data before, immediately after the procedure, at day 3 post-TAVI and at discharge were collected, and continuous telemetry was recorded. We evaluated the rates of temporary and PPI during hospital stay and at 1-year follow-up (FUP), ventricular pacing rates in the first visit after PPI and all-cause mortality at 30-days, 3 and 6 months and 1-year after TAVI.

**Results and conclusions:** 220 pts were included. Baseline RBBB occurred in 18 pts (8,2%).

Patients with RBBB presented higher baseline QRS duration ( $140,0 \pm 16,9$  ms vs.  $107,9 \pm 26,6$  ms;  $P=0,002$ ), without differences in QRS duration immediately or at day-3 after TAVI ( $P>0,05$ ). High-degree atrioventricular block and complete atrioventricular block immediately after TAVI were more frequent in pts with RBBB (44,4% vs. 14,5%,  $P=0,004$ ).

Patients with baseline RBBB presented significantly higher rates of PPI during hospital stay (55,6% vs. 20,0%;  $P=0,002$ ) and higher rates of PPI at 1-year FUP (58,8% vs. 21,4%;  $P=0,002$ ). The rates of ventricular pacing at the first visit in pts with RBBB was 75,0% (vs 47,2%;  $P=0,139$ ).

No differences were found regarding 30-day, 3 and 6 months and 1-year FUP regarding all-cause mortality, between pts with and without RBBB.

## Poster No. 094 Age-dependent decline in common femoral artery flow-mediated dilation and wall shear stress in healthy subjects

Mariam Bapir<sup>1†</sup>, Simon S Skene<sup>1</sup>, Paola Campagnolo<sup>2</sup>, and Christian Heiss<sup>1</sup>

<sup>1</sup>Department of Clinical and Experimental Medicine, University of Surrey

<sup>2</sup>Department of Biochemical Sciences, University of Surrey

† The presenting author.

**Background:** Femoral artery (FA) endothelial function is a promising biomarker for peripheral artery disease (PAD) prevention. We assessed FA flow-mediated dilation (FMD) in healthy adults of various ages.

**Material and methods:** Repeated common FA and brachial artery (BA) FMD measurements were performed with ultrasound induced by 5 minutes distal cuff occlusion (thigh, calf, forearm) to assess intra- and interindividual variability and acceptability ( $n = 10$ ). We then performed a cross-sectional study with FA- and BA-FMD measurements in healthy participants aged 18–80 ( $n = 53$ ).

**Results and conclusions:** All FMD protocols had good reproducibility with average deviation of  $-0.1\%$  (SD 0.6%, 0.9%, 0.6%) but thigh occlusion was less well tolerated. BA- and FA-FMD with thigh occlusion did not significantly differ while FA-FMD with calf occlusion was significantly lower ( $-1.0 \pm 0.9\%$ ).

Both FA-FMD and BA-FMD inversely correlated with age and baseline diameter and positively with wall shear stress (WSS). FA-FMD and BA-FMD correlated significantly ( $r = 0.57$ ,  $P < 0.001$ ). The baseline diameter was significantly greater in the FA as compared to the BA while the WSS was significantly lower. At the onset of reactive hyperaemia, the mean flow velocity, WSS and flow reserve were lower in the FA as compared to the BA. A large proportion of FA WSS values in older participants were below  $5 \text{ dyne/cm}^2$  which is regarded as pro-atherogenic.

FA endothelial function declines with age in parallel with the BA. FAs exhibits stronger age-dependent enlargement as compared to the BA leading to a critical decrease in WSS that may explain part of the age-dependent predisposition for PAD.

## Poster No. 095 The predictors of clinical outcome in the patients undergoing endovascular intervention for lower extremity peripheral arterial disease

Kim Byung Ok<sup>1</sup>†

<sup>1</sup>Inje University, Sanggye-paik Hospital

† The presenting author.

**Background:** Patients with peripheral arterial disease (PAD) have a higher mortality rate than patients without PAD. This study aimed to identify the predictors of mortality outcomes in patients with peripheral artery disease undergoing lower extremity endovascular interventions.

**Materials and methods:** We studied 300 consecutive patients admitted for symptomatic PAD. A 196 patients without angina and prior coronary revascularization ( $72 \pm 10$  years, 156 men) who underwent lower extremity endovascular intervention (claudication,  $n = 74$ ; critical limb ischemia,  $n = 122$ ) were retrospectively analyzed. Results: During follow-up, all-cause mortality and MACCE at 3 year were 16.3% and 19.8%, respectively. The independent risk factors for all-cause mortality were old age ( $HR = 1.05$ ,  $P = 0.043$ ), lower body mass index ( $HR = 0.83$ ,  $P = 0.016$ ), critical limb ischemia ( $HR = 3.74$ ,  $P = 0.033$ ) and the presence of CAD ( $HR = 2.85$ ,  $P = 0.027$ ). This variable surpassed all classical risk factors (including smoking and history of hypertension or diabetes mellitus). Of the 196 patients, 101 patients (52%) had asymptomatic CAD; 1-VD ( $n = 35$ , 18%); 2-VD ( $n = 32$ , 16%); 3-VD ( $n = 28$ , 14%). At 3 year follow-up, patients with CAD had significantly higher all-cause mortality (19% vs. 11%,  $P = 0.018$ ) and higher MACCE rate (26% vs. 8%,  $P = 0.001$ ) compared to those without CAD.

**Conclusions:** Asymptomatic coronary artery disease (CAD) was found in half of the patients undergoing endovascular intervention for PAD and associated with higher mortality and MACCE rate. Therefore, detection of CAD might be important for risk stratification for these patients, especially with lower body mass index or critical limb ischemia.



## Poster No. 098 SGLT2-inhibitors as add-on therapy in cardiac amyloidosis: our experience

Prof. Giovanni Fazio<sup>1†</sup>

<sup>1</sup>Triolo Zancla Hospital

† The presenting author.

**Background:** Cardiac amyloidosis (CA) is a severe and progressive infiltrative disease caused by physiological, inherited or acquired abnormalities, which lead to the accumulation of amyloid fibrils in the cardiac interstitium. Despite recent evidence support the use of SGLT2-inhibitors in heart failure, including HFpEF for empagliflozin and dapagliflozin, there are no studies on the use of these drugs for the treatment of CA.

**Methods:** We enrolled 5 consecutive patients with symptomatic CA (II or III NYHA). The diagnosis was based on non-invasive criteria: echocardiographic criteria + grade 2 or 3 cardiac uptake at diphosphonate scintigraphy + negative serum light chains and negative serum and urine immunofixation. Mean age was 66,52 years, all male. Despite optimal therapy, they had symptoms of pulmonary and peripheral congestion. We added 10 mg of dapagliflozin daily to therapy and reassessed patients after 7 days.

**Results:** Dapagliflozin was effective as add-on therapy in CA. All treated patients reported an improvement in symptoms and signs. After 7 days, dyspnea improved, exercise tolerance evaluated in six minutes walking test increased (from a mean of 123 meters to a mean of 212 meters), and oedema decreased. Therapy was well tolerated, and no side effects were reported.

**Conclusions:** Our initial experience with dapagliflozin suggests that SGLT2-inhibitors may play a role in the treatment of cardiac amyloidosis. In our opinion, the growing evidence of this class of drugs in heart failure therapy justifies clinical trials on amyloidosis.

## Poster No. 103 Spontaneous coronary artery dissection: when pain and ST-segment elevation persist

Rafaela G. Lopes<sup>1†</sup>, Isabel Cruz<sup>1</sup>, Inês Pereira Oliveira<sup>1</sup>, Bruno Bragança<sup>1</sup>, Inês G. Campos<sup>1</sup>, Joel Ponte Monteiro<sup>1</sup>, Carla Almeida<sup>1</sup>, Alexandra Castro<sup>1</sup>, and Aurora Andrade<sup>1</sup>

<sup>1</sup>Hospital Padre Américo

† The presenting author.

A 44-year-old female with nonrelevant medical history was admitted due to chest pain. She was hemodynamically stable. Normal physical examination. ECG with ST-segment depression in the inferior leads. Echocardiogram had no contractility abnormalities. High-sensitivity troponin I (hsTnI) of 164.4 pg/mL. Non-ST-segment elevation myocardial infarction (NSTEMI) diagnosis was made. 12 hours later she developed refractory chest pain. Emergent coronariography depicted independent ostia for the anterior descending and circumflex arteries and type 1 spontaneous coronary artery dissection (SCAD) of the circumflex artery. During angiography, pain subsided and a conservative approach was adopted. An hour later, she had recurrent pain refractory to medical treatment and new onset of persistent ST-segment elevation in leads V4-V6. It was decided to perform percutaneous coronary intervention and a drug eluting stent was placed in the proximal circumflex artery. There was distal propagation of the parietal hematoma, but TIMI 3 flow was restored. She was discharged on day 6. 5 days later she was readmitted due to NSTEMI. She had recurrent episodes of chest pain followed by reelevation of hsTnI. Coronary computer tomography depicted distal progression of the dissection with involvement of a first obtuse marginal and distal circumflex. After uptitration of anti-ischemic medication she was discharged. The case underlines the challenging and non-linear approach of SCAD in the setting persistent chest pain. Besides the technical difficulties of angioplasty, with higher risk of restenosis and stent failure, most recommendations support a conservative approach. However, persistent chest pain imply further action, as exemplified in this case report.

## Poster No. 104 Impact of pre-treatment with a P2Y12 receptor inhibitor on delay to CABG surgery in a real-world population with non-ST segment elevation acute coronary syndrome

Daniel Gomes<sup>1†</sup>, Bruno ML Rocha<sup>1</sup>, Jorge Ferreira<sup>1</sup>, Mariana Sousa Paiva<sup>1</sup>, Rita Reis Santos<sup>1</sup>, Marina Raquel Santos<sup>2</sup>, Gonçalo Cunha<sup>1</sup>, Pedro de Araújo Gonçalves<sup>1</sup>, Susana Fevereiro<sup>1</sup>, Marisa Trábulo<sup>1</sup>, Carlos Aguiar<sup>1</sup>, Miguel Sousa-Uva<sup>1</sup>, José Neves<sup>1</sup>, and Miguel Mendes<sup>1</sup>

<sup>1</sup>Hospital De Santa Cruz

<sup>2</sup>Hospital Dr. Nélio Mendonça

† The presenting author.

**Background:** ESC guidelines for non-ST elevation acute coronary syndromes (NSTEMI-ACS) recommend against P2Y12 pre-treatment receptor inhibitors (P2Y12i) in patients undergoing early invasive management (< 24 h). The rationale is, in part, to prevent bleeding complications and the delay of coronary artery bypass graft surgery (CABG) in patients with suitable anatomy. This study aims to analyze the impact of P2Y12i pre-treatment on delay to CABG surgery in a real-world population with NSTEMI-ACS.

**Methods:** Single-centre retrospective cohort of consecutive patients with NSTEMI-ACS undergoing invasive evaluation in 2019. Those with previous CABG ( $n=31$ ) or non-obstructive coronary disease ( $n=57$ ) were excluded.

**Results:** Total cohort included 262 patients (mean age  $68 \pm 12$  years, 69% male, 15% with unstable angina and mean GRACE score  $134 \pm 35$ ). Median time from first medical contact to angiography was 2 (1–4) days. Overall, 168 (64%) patients underwent percutaneous coronary intervention, 47 (18%) were proposed for CABG and the remainder received conservative management. All patients considered for CABG received pre-treatment with P2Y12i, either clopidogrel or ticagrelor. Median time from angiography to CABG was 12 (7–15) days. Six patients experienced recurrent angina (13%) and 2 (4%) died before surgery due to refractory ventricular fibrillation. Those who underwent CABG under P2Y12i effect were more likely to receive blood and platelets transfusions (64.7% vs. 28.6%,  $P=0.017$  and 82.4% vs. 21.4%,  $P<0.001$ , respectively), although there were no differences regarding major bleeding.

**Conclusion:** Pre-treatment with P2Y12i was a potential driver of CABG delay in our cohort. In the real-world, adopting the new recommendations of withholding pre-treatment might decrease this delay.

## Poster No. 106 Can we optimize d-dimer cut off value to predict pulmonary embolism in covid-19 patients?

Rafaela Fernandes<sup>1</sup>†, Joana Moura Ferreira<sup>1</sup>, Ana Rita Alves<sup>1</sup>, Gabriela Almeida<sup>1</sup>, Vanessa Lopes<sup>1</sup>, Gil Cunha<sup>1</sup>, Gonçalo Costa<sup>1</sup>, Eric Monteiro<sup>1</sup>, Joana Guimarães<sup>1</sup>, Diogo Fernandes<sup>1</sup>, Ana Rita Gomes<sup>1</sup>, João Borges Rosa<sup>1</sup>, Gustavo Campos<sup>1</sup>, Diana Campos<sup>1</sup>, Carolina Loureiro<sup>1</sup>, José Paulo Almeida<sup>1</sup>, Sofia Martinho<sup>1</sup>, Paulo Martins<sup>1</sup>, and Lino Gonçalves<sup>1</sup>

<sup>1</sup>Centro Hospitalar E Universitário De Coimbra

† The presenting author.

**Background:** Covid-19 is associated with an increased risk of pulmonary embolism (PE) therefore, should the cut off d-dimer value be adjusted for these patients?

**Material and methods:** Retrospective and observational study to understand if there is a d-dimer cut-off that could guide clinics to perform a thoracic computed tomography angiography (CTA) in patients with covid-19. The population was covid-19 patients admitted to covid-19 dedicated wards of a University Hospital Centre for one year.

**Results and conclusions:** 725 (52%) patients with covid-19 had a d-dimer value dosed during the first 5 days of the disease. Those, 63 (9%) did a CTA with a diagnosis of 16 (25%) PE. Gender was equally represented, median age was 70 years (ID = 3.49) and the majority (94%) survived. Thirteen (81%) patients with PE had a d-dimer value above 2500 ng/mL (OR = 9.244, 95% CI 2.248–9.837), with 7 (54%) with values over 10000 ng/mL, but in 3 (9%) it was under 1500 ng/mL. Seventy-three (63%) of patients with a d-dimer over 1500 ng/mL did not had a thoracic CTA performed. In our population PE was not a frequent outcome. The results are influenced by the low number of thoracic CTA performed because, even tough the cut-off d-dimer value used at our hospital to perform a thoracic CTA to exclude PE is 1500 ng/mL, most patients with that d-dimer value did not take the exam and so PE could not be excluded. Although in most PE cases the d-dimer value was above 2500 ng/mL, the results of our study cannot verify if that is a better cut-off value.

## Poster No. 108 Effectiveness and safety of P2Y12 inhibitor pretreatment for primary PCI in STEMI: Systematic review and meta-analysis

João Presume<sup>1†</sup>, Daniel Gomes<sup>1</sup>, Jorge Ferreira<sup>1</sup>, Francisco Albuquerque<sup>1</sup>, Manuel Sousa Almeida<sup>1</sup>, Miguel Sousa Uva<sup>1</sup>, Carlos Aguiar<sup>1</sup>, and Miguel Mendes<sup>1</sup>

<sup>1</sup>Hospital De Santa Cruz

† The presenting author.

Double antiplatelet therapy (DAPT) with both aspirin and P2Y12 inhibitors in patients with STEMI has been shown to be associated with better clinical outcomes. Yet, there is uncertainty regarding the optimal timing for its initiation. This study is a systematic review and meta-analysis of the current evidence on pretreatment with P2Y12 inhibitors in patients with STEMI submitted to primary percutaneous coronary intervention (PCI).

We performed a systematic search of electronic databases Pubmed, CENTRAL and Scopus until April/22. Studies were considered eligible if they were comparing P2Y12 inhibitor upstream administration vs. downstream use in patients with STEMI submitted to PCI. Studies with patients treated with fibrinolysis or medical therapy only were excluded. Outcomes were assessed at the shortest follow-up available.

Out of 2336 articles, 18 studies were included (3 RCT and 17 non-RCT), with a total of 79300 patients (52439 in the pretreatment arm). Pretreatment was associated with a reduction in definite stent thrombosis (OR 0.59 [0.37–0.94]), all-cause death (OR 0.77 [0.60–0.97]) and cardiogenic shock (OR 0.60 [0.48–0.75]). It was also associated with lower incidence of TIMI flow < 3 pre-PCI (OR 0.78 [0.67–0.92]). However, it was not associated with a significant reduction in recurrent MI (OR 0.93 [0.57–1.52]). Regarding safety outcomes, pretreatment was not associated with higher risk of major bleeding events (OR 0.83 [0.75–0.92]).

Pretreatment with DAPT, including a P2Y12 inhibitor, was associated with better pre-PCI coronary perfusion, lower risk for definite stent thrombosis, cardiogenic shock, and all-cause mortality. No sign of potential harm from this approach was encountered.

## Poster No. 109 Prognostic value of white blood cell count variation during in-hospital stay in STEMI patients: Insights from SCALIM Registry

Marouane Boukhris<sup>1</sup>, Camille Dierx Molié<sup>1</sup>, Pierre Chenard<sup>1</sup>†, Amandine Gourceyrol<sup>1</sup>, Amandine Gasnier<sup>1</sup>, Patrice Viot<sup>1</sup>, and Victor Aboyans<sup>1</sup>

<sup>1</sup>University Hospital of Limoges - Hospital Dupuytren, Limoges (France)

† The presenting author.

**Background:** In patients with ST-elevation myocardial infarction (STEMI), white blood cell count (WBCC) is associated with infarct size and cardiovascular outcome. We sought to determine the impact of WBCC variation (?WBCC) during in-hospital stay on long-term outcome after STEMI.

**Methods:** From 2011 to 2019, consecutive patients with STEMI were enrolled. Those with at least two WBCC during hospitalization were included in this study. ?WBCC was calculated as: [WBCC (admission) – WBCC (before discharge)]. The population was divided into 3 groups according to ?WBCC tertiles. The primary outcome was total mortality.

**Results:** A total of 1778 patients (mean age  $64.5 \pm 14.1$ , 75.7% males), were included and divided in 3 groups: Group 1 (?WBCC  $< 0.85 \cdot 10^3/\text{mm}^3$ ); Group 2 (?WBCC  $0.85\text{--}3.31 \cdot 10^3/\text{mm}^3$ ); and Group 3 (?WBCC  $> 3.31 \cdot 10^3/\text{mm}^3$ ). Patients in Group 1 were the oldest ( $67.9 \pm 13.8$ , vs.  $65.1 \pm 13.9$  and  $60.5 \pm 13.7$  years in Groups 2 and 3 respectively,  $P < 0.001$ ). Hypertension, prior coronary artery bypass and cancer were more prevalent in Groups 1 and 2. Troponin peak was the highest in Group 3 ( $3601 \pm 563$ ) than Group 2 and 3 ( $2810 \pm 439$  and  $2451 \pm 467$  ng/ml, respectively;  $P < 0.001$ ).

Five-year survival was the lowest in Group 1 (78.6% vs. 87.2% and 87.5% in Group 2 and 3, respectively;  $P < 0.001$ ). Adjusted to age, gender, cardiovascular risk factors, MI territory and left ventricular ejection fraction, ?WBCC  $< 0.85 \cdot 10^3/\text{mm}^3$  was independently associated with all-cause mortality [HR 1.46; 95%CI 1.12–1.91;  $P = 0.005$ ].

**Conclusion:** ?WBCC  $< 850/\text{mm}^3$  is associated with increased mortality. Low ?WBCC during hospitalization could represent an interesting prognostic tool in STEMI patients.

## Poster No. 110 History of venous thromboembolic disease: a prognostic risk marker following STEMI? Insights of the French SCALIM registry

Pierre Chenard<sup>1</sup>†, Benjamin Dousset<sup>1</sup>, Marouane Boukhris<sup>1</sup>, Patrice Viot<sup>1</sup>, and Victor Aboyans<sup>1</sup>

<sup>1</sup>University Hospital of Limoges - Hospital Dupuytren, Limoges (France)

† The presenting author.

**Background:** Venous and arterial thrombosis are two different entities. However, they share common risk factors and a continuum between arterial and venous thrombosis has been suggested. The purpose of our study was to determine whether a history venous thromboembolic disease (VTE) is associated with poorer outcome in patients with ST-elevation myocardial infarction (STEMI).

**Methods:** All consecutive STEMI patients between 2011 and 2019 were included in our regional SCALIM registry. Clinical history of VTE was collected at baseline. The primary outcome was cardiovascular mortality and recurrent non-fatal arterial events (including non-fatal-myocardial infarction, ischemic stroke and peripheral ischemic event) at 5-year follow-up. The secondary outcome was total mortality.

**Results:** A total of 1924 patients ( $64.7 \pm 14.1$  years; 75.1% men) were included, among whom 2.8% with history of VTE. The latter were older than those without VTE (respectively  $72.8 \pm 14.1$  vs.  $64.4 \pm 14.0$  years;  $P < 0.001$ ) and had more often hypertension, history of stroke and cancer. We found no statistical difference between the two groups regarding the 5-year cardiovascular mortality (11.3% vs. 7.1%,  $P = 0.231$ ) and recurrent non-fatal arterial events (17.0% vs. 14.9%,  $P = 0.754$ ). Five-year all-cause mortality was significantly higher in patients with history of VTE (33.3% vs. 14.6%,  $P = 0.001$ ).

In a nested case-control study adjusted for age, no difference was found in primary and secondary outcomes according to VTE history.

**Conclusion:** We found no impact of history of VTE on 5-year cardiovascular outcome in who had STEMI patients. Higher mortality in these patients are related to older age and comorbidities.

## Poster No. 111 Therapeutic Options and Outcomes in Mid Aortic Syndrome A systematic review and meta-analysis

Roland RJ Van Kimmenade<sup>1</sup>†, Kimberley Cortenbach<sup>1</sup>, Bahram Yosofi<sup>1</sup>, Laura Rodwell<sup>1</sup>, Jelena Meek<sup>1</sup>, Ritesh Patel<sup>2</sup>, Siddharth Prakash<sup>3</sup>, Niels Riksen<sup>1</sup>, Sjoerd Jenniskens<sup>1</sup>, Mark Dirven<sup>1</sup>, and Marco de Ruiten<sup>4</sup>

<sup>1</sup>RadboudUMC, Nijmegen, the Netherlands

<sup>2</sup>University of South Florida

<sup>3</sup>The John Ritter Research Program in Aortic and Vascular Diseases

<sup>4</sup>LUMC

† The presenting author.

**Objective:** Mid-Aortic Syndrome (MAS) is narrowing of the distal thoracic and/or abdominal aorta with congenital, inflammatory or idiopathic aetiology. If untreated, prognosis is poor due to hypertensive complications yet follow-up data are sparse. The aim of this study was to investigate hypertension during follow-up after medical, endovascular, and surgical therapy.

**Design and methods:** A meta-analysis of case series and reports, focusing on the incidence of hypertension during the follow-up of juvenile (0–17 years) and adult MAS patients after medical, endovascular or surgical therapy. Search queries were performed in PubMed, Embase, and Web of Science; eligible articles underwent quality control. Descriptive statistics were reported based on available data, individual patient data meta-analyses were performed using a one-stage approach, accounting for clustering by case series or decades of reporting for case reports. For the meta-analysis, missing outcome and aetiology data were multiply imputed.

**Results:** The number of juveniles and adults who underwent endovascular therapy (33.7% versus 27.3%;  $P = .42$ ) and surgery (52.2% versus 58.0%;  $P = .46$ ) was similar. At baseline, 92.4% of juveniles and 87.5% of adults were hypertensive, decreasing to 23.2% and 24.1% during a follow-up of 23 (juveniles) and 18 (adults) months. In juveniles, after endovascular therapy more hypertension was found compared to surgery (38.1% versus 10.8%;  $P = .020$ ). Meta-analysis demonstrated a trend for hypertension after endovascular therapy in juveniles, whereas hypertension was more prevalent following surgery in adults compared to endovascular therapy or medication.

**Conclusions:** Complications and hypertension in MAS during follow-up were more common in juveniles after endovascular treatment, whereas surgery in adults was associated with more hypertension.



## Poster No. 113 Case report: the challenges in diagnosing congenital double-chambered left ventricle in adults

Mengfei Lu<sup>1</sup>†, dr Joseph Appiah<sup>1</sup>, and dr Mae-Sing Lim-Cooke<sup>1</sup>

<sup>1</sup>Princess Alexandra Hospital

† The presenting author.

**Background:** Double-chambered left ventricle is a congenital condition that rarely presents in adulthood. This case report illustrates the common cardiac imaging modalities and presents the diagnostic challenges.

**Material and method:** Clinical history and cardiac imaging was obtained using electronic systems and E-letters. Literature search was performed using PubMed with keywords including double-chambered ventricle and congenital heart disease.

**Discussion:** A 76-year-old female presented with breathlessness, her transthoracic echocardiogram (TTE) showed severely impaired bi-ventricular function. An incidental echogenic structure was identified and treated initially as a left ventricular (LV) thrombus. Follow-up cardiac magnetic resonance (CMR) with perfusion confirmed the LV apical mass, but thought was more in keeping with a tumour. Further investigations with a gated cardiac Computerised Tomography (CT) and a review of the original CMR demonstrated appearances that were consistent with a developmental congenital double-chambered left ventricle rather than a false aneurysm or thrombus. This was confirmed on repeat CMR and with enhancement and transoesophageal echocardiogram (TOE) on 3D reconstruction. A discussion between Cardiologist and Cardiac Surgeons concluded that she is unlikely to benefit from any surgical intervention. The patient has since had significant improvement in LV function with medical therapy.

**Conclusions:** This report highlights an interesting case where congenital double-chambered left ventricle can act as a mimic for left ventricular thrombus or tumour. Current cardiac imaging modalities can be used in combination to achieve the diagnosis. It also demonstrates that pharmacological therapy alone is an adequate treatment to manage the symptoms of severely impaired bi-ventricular function in these patients.

## Poster No. 115 Switch the risk: from PDE5i to Riociguat in real world pulmonary hypertension

Mariana Martinho<sup>1</sup>†, Sofia Alegria<sup>1</sup>, Filipa Ferreira<sup>1</sup>, Rita Calé<sup>1</sup>, Débora Repolho<sup>1</sup>, Ana Rita Pereira<sup>1</sup>, Alexandra Briosa<sup>1</sup>, João Grade Santos<sup>1</sup>, Bárbara Ferreira<sup>1</sup>, Diogo Santos Cunha<sup>1</sup>, Oliveira Baltazar<sup>1</sup>, Nazar Ilchyshyn<sup>1</sup>, João Mirinha Luz<sup>1</sup>, Maria José Loureiro<sup>1</sup>, and Hélder Pereira<sup>1</sup>

<sup>1</sup>Hospital Garcia De Orta, E.P.E.

† The presenting author.

**Introduction:** Switching from phosphodiesterase-5 inhibitors (PDE5i) to Riociguat is associated with increased efficacy in pulmonary arterial hypertension (PAH) and chronic thromboembolic pulmonary hypertension (CTEPH).

**Objective:** To show clinical efficacy of replacing PDE5i to Riociguat in a portuguese PH-dedicated centre.

**Methods:** Retrospective single-centre study of PAH and inoperable/persistent/recurrent CTEPH patients (pts) who switched vasodilator therapy. Parameters were stratified according to the 2022 PH guidelines and stratification as low/intermediate/high-risk PH followed the COMPERA registry, before switching, at 3–6 months of follow-up (FUP) and until the last clinical evaluation, balloon pulmonary angioplasty (BPA), heart transplant or death.

**Results:** Of 13 pts, 75.0% had CTEPH (4 pts had persistent disease after surgical endarterectomy), 16.7% had PAH and 1pt had mixed PAH/CTEPH. Mean age was  $56.2 \pm 16.3$  years and 83.3% were females. Mean time until switch was  $33.5 \pm 25.5$  months. Previous therapy was: 33.3% Sildenafil, 41.7% Sildenafil/Bosentan and 25% Sildenafil/Bosentan/prostanoid. Before switching, 66.7% had intermediate and 33.3% low-risk PH; at a FUP of  $4.4 \pm 1.7$  months, 8.3% had intermediate and 91.7% low-risk PH. There was a significant benefit in the COMPERA risk ( $1.50[1.33;1.62]$  vs.  $1.22[1.09;1.40]$ ,  $P=0.011$ ). Long-term FUP was performed in 8 pts at  $48.2 \pm 35.6$  months (death 1pt, transplant 1pt, BPA 3 pts). Medical treatment was Riociguat in 33.3%, Riociguat and Bosentan in 58.3%, and 1pt with Riociguat, Bosentan and Treprostinil. Clinical benefit was significant at long-term FUP when compared to the initial evaluation ( $1.22[1.09;1.40]$ ,  $P=0.011$ ), but not to the first FUP.

**Conclusion:** This study corroborates previous evidence regarding the vasodilator switch and also suggests that the treatment goal is maintained throughout long-term FUP.

## Poster No. 116 Hemodynamic characteristics associated with partial thrombosis of the false lumen in patients with chronic aortic dissection of the descending aorta: a 4D flow CMR study

Aroa Ruiz Muñoz<sup>1</sup>†, Andrea Guala<sup>1</sup>, Lydia Dux-Santoy<sup>1</sup>, Gisela Teixidó-Turà<sup>1</sup>, Juan Garrido-Oliver<sup>1</sup>, Ana Garcia-Duran<sup>1</sup>, Filipa Valente<sup>1</sup>, Laura Galian-Gay<sup>1</sup>, Laura Gutierrez<sup>1</sup>, Hug Cuellar-Calabria<sup>1</sup>, Kevin Johnson<sup>2</sup>, Oliver Wieven<sup>2</sup>, Ignacio Ferreira-Gonzalez<sup>1</sup>, Arturo Evangelista<sup>1</sup>, and Jose Rodriguez-Palomares<sup>1</sup>

<sup>1</sup>Hospital Universitari Vall Hebron

<sup>2</sup>University of Wisconsin

† The presenting author.

**Background:** Partial thrombosis of the false lumen (FL) in patients with chronic aortic dissection (AD) of the descending aorta has been associated with faster aortic dilation. Four-dimensional phase-contrast cardiovascular magnetic resonance (4D flow CMR) studies analyzing flow dynamics and biomechanics in the FL and their relationship with partial thrombosis are lacking. This study aimed to compare FL flow dynamics and biomechanics between patients with a patent and partially thrombosed FL.

**Materials and methods:** Patients with a chronic, patent (no thrombus) or partially thrombosed FL in the descending aorta after an AD underwent an imaging follow-up including a magnetic resonance angiography (MRA) and a 4D flow CMR study. FL thrombosis was quantified as the ratio of thrombus volume and FL volume on MRA. FL flow dynamics was assessed in terms of forward flow, wall shear stress (WSS), maximum kinetic energy (KE) and acceleration, and flow stasis on 4D flow CMR. Aortic stiffness in the FL was quantified using pulse wave velocity (PWV).

**Results and conclusions:** Sixty-five patients with a complete imaging protocol were included in the study (patency in 34 patients, partial thrombosis in 31). Partial thrombosis of the FL was associated with a reduction in the amount and energy of flow in the FL (reduced forward systolic flow, KE and acceleration), and a more stagnated flow in the FL (increased flow stasis). Axial WSS showed a tendency to be lower in the partial thrombosis group compared to the patency group, while PWV were similar in both of them.

**Funding:** IJC2018-037349-I.

## Poster No. 117 rs12526196 polymorphism in CCN2 gene is an independent risk factor for ascending thoracic aortic aneurysm

Isabel Rodríguez<sup>1†</sup>, Antonio Tejera-Muñoz<sup>2</sup>, Álvaro Del Río-García<sup>1</sup>, Yamina Mohamedi<sup>1</sup>, María Martín Fernández<sup>3</sup>, Valentina Chiminazzo<sup>4</sup>, Beatriz Suárez-Álvarez<sup>5</sup>, Carlos López-Larrea<sup>6</sup>, Marta Ruiz-Ortega<sup>7</sup>, and Raúl Rodríguez-Díez<sup>8</sup>

<sup>1</sup>CardiacPathologyResearchGroup, Instituto de Investigación Sanitaria del Principado de Asturias (ISPA), 33011, Oviedo, Asturias, Spain

<sup>2</sup>ResearchSupportUnit, Hospital General Mancha Centro, 13600 Alcázar de San Juan, Spain. Molecular and CellularBiology in Renal and Vascular Pathology, IIS-Fundación Jiménez Díaz, Universidad Autónoma de Madrid, Av Reyes Católicos 2, 28040 Madrid, Spain

<sup>3</sup>CardiologyDepartment, Hospital Universitario Central de Asturias, 33011, Oviedo, Asturias, Spain CardiacPathologyResearchGroup, Instituto de Investigación Sanitaria del Principado de Asturias (ISPA), 33011, Oviedo, Asturias, Spain

<sup>4</sup>Biostatistics and EpidemiologyPlatform, Instituto de Investigación Sanitaria del Principado de Asturias (ISPA), 33011, Oviedo, Asturias, Spain

<sup>5</sup>TranslationalImmunology. Instituto de Investigación Sanitaria del Principado de Asturias ISPA, 33011, Oviedo, Asturias, Spain

<sup>6</sup>Servicio de Inmunología, Hospital Universitario Central de Asturias, 33011, Oviedo, Asturias, Spain

<sup>7</sup>Molecular and CellularBiology in Renal and Vascular Pathology, IIS-Fundación Jiménez Díaz, Universidad Autónoma de Madrid, Av Reyes Católicos 2, 28040 Madrid, Spain. TranslationalImmunology. Instituto de Investigación Sanitaria del Principado de Asturias ISPA, 33011, Oviedo, Asturias, Spain

<sup>8</sup>CTranslationalImmunology. Instituto de Investigación Sanitaria del Principado de Asturias ISPA, 33011, Oviedo, Asturias, Spain

† The presenting author.

**Background:** The Cellular Communication Network Factor-2 (CCN2/CTGF) has been traditionally described as a downstream mediator of other profibrotic factors including transforming growth factor (TGF)- $\beta$  and Angiotensin II. However, recent evidence from our group demonstrated the direct role of CCN2 in maintaining aortic wall homeostasis and, in addition, the development of acute and lethal aortic aneurysm induced by Angiotensin II in absence of CCN2 in mice. In order to translate these findings to humans, we evaluated the potential association between three polymorphisms in the CCN2 gene and the presence of thoracic aortic aneurysm (TAA).

**Material and methods:** 69 patients with TAA and 297 controls were genotyped for rs6918698, rs9402373 and rs12526196 polymorphisms related to CCN2 gene. Multivariable logistic regression models were performed.

**Results and conclusions:** While no associations were found between rs6918698 and rs9402373 with TAA development, patients carrying the C allele from rs12526196 polymorphism have a higher probability of suffering TAA compared to patients with TT genotype, independently of other risk factors such as sex, age, hypertension, type of valvulopathy and presence of bicuspid aortic valve (OR = 3.17; 95% CI = 1.30–7.88;  $P = 0.011$ ). This study extrapolates to humans the relevance of CCN2 in aortic aneurysm observed in mice and postulate, for the first time, a protective role to CCN2 in aortic aneurysm pathology. Our results encourage future research to explore new variants, polymorphisms or mutations, in the CCN2 gene that could be predisposing to TAA development.

**Funding:** Research funded by ISCIII (PI20/000140, PI18/00694, PI19/00184, PI20/00639); RICORS2040-KIDNEY-DISEASE (RD21/0005/0002, RD21/0005/0017); Sara-Borrell-CD20/00042; Miguel-Servet-CP18/00106; Sociedad Española de Nefrología.

## Poster No. 118 The IL6rs1800795 polymorphism is associated with ascending thoracic aortic dilatation in bicuspid aortic valve patients

Isabel Rodríguez<sup>1†</sup>, Alejandro Junco-Vicente<sup>2</sup>, Valeria Rolfe-Sóñora<sup>3</sup>, Álvaro Del Río-García<sup>1</sup>, Guillermo Solache-Berrocal<sup>1</sup>, César Morís<sup>4</sup>, and María Martín Fernández<sup>5</sup>

<sup>1</sup>CardiacPathologyResearchGroup, Instituto de Investigación Sanitaria del Principado de Asturias (ISPA), 33011, Oviedo, Asturias, Spain

<sup>2</sup>Cardiology Department Hospital Universitario de Cabueñes, Gijón

<sup>3</sup>Biostatistics and EpidemiologyPlatform, Instituto de Investigación Sanitaria del Principado de Asturias (ISPA), 33011, Oviedo, Asturias, Spain

<sup>4</sup>CardiologyDepartment, Hospital Universitario Central de Asturias, 33011, Oviedo, Asturias, Spain CardiacPathologyResearchGroup, Instituto de Investigación Sanitaria del Principado de Asturias (ISPA), 33011, Oviedo, Asturias, Spain

<sup>5</sup>CardiologyDepartment, Hospital Universitario Central de Asturias, 33011, Oviedo, Asturias, Spain CardiacPathologyResearchGroup, Instituto de Investigación Sanitaria del Principado de Asturias (ISPA), 33011, Oviedo, Asturias, Spain

† The presenting author.

**Antecedentes:** Los pacientes con válvula aórtica bicúspide (BAV), en comparación con las personas con válvula aórtica tricúspide normal, tienen un mayor riesgo de desarrollar dilatación de la aorta ascendente (DAA). La disfunción valvular significativa no explica una complicación aórtica desafortunada y, por lo tanto, los mecanismos moleculares involucrados se encuentran bajo investigación. Uno de los procesos involucrados es la inflamación y las citocinas como la interleucina-6 están asociados con las dimensiones aórticas y con la degeneración de la matriz extracelular aórtica en modelos animales. . Por este motivo, nos propusimos analizar un polimorfismo del gen de la interleucina-6 (*IL6*), que regula positivamente la transcripción y traducción del gen, en pacientes con VAB.

**Material y métodos:** Presentamos una serie de 119 pacientes con VAB genotipados para el polimorfismo rs1800795 en la región promotora del gen *IL6*. Se realizaron modelos de regresión logística multivariable.

**Resultados y conclusiones:** Nuestros pacientes, todos con VAB, tenían una mediana de edad de 55 años, 76,5% hombres, 29,4% fumadores, 30% dislipidémicos, 35,3% hipertensos, 12,6% diabéticos y 44% con DAA de 39 a 49 mm. Homocigotos El genotipo para el alelo C del polimorfismo IL6 fue significativamente menos frecuente en pacientes con dilatación (OR = 0,32, IC del 95% = 0,11–0,96,  $P = 0,035$ ). Tras ajustar por variables de confusión como sexo, edad, hipertensión arterial y valvulopatía, los pacientes portadores del genotipo CC seguían teniendo menor probabilidad de padecer DAA (OR = 0,25; IC95% = 0,07–0,76;  $P = 0,02$ ).

La identificación de individuos con predisposición genética para el desarrollo de DAA es fundamental en beneficio de un seguimiento médico más estrecho. Son necesarios más estudios para evaluar su uso en la aortopatía bicúspide.

Investigación financiada por la Sociedad Española de Cardiología; ISCIII-PI1800694; Fundación-Asturcor; Programa Severo-Ochoa.

## Poster No. 119 Large arterial thrombi in the pulmonary vein are common in elderly subjects and may cause age-related disease by producing neutrophil extracellular traps

Hidekazu Takeuchi<sup>1†</sup>

<sup>1</sup>Takeuchi Naika Clinic

† The presenting author.

**Background:** Arterial thrombi (ATs) are formed by neutrophil extracellular traps (NETs) that are released from neutrophils when pulmonary infection occurs. NETs capture and kill pathogens, and NETs form ATs in the pulmonary vein to prevent pathogens from spreading to all organs via pulmonary vein flow. We reported several cases of pulmonary vein thrombi (PVTs) that are arterial thrombi, which were estimated using enhanced computed tomography (ECT) or transoesophageal echocardiography (TOE). However, PVTs are presently underrated. After the infection, the ATs become larger in the pulmonary vein to be PVTs. We reported that at least 61% of elderly individuals with chest pain had PVTs. It is unknown how many people with age-related diseases had PVTs. The aim of this study was to clarify the frequency of subjects with PVTs among subjects with age-related diseases.

**Materials and methods:** We performed ECT and TOE exams on 218 consecutive Japanese subjects (99 men and 119 women; age = 73.6 ( $\pm$  11.3)-year-old; range: 28- to 95-year-old) with age-related diseases, such as hypertension (139), dyslipidaemia (57), angina pectoris (31), diabetes mellitus (27), and atrial fibrillation (32).

**Results and conclusions:** We identified clear PVTs in 183 (83.9%) patients, unclear PVTs in 22 (10.1%) patients, and no PVTs in 13 (6.0%) patients using ECT. Among the 35 patients without clear PVT images from ECT, we identified PVTs in 32 patients using TOE. In total, 215 (98.6%) patients had PVTs. Among subjects with age-related diseases, 215 (98.6%) subjects had PVTs.

## Poster No. 120 Possible mechanism of the noncoding RNA control of thromboinflammation

Hidekazu Takeuchi<sup>1†</sup>

<sup>1</sup>Takeuchi Naika Clinic

† The presenting author.

**Background:** Neutrophil extracellular traps (NETs) promote arterial thrombus (AT) formation that induce thromboinflammation in organs. The mechanism of thromboinflammation is unclear. ATs block blood flow, and the associated areas should be affected by hypoxia and hypothermia, which can activate hypoxia-induced factors (HIFs) and heat shock protein (HSP).

**Materials and methods:** Sequence identification using BLAST.

**Results and conclusions:** HSP (CNNGAANNNTCCNNG), HIFs (RCGTG) and c-Myc (CACGTG) can bind and become cooperatively activated at the sequence CTTGAATT TCCACGTG (named HHc), which is located 170 kb downstream of EPHA7, a target that was identified using BLAST and has the sequence GGTTTGTTGTGTTC CCATCCATATCTCAT (FRONT(1–30)) directly before it. According to the results of the BLAST search, FRONT(1–30) + HHc was highly conserved among MICA, MICB, HLA-G, HLA-A, HLA-DQA2, HLA-DQB1, HLA-DQB4, HLA-DRB1, HLA-DRB4, HLA-F, and HCG4, which are associated with the major histocompatibility complex. Additionally, the FRONT(1–30) + HHc sequence was highly conserved in NFAT1 and TIGIT, which are associated with T-cells and in the ncRNA LOC105379251. Furthermore, this region is highly conserved among mTOR, MMD, C1QTNF1, SOX-9, AP2gamma, PHACTR3, ERA, and CITED2, indicating that these genes are modulated under hypothermic and hypoxic conditions. Our previous paper reported that this ncRNA has only the FRONT1 region but not the HHc sequence; however, here, we observed that this ncRNA had both the FRONT(1–30) and HHc regions. FRONT(1–30) + HHc was not conserved between humans and mice. FRONT(1–30) + HHc was highly conserved sequences around the gene loci associated with inflammation in human.

## Poster No. 122 Predicting the rate of progressive dilation by wall shear stress in bicuspid aortic valve patients

Jose Rodriguez-Palomares<sup>1†</sup>, Lydia Dux-Santoy<sup>1</sup>, Gisela Teixidó-Turà<sup>1</sup>, Aroa Ruiz-Muñoz<sup>1</sup>, Juan Garrido-Oliver<sup>1</sup>, Kevin Johnson<sup>2</sup>, Oliver Wieven<sup>2</sup>, Laura Galian<sup>1</sup>, Filipa Valente<sup>1</sup>, Laura Gutierrez<sup>1</sup>, Teresa Gonzalez-Alujas<sup>1</sup>, Augusto Sao-Aviles<sup>1</sup>, Arturo Evangelista<sup>1</sup>, Ignacio Ferreira-Gonzalez<sup>1</sup>, and Andrea Guala<sup>1</sup>

<sup>1</sup>Hospital Universitari Vall Hebron

<sup>2</sup>University of Wisconsin

† The presenting author.

**Background:** Despite the high prevalence of ascending aorta (AAo) dilation in bicuspid aortic valve (BAV) patients there is limited evidence of dilation aetiology. Several cross-sectional studies pointed to a role for wall shear stress (WSS), but this hypothesis has not been tested. Recently, a technique for 3D-maps of aortic growth from two contrast-enhanced computed tomography angiograms (CTA) was presented and validated. We aim to test if local WSS predicts local dilation rates in BAV patients.

**Materials and methods:** Forty BAV patients free from aortic valve disease and previous relevant interventions underwent a baseline 4D flow CMR followed by two CTA. WSS, and its axial and circumferential components, and growth rate (GR) were computed at 64 standardized regions in the ascending aortic (AAo). A two-tailed p-value < 0.05 was considered statistically significant.

**Results and conclusions:** Patients were relatively young ( $51 \pm 13$  years) and follow-up duration was  $44.8 \pm 2.6$  months. Growth rate was heterogeneous in the AAo, with fastest progression located in the outer mid AAo region and in the inner region of the proximal-mid AAo. WSS magnitude and WSS axial component were maximum in the right region of the mid AAo while circumferential WSS was highest in the outer region of the mid AAo, the region experiencing fastest growth. Significant associations between GR and circumferential WSS were located in the regions with fastest progressive dilation, while WSS magnitude and its axial component resulted in limited predictive capacity. In conclusion, circumferential WSS is related to fast progressive dilation in BAV patients.

**Funding:** *PI17/00381, SEC/FEC-INV-CL120/015, LCF/BQ/PR22/11920008, RTC2019-007280-1.*



## Poster No. 127 Intravenous statin administration during myocardial infarction mitigates cardiac damage and preserves cardiac function in diabetic cardiomyopathy rats

Sebastian Alcover<sup>1†</sup>, Sergi López<sup>1</sup>, Lina Badimon<sup>2</sup>, and Gemma Vilahur<sup>3</sup>

<sup>1</sup>Cardiovascular Program, Institut de Recerca, Hospital de la Santa Creu i Sant Pau, IIB Sant Pau, Barcelona, Spain

<sup>2</sup>Cardiovascular Program, Institut de Recerca, Hospital de la Santa Creu i Sant Pau, IIB Sant Pau, Barcelona, Spain - CiberCV, Institute of Health Carlos III, Madrid, Spain - Cardiovascular Research Chair, UAB, 08025 Barcelona, Spain

<sup>3</sup>Cardiovascular Program, Institut de Recerca, Hospital de la Santa Creu i Sant Pau, IIB Sant Pau, Barcelona, Spain - CiberCV, Institute of Health Carlos III, Madrid, Spain

† The presenting author.

**Introduction:** Diabetic patients may develop diabetic cardiomyopathy (DCM) and are at increased risk of myocardial infarction (MI). Yet, cardioprotection remains a challenge in the presence of comorbidities.

**Objectives:** We examined whether intravenous administration of atorvastatin during ongoing myocardial ischemia prevents against the deleterious effects of MI in DCM rats.

**Methods:** DCM was induced by streptozotocin (65 mg/kg) in Sprague Dawley rats ( $n = 14$ ). 5 weeks thereafter animals exhibited a DCM phenotype associated with a significant diastolic (IVRT +  $15.64 \pm 5.49$ ms  $P < 0.05$  vs. baseline) and systolic (LVEF,  $-8.63 \pm 6.71\%$   $P < 0.05$  vs. baseline) ventricular dysfunction. AMI was then induced by coronary ligation of the LAD for 45minutes. Early after ischemia (15minutes) DCM-rats received either i.v atorvastatin or vehicle. Animals were reperused and sacrificed at 24h for infarct size assessment and molecular analysis. Cardiac function was monitored by echocardiography.

**Results:** No differences were detected as per the area-at-risk between both animal groups. Atorvastatin significantly reduced infarct size expansion (35% relative reduction) as compared to vehicle ( $15.3 \pm 1.03\%$  vs.  $23.7 \pm 4.3\%$  IS/AAR;  $P < 0.05$ ). LVEF, shortening fraction, and stroke volume were better preserved in atorvastatin-treated DCM rats as compared to vehicle ( $4.62 \pm 2.55\%$  vs.  $12.4 \pm 3.16\%$ ;  $5.77 \pm 3.74\%$  vs.  $15.9 \pm 4.9\%$ ; and  $58.93 \pm 28.79\mu\text{l}$  vs.  $101.73 \pm 31.58\mu\text{l}$ , respectively;  $P < 0.05$ ). At a molecular level, atorvastatin administration was associated with a lower expression of Phosphorylated-p53 (apoptosis) and higher P-AMPK/AMP ratio (cardiac metabolism);  $P < 0.05$  vs. vehicle).

**Conclusion:** Intravenous administration of atorvastatin during MI limits infarct size and preserves cardiac function post-MI in rats with manifest DCM supporting the cardioprotective potential of this therapeutic approach despite comorbid conditions.

## Poster No. 128 Association of platelet markers with occurrence of thromboembolic and bleeding events following left atrial appendage occlusion

Errol Aarnink<sup>1</sup>†, Domenico G. Della Rocca<sup>2</sup>, Pedro L. Cepas<sup>3</sup>, Amin Polzin<sup>4</sup>, Luca Branca<sup>5</sup>, Daniel Spoon<sup>6</sup>, Xavier Freixa<sup>3</sup>, and Lucas V.A. Boersma<sup>1</sup>

<sup>1</sup>St. Antonius Hospital, Nieuwegein, Netherlands

<sup>2</sup>Texas Cardiac Arrhythmia Institute, St. David's Medical Center, Austin, Texas, USA

<sup>3</sup>Hospital Clínic de Barcelona

<sup>4</sup>Medical Faculty, Department of Internal Medicine, Division of Cardiology, Pulmonology and Vascular Medicine, Heinrich-Heine-University, Düsseldorf, Germany

<sup>5</sup>Catheterization Laboratory, Cardiothoracic Department, Spedali Civili of Brescia, Brescia, Italy

<sup>6</sup>International Heart Institute of Montana, Missoula, Montana, USA

† The presenting author.

**Background:** Patients undergoing left atrial appendage occlusion (LAAO) often are at increased risk for bleeding or thromboembolic events. In most implanting centers, baseline blood is drawn as a pre-procedural check-up. However, it is unknown what laboratory parameters have added value in this specific population. Platelet count (PLC) and mean platelet volume (MPV) may identify which patients are at risk for thromboembolic events or bleeding.

**Materials and methods:** Five implanting centers retrospectively gathered data on pre-procedural platelet markers. Composite endpoints on thromboembolic events (stroke, transient ischemic attack, device-related thrombus and systemic embolism) and bleeding (minor, major, and intracranial hemorrhage) were collected.

**Results and conclusions:** A total of 1138 patients were included ( $73 \pm 8$  years, 63% male, CHA2DS2-VASc:  $4.4 \pm 1.5$ ; HAS-BLED:  $3.2 \pm 1.1$ ). Implanted devices consisted of Watchman 2.5/FLX ( $n = 778$ ), Amplatzer Cardiac Plug/AMULET ( $n = 315$ ), or another device ( $n = 45$ ). Baseline PLC was present in 91% and MPV in 41%. PLC was significantly lower in the 97 patients developing a thromboembolic event ( $206 \pm 73$  vs.  $225 \pm 72 \times 10^9/L$ ,  $P = 0.028$ ), but no difference in MPV was observed ( $9.7 \pm 1.4$  vs.  $9.5 \pm 1.5$  fL,  $P = 0.40$ ). In another 97 patients, significant bleeding was observed during follow-up. No difference in baseline PLC was found ( $216 \pm 79$  vs.  $207 \pm 72 \times 10^9/L$ ,  $P = 0.30$ ) and a trend towards lower MPV could be observed ( $9.5 \pm 1.3$  vs.  $9.8 \pm 1.5$  fL,  $P = 0.07$ ). Patients developing bleeding more often were discharged with antiplatelet therapy, while patients developing a thromboembolic event more often received anticoagulation therapy. In conclusion, occurrence of a thromboembolic event was associated with lower baseline PLC, which may be explained by PLC being lower in more frail patients.

## Poster No. 129 Aortic events during pregnancy in women with bicuspid aortic valve and aortic dilatation. A retrospective study

Guillaume Jondeau<sup>1</sup>†, Belkadi <sup>1</sup>, Eliahou <sup>1</sup>, Arnoult <sup>1</sup>, Delhomme <sup>1</sup>, Jadoui <sup>1</sup>, Raffoul <sup>1</sup>, Bourgeois Moine<sup>1</sup>, and Milleron <sup>1</sup>

<sup>1</sup>Hopital Bichat PARIS

† The presenting author.

**Background:** The risk of aortic dissection during pregnancy remains poorly appreciated in women with BAV.

**Materials and methods:** retrospective study using data of women seen in our center with BAV and aortic dilatation, not affected by a genetic syndrome who have been pregnant. Assuming from the literature an annual aortic dilation rate of 0.2 mm at aortic root and 0.4 mm at ascending aorta, we estimated ascending aortic diameters and Z-score at the time of pregnancy.

**Results and conclusions:** We identified 47 women with BAV and aortic dilatation with an occurrence of 103 pregnancies.

Age at the time of pregnancy was 29 (26–33) years. No aortic dissection occurred during pregnancy or postpartum period. At distance of pregnancy and post partum, acute aortic dissection occurred in 2 women and elective aortic surgery was performed on 8 women, associated with aortic valve replacement for 6 of them.

Age at first visit in our center was 43 (35–56) years old. Median largest ascending aortic diameter (root or tubular aorta) was 44 (40–47) mm corresponding to a median Z-score of 4.4 (3.6–5.1).

At the time of pregnancy, estimated largest aortic diameter was 37.2 (33.4–42.3) mm,  $\geq 40$  mm in 40/103 pregnancies,  $\geq 45$  mm in 15/103, and  $\geq 50$  mm in 0/10. Estimated Z-score was 3.4 (2.3–4.7),  $\geq 2$  in 86/103 and  $\geq 4$  in 40/103 at the time of pregnancy.

**Conclusion:** In our population of women with BAV and aortic dilatation, no aortic complication occurred during 103 pregnancies, despite high incidence of aortic dilation.

## Poster No. 130 Aortic root anatomy is related to the bicuspid aortic valve phenotype

Guillaume Jondeau<sup>1†</sup>, Milleron<sup>1</sup>, Masi<sup>1</sup>, Eliahou<sup>1</sup>, Paul<sup>2</sup>, Arnoult<sup>1</sup>, Ould Ouadi<sup>1</sup>, Lansac<sup>3</sup>, Raffoul<sup>1</sup>, Pellenc<sup>1</sup>, and Ou<sup>1</sup>

<sup>1</sup>Hopital Bichat Paris

<sup>2</sup>Institut Mutualiste Montsouris

<sup>3</sup>Hopital Pitié Salpêtrière

† The presenting author.

**Background:** Bicuspid Aortic Valve (BAV) is associated with an asymmetrical (not circular) aortic root, resulting in variability in the aortic root diameter measurements.

**Materials and methods:** Aortic root asymmetry, orientation of the largest root diameter, and orientation of the valve opening were studied using CT scans of 85 BAV patients without significant aortic valve dysfunction referred for evaluation of a thoracic aortic aneurysm. BAV with fusion of the left and the right coronary cusps (L-R BAV), with or without raphe ( $n = 63$ ), were compared with BAV with fusion of the right coronary and non-coronary cusps (N-R BAV), with or without raphe ( $n = 22$ ).

**Results and conclusions:** Orientation of the valve opening differed from orientation of the largest root diameter by nearly  $75^\circ$  in both groups. The angle of the largest root diameter with the reference sagittal plane was  $64.3^\circ$  in the L-R BAV group versus  $143.1^\circ$  in the N-R BAV group ( $P < 0.0001$ ).

Therefore, using TTE parasternal long axis view, in N-R BAV, the ultrasonic beam is roughly parallel to the valve opening orientation and almost orthogonal to the maximum diameter of the root. On the contrary, in the L-R BAV, the ultrasonic beam is roughly perpendicular to the valve opening orientation and almost parallel to the maximum diameter of the root. Consequently, TTE parasternal long axis view significantly underestimates the maximum aortic root diameter in the N-R BAV, and modestly underestimates the root diameter in L-R BAV ( $-6.1 \pm 0.96$  vs.  $-2.3 \pm 0.47$  mm;  $P = 0.0008$ ).

## Poster No. 131 Family history of aortic dissection is not a risk marker in patients with a FBN1 mutation

Guillaume Jondeau<sup>1†</sup>, Tchitchinadze<sup>1</sup>, Milleron<sup>1</sup>, Eliahou<sup>1</sup>, Jouadi<sup>1</sup>, Ould Ouali<sup>1</sup>, Hanna<sup>1</sup>, Arnaud<sup>1</sup>, Ropers<sup>2</sup>, Boileau<sup>1</sup>, and Gouya<sup>1</sup>

<sup>1</sup>Hopital Bichat Paris

<sup>2</sup>Hopital Pitié Salpêtrière

† The presenting author.

**Background:** Family history of aortic dissection is considered as a risk factor for aortic dissection in patients with thoracic aortic aneurysms, but there is no supporting data published.

**Material and methods:** Retrospective study of patients coming to the French reference centre carrying a *FBN1* pathogenic variant. Patients with a family history of aortic dissection were compared with patients without a family history of aortic dissection.

**Results:** 1700 patients (age  $33.2 \pm 17$  years, 51% women) were included. 145 (8,5%) patients underwent aortic dissection at  $37.9 \pm 11.4$  years and 323 (19%) patients underwent prophylactic aortic surgery at  $33.8 \pm 13.9$  years.

481 patients had a family history of aortic dissection (28%), including 38 who dissected, and 88 who underwent surgery. 1219 had no family history of aortic dissection, including 107 who dissected, and 235 who underwent surgery.

Therefore, the personal risk for aortic dissection was similar in patients with and without a family history of aortic dissection (38/481, i.e. 7.9% vs. 107/1219, i.e. 8.8%), as was the personal risk for prophylactic aortic surgery (88/481, i.e. 18.3% vs. 235/1219, i.e. 19.3%), and the combined risk for either aortic dissection or surgery (118/481, i.e. 24.5% vs. 328/1219, i.e. 26.9%). Similar results were obtained when only familial forms were considered.

**Conclusions:** A family history of aortic dissection is not a marker of aortic disease severity in patients with *FBN1* pathogenic variant, and should not lead to earlier elective surgery.

## Poster No. 132 HTAD PATIENT PATHWAY: Strategy for diagnostic work-up of patients and families with (suspected) Heritable Thoracic Aortic Diseases (HTAD). A statement from the HTAD Working Group of VASCERN

Julie de Backer<sup>1†</sup>, Maryanne Caruana<sup>2</sup>, Marieke Baars<sup>3</sup>, Evi Bashiardes<sup>4</sup>, Kalman Benke<sup>5</sup>, Erik Bjorck<sup>6</sup>, Andrei Codreanu<sup>7</sup>, Elena de Moya Rubio<sup>8</sup>, Julia Dumfarth<sup>9</sup>, Arturo Evangelista<sup>10</sup>, Maarten Groenink<sup>11</sup>, Klaus Kallenbach<sup>7</sup>, Marlies Kempers<sup>12</sup>, Anna Keravnu<sup>4</sup>, Bart Loeys<sup>13</sup>, Laura Muino Mosquera<sup>1</sup>, Edit Nagi<sup>14</sup>, Stefano Nistri<sup>15</sup>, Guglielmina Pepe<sup>15</sup>, Jolien Roos Hesselink<sup>16</sup>, Zoltan Szabolcs<sup>17</sup>, Gisela Teixido<sup>18</sup>, Janneke Timmermans<sup>12</sup>, Ingrid Van de Laar<sup>19</sup>, Roland Van Kimmenade<sup>19</sup>, Aline Verstraeten<sup>13</sup>, Yskert Von Kodolitsch<sup>20</sup>, and Guillaume Jondeau<sup>21</sup>

<sup>1</sup>Ghent University Hospital Belgium

<sup>2</sup>Mater Dei Hospital Malta

<sup>3</sup>Academic Medical Centre Amsterdam

<sup>4</sup>The Cyprus Institute of Neurology and Genetics

<sup>5</sup>Semmelweis University Heart and Vascular Centre

<sup>6</sup>Karolinska University Hospital, Stockholm

<sup>7</sup>Centre Hospitalier de Luxembourg

<sup>8</sup>Marfan Hilfe

<sup>9</sup>Medical University Innsbruck

<sup>10</sup>Hospital Universitari Vall d'Hebron

<sup>11</sup>Academic Medical Centre, Amsterdam

<sup>12</sup>Radboud University Medical Center, Nijmegen

<sup>13</sup>University Hospital of Antwerp, Antwerp

<sup>14</sup>Karolinska University Hospital, Stockholm

<sup>15</sup>Careggi Hospital, University of Florence

<sup>16</sup>Erasmus Medical Center, Rotterdam

<sup>17</sup>Semmelweis University Heart and Vascular Centre, Budapest

<sup>18</sup>Hospital Universitari Vall d'Hebron, Barcelona

<sup>19</sup>Erasmus Medical Center, Rotterdam

<sup>20</sup>University Hospital Hamburg-Eppendorf University Heart Centre, Hamburg

<sup>21</sup>Hôpital Bichat-Claude Bernard, Paris

† The presenting author.

**Background:** Timely diagnosis of patients with Heritable Thoracic Aortic Diseases (HTAD) is essential to avoid (often fatal) aortic dissection. Experts of the HTAD rare disease working group of the European Reference Network of Rare Vascular diseases (vascern) aimed to propose a pathway to: (1) improve patient care by diminishing time to diagnosis; (2) facilitate the establishment of a correct diagnosis, using molecular genetics when possible, which may lead to a more personalized treatment; (3) exclude the diagnosis in unaffected persons (family screening); (4) avoid overuse of financial and personnel resources.

**Material and methods:** This pathway is a consensus at expert level. It was generated based on available guidelines when possible. Discussion items were listed and, where necessary, items were included in a questionnaire sent out for voting and discussion over monthly teleconference calls.

**Results and conclusions:** Pathway Elements include Thoracic aortic aneurysm – and dissection, Bicuspid Aortic Valve, Medium-sized artery aneurysms/dissection, Extravascular features and Family History. Recommendations for the evaluation of patients and family members are provided.

This pathway is advised to implement standardisation of diagnostic workup and follow-up of patients with suspected HTAD and the screening of their relatives and it focuses on patients with heritable aortic diseases whether syndromic or not. It is subject to adjustment with better recognition of new entities, and with the technical progress and increased availability of genetic testing.

## Poster No. 133 Local TGF-beta sequestration by fibrillin-1 regulates vascular wall homeostasis in the thoracic aorta

Julie de Backer<sup>1†</sup>, Violette de Leeuw<sup>1</sup>, Mathias Van Impe<sup>1</sup>, Marine Vanhomwegen<sup>1</sup>, Gerlinde Logghe<sup>1</sup>, Margie Oblinado<sup>2</sup>, Marco Stampanoni<sup>2</sup>, Patrick Segers<sup>1</sup>, Laura Muino Mosquera<sup>1</sup>, Lynn Sakai<sup>3</sup>, and Patrick Sips<sup>1</sup>

<sup>1</sup>Ghent University Hospital Belgium

<sup>2</sup>Paul Scherer Institute

<sup>3</sup>Oregon Health & Science University

† The presenting author.

**Introduction:** Marfan syndrome (MFS) is caused by a defect in fibrillin-1, which binds TGF-beta via interaction with latent TGF-beta binding proteins (LTBPs). The role of TGF-beta in MFS is controversial.

**Objectives:** use dedicated mouse models for MFS, with defects interfering with TGF-beta binding and function, to gain insights into the role of TGF-beta signaling in aneurysm formation and dissection.

**Material & methods:** Mice lacking the binding site for LTBPs (*Fbn1*<sup>H1Δ/+</sup> and *Fbn1*<sup>H1Δ/H1Δ</sup>), mice with a truncated fibrillin-1 (*Fbn1*<sup>GT-8/+</sup>), and mice with a combination (*Fbn1*<sup>GT-8/H1Δ</sup>) were subjected to cardiac ultrasound and ex vivo synchrotron X-ray imaging.

**Results:** Only *Fbn1*<sup>GT-8/H1Δ</sup> mice showed increased mortality (aortic rupture) starting at 4–5 months, whereas all other mice had a normal life span. Aortic root dilatation occurred both in *Fbn1*<sup>GT-8/+</sup> and *Fbn1*<sup>GT-8/H1Δ</sup> mice at 6 months, but not in *Fbn1*<sup>H1Δ/+</sup> or *Fbn1*<sup>H1Δ/H1Δ</sup> mice. Significant elastin fragmentation was observed in the thoracic aortic wall of *Fbn1*<sup>GT-8/+</sup> mice, and to a larger extent in *Fbn1*<sup>GT-8/H1Δ</sup> mice. Surprisingly, localized elastin fragmentation was also found in the ascending aorta of *Fbn1*<sup>H1Δ/+</sup> and *Fbn1*<sup>H1Δ/H1Δ</sup> mice, despite a lack of aortic aneurysm formation. Moreover, *Fbn1*<sup>H1Δ/H1Δ</sup> mice displayed more severe aortic wall damage.

**Conclusion:** Our data suggest that loss of LTBP binding to fibrillin-1 leads to the development of localized aortic microdissections in the absence of aortic aneurysm, and exacerbates the aortic wall morphology abnormalities in mice with truncated fibrillin-1. We therefore hypothesize that local TGF-beta sequestration is required to maintain aortic homeostasis.

## Poster No. 134 Zebrafish as a tool to study cardiovascular effects caused by fibrillin impairment

Julie de Backer<sup>1</sup>†, Karo de Rycke<sup>1</sup>, Lisa Caboor<sup>1</sup>, Petra Vermassen<sup>1</sup>, and Patrick Sips<sup>1</sup>

<sup>1</sup>Ghent University Hospital Belgium

† The presenting author.

**Introduction:** Marfan syndrome (MFS) is the most common type of fibrillinopathy with a high predisposition to develop TAAD. A thorough understanding of the underlying mechanisms is still lacking, indicating a particular need for more flexible *in vivo* models to address this knowledge gap.

**Objectives:** We aimed to generate a relevant zebrafish model to gain insight into the molecular mechanisms relating fibrillin defects to the cardiovascular system.

**Methods:** The CRISPR/Cas9 system was used to systematically target the three different fibrillin genes (*fbn1*, *fbn2a* and *fbn2b*) in Tg(kdrl:GFP) reporter zebrafish. Time-lapse fluorescent microscopy was used to evaluate the cardiovascular phenotype.

**Results:** zebrafish lacking *fbn1* and/or *fbn2a* do not show any cardiovascular phenotype during early-stage development. On the other hand, approximately 50% of homozygous *fbn2b* mutant (*fbn2b*<sup>-/-</sup>) zebrafish embryo's show a severe phenotype characterized by endocardial detachment, leading to vascular embolism and premature mortality at 7–9 dpf. Interestingly, the remaining *fbn2b*<sup>-/-</sup> zebrafish survive until adulthood, but during larval stages already develop a dilation of the bulbus arteriosus. The caudal vein of all *fbn2b*<sup>-/-</sup> embryos also develops abnormally as a cavernous structure lacking vessel integrity. This phenotype is resolved in embryos retaining normal blood flow and aggravated upon pharmacological inhibition of blood flow during development.

**Conclusion:** These data indicate that *fbn2b*<sup>-/-</sup> zebrafish model recapitulates cardiovascular complications, and can be considered as a relevant model to study the mechanisms underlying MFS pathogenesis. Our preliminary data suggest that there is an interplay between fibrillin deficiency and biomechanical signaling in the regulation of cardiovascular development.



## Poster No. 135 Stroke risk of patients with new AF during ACS may depend on onset and duration

Wilbert Bor<sup>1†</sup>, J. Azzahafi<sup>1</sup>, N. di Maio<sup>1</sup>, N.M.R. Van Der Sangen<sup>2</sup>, S. Rayhi<sup>1</sup>, J. Peper<sup>1</sup>, and J.M. Ten Berg<sup>1</sup>

<sup>1</sup>St. Antonius Hospital, Nieuwegein, Netherlands

<sup>2</sup>AmsterdamUMC

† The presenting author.

**Background/rationale:** Newly diagnosed atrial fibrillation(AF) during acute coronary syndrome(ACS) is associated with worse outcomes. In this study we evaluated the associated stroke risk of newly diagnosed AF in ACS patients according to the onset and duration of the episode.

**Results:** Amongst 4433 patients presenting with ACS, 439(9.9%) had newly diagnosed AF and 396(8.9%) had known AF. Of the new AF cases, 27.5% occurred post-CABG. The onset was within 24 hours of ACS presentation in 70.1% of non-CABG cases. The new AF episodes lasted longer than 24 hours in 42.9% of the non-CABG cases. At discharge 54.0% of patients with new AF was treated with OAC, in contrast to 89.2% with known AF.

The incidence of ischemic stroke at one year was 1.2% in patients without AF, 1.0% with known AF, and 3.6% with new AF ( $P < 0.001$ ). Within patients developing AF post-CABG, the incidence was 4/120(3.3%). Within non-CABG patients, the incidence of ischemic stroke for patients with onset within 24 hours of presentation was 0/133(0.0%) for patients with an episode lasting < 24 hours, and 6/109(5.5%) for patients with an episode lasting > 24 hours. For patients with new AF onset after 24 hours the incidence was 5/120(5.5%) for patients with an episode lasting < 24 hours, and 5/92(5.4%) for patients with an episode lasting > 24 hours.

**Conclusion:** Patients with newly diagnosed AF during ACS seem undertreated with OAC. The associated risk of ischemic stroke with new AF during ACS may be lower in episodes that terminate within the first 24 hours of presentation.

## Poster No. 137 A very evident pulmonary thrombus

Catarina Gonçalves Coelho<sup>1†</sup>, Mariana Saraiva<sup>1</sup>, Joana Luís<sup>2</sup>, Sofia Lázaro Mendes<sup>1</sup>, Maria Luz Pitta<sup>1</sup>, and Vítor Paulo Martins<sup>1</sup>

<sup>1</sup>Hospital Distrital De Santarém, E.P.E.

<sup>2</sup>Hospital Vila Franca Xira

† The presenting author.

**Clinical case:** Female patient, 78 years-old, that complained of epigastric pain and intense fatigue for a week. While waiting in the urgency department, she became hypotensive, with refractory shock. Electrocardiogram showed sinus rhythm, 90 bpm, *de novo* right bundle block and infraST in the right precordial leads. The echocardiogram showed a dilated right ventricle (ratio RV/LV > 1), with depressed function and major tricuspid regurgitation, RV/RA gradient of at least 55 mmHg. Left ventricle presented "D-shape", preserved function and no segmental kinetic changes. The pulmonary artery was dilated and a serpentine mass was visible, protruding through the pulmonary valve; similar masses were also visible in its branches. The diagnosis of pulmonary embolism (PE) was assumed and fibrinolysis was started, given there were no contra-indications.

One year before, she had an intermediate-risk PE in the context of COVID-19, with a similar echocardiographic presentation. She recovered RV function in the following months and stopped anticoagulation 3 months after that episode.

**Discussion:** PE can present with varying degrees of severity. Bedside echocardiography can be of major help in its diagnosis, especially in critical patients. The visualization of a thrombus in the pulmonary artery is rare, particularly in transthoracic echocardiogram. Echocardiogram is also useful for risk stratification and prognostic evaluation. This patient developed obstructive shock due to massive PE and the fibrinolytic treatment was paramount for her survival. A good echocardiogram helped in the differential diagnosis and enabled the Cardiologist to assist the patient in the best way.

## Poster No. 138 Thromboembolic and bleeding risks due to perioperative stop of antithrombotic treatment in non-cardiac surgery - a single center experience

Mariana Ferreira Carvalho<sup>1</sup>†, Carolina Gonçalves<sup>1</sup>, Margarida Cabral<sup>1</sup>, Sara Lopes Fernandes<sup>1</sup>, Rita Ribeiro Carvalho<sup>1</sup>, Jorge Guardado<sup>1</sup>, Alexandre Antunes<sup>1</sup>, and João Morais<sup>1</sup>

<sup>1</sup>Hospital de Leiria

† The presenting author.

**Introduction:** Discontinuation of antiplatelet therapy is essential for patients in the perioperative period submitted to high bleeding risk non-cardiac surgery (NCS). Similarly, oral anticoagulants should be interrupted before high risk surgical procedures, excluding patients with mechanical heart valves together with any thromboembolic risk factors. Interruption of this medication may increase thromboembolic events, however, their frequency still remains unclear.

**Purpose:** We aim to evaluate the thromboembolic and bleeding events due to perioperative cessation of antithrombotic treatment in non-cardiac surgery approach in the population in our center.

**Methods:** A single-center retrospective observational analysis between January 2015 and August 2022 evaluated 356 patients. Eligibility criteria included: interruption of antithrombotic or anticoagulant therapy, high cardiovascular risk with previous cardiovascular disease diagnosis, planned major non-cardiac surgery, and perioperative follow-up at our center.

**Results:** A total 356 patients undergoing NCS were eligible in the cohort: 91.2% of patients with high bleeding risk surgery and 94.5% with mild-moderate thrombotic risk.

All cause death occurred in 4 patients (1.1%), thrombotic events in 4 patients (1.1%) and major bleeding events in 11 patients (3.1%). Hemoglobin level ( $P=0.004$ ), duration of surgery ( $P<0.001$ ) and age ( $P=0.004$ ) were significantly related to the risk of bleeding events. Mean duration of interruption of antithrombotic therapy was of  $8 \pm 2$  days.

**Conclusions:** Although cessation of antithrombotic therapy, hemorrhagic events are more associated than thrombotic ones in patients with previous cardiac disease that underwent elective NCS. The factors with significant association with bleeding complications after NCS were age, hemoglobin level, and duration of surgery.

## Poster No. 139 Direct Oral Anticoagulant Use in the Treatment of Venous Thromboembolism Associated with Cancer

Francisca Carmo<sup>1†</sup>, Joana Martins Cabral<sup>1</sup>, and Luísa Magalhães<sup>1</sup>

<sup>1</sup>Centro Hospitalar Vila Nova De Gaia / Espinho E.P.E.

† The presenting author.

Venous thromboembolism (VTE) is a common cause of death and complications in patients with cancer. Choosing an anticoagulant is challenging because these patients are at high risk of recurrent VTE and bleeding. Major guidelines recommended the use of low-molecular-weight heparin (LMWH), but recent studies recommend consideration of direct anticoagulants (DOACs) in selected patients. However, their clinical use is limited by the increased risk of bleeding and interaction with other drugs.

Retrospective study, including patients followed since 2015 in VTE consultation, with cancer-associated VTE. Patients with an ECOG Performance Status Scale of 4 and with contraindications for anticoagulation were excluded. We reported the incidence of recurrent VTE and haemorrhage within the first year after anticoagulation. In this study, we compared the efficacy and safety of the use of DOACs versus LMWH in patients with cancer-associated VTE.

91 patients were included, 55% male, median age of 70 years and most frequent ECOG Performance Status Scale of 0 (44%). 65% of the patients were treated with DOACs. The most common cancers included: colorectal (26%), genitourinary (25%), haematological (10%) and upper gastrointestinal (9%). Were reported 6 recurrent VTE events (4 pulmonary embolisms, 2 deep vein thrombosis) and 6 minor bleeding events, without any major or fatal event. The occurrence of recurrent thromboembolic events or bleeding was not significantly different between patients treated with LMWH or DOACs.

In this real-world observational study, we confirm the efficacy and safety of the use of DOACs in the treatment of VTE associated with cancer in selected patients.

## Poster No. 140 Major cardiovascular events in high cardiovascular risk patients submitted to non-cardiac surgery and its clinical determinants

Mariana Ferreira Carvalho<sup>1</sup>†, Carolina Gonçalves<sup>1</sup>, Margarida Cabral<sup>1</sup>, Sara Lopes Fernandes<sup>1</sup>, Rita Ribeiro Carvalho<sup>1</sup>, Jorge Guardado<sup>1</sup>, Alexandre Antunes<sup>1</sup>, and João Morais<sup>1</sup>

<sup>1</sup>Hospital de Leiria

† The presenting author.

**Introduction:** Pre-operative cardiovascular assessment of patients with high ischaemic risk is fundamental to give the best perioperative management. Morbi-mortality is mainly due to patient-related risk and surgery-related risk. However, the risk scores are very heterogeneous and derived from non-cardiac populations, making them less accurate.

**Purpose:** The study aims to characterize a cohort of patients with high ischemic risk who underwent non-cardiac surgery and to identify predictors of perioperative major adverse cardiovascular events (MACE) defined by urgent revascularization, myocardial infarction (MI) and/or cardiac death, thromboembolism and acute limb ischemia.

**Methods:** A single-center retrospective observational analysis between January 2015 and August 2022 evaluated 356 patients. Eligibility criteria included: patients with high cardiovascular risk with previous diagnosis of cardiac disease, planned to be submitted to high-risk non-cardiac surgery, and perioperative follow-up at our center.

**Results:** A total of 356 patients with high cardiovascular risk undergoing NCS were eligible in the cohort. Perioperative MACE occurred in 4.5% of the patients. Predictors of MACE during perioperative period were older age ( $P < 0.001$ ), chronic pulmonary disease ( $P = 0.031$ ), coronary artery disease (CAD) ( $P = 0.011$ ) and valvular heart disease ( $P = 0.039$ ). Diabetes and hypertension exhibited a neutral impact in these patients.

**Conclusions:** These results highlight the increased thrombotic risk inherent to major surgery in patients with high risk cardiovascular disease. Older age, previous diagnosis of chronic pulmonary disease, coronary artery disease, and valvular heart disease are predictors of MACE in patients submitted to non-cardiac surgery, providing incremental value for predicting these events. More studies are needed to further characterize this population.x

## Poster No. 142 An unusual heart-kidney connection: from diagnosis to staging of renal cell carcinoma

Jéni Quintal<sup>1</sup>†, Paula Lopes<sup>1</sup>, Joana Póvoa<sup>1</sup>, Aissato Cassama<sup>1</sup>, Ana Cristina Diogo<sup>1</sup>, and Vanessa Pereira<sup>1</sup>

<sup>1</sup>Centro Hospitalar de Setúbal, E.P.E.

† The presenting author.

A 58-years-old man is admitted in emergency department with complaints of 2-days le flank pain and hematuria. When questioned, he mentions 6-months bilateral low back pain. His medical history was relevant for tobacco consumption (80 pack-year) and acute myocardial infarction in 2011. During abdominal examination, a painless 7 cm mass is detected in the left abdominal flank. Blood tests were remarkable for macrocytic anemia, increased D-dimers and serum calcium levels and leukocytosis. A thoracoabdominal-pelvic CT was performed to exclude advanced neoplasia. A 15×13 cm heterogeneous renal lesion involving the lower half of the left kidney was shown. This lesion extended through the renal vein and suprarenal inferior vena cava (IVC) to the right atrium. Bilateral pulmonary thromboembolism and metastatic lesions in the liver, left adrenal gland, latero-aortic ganglia and lung parenchyma were also detected. A thrombus was confirmed in the IVC with extension to the Eustachian valve by echocardiography. Metastatic renal carcinoma was assumed and enoxaparin was started. A renal biopsy identified clear cell renal carcinoma (CCRC). Embolization of the left renal artery was performed and Palliative Care follow-up was started after multidisciplinary team discussion. Renal cell carcinoma accounts for 2% of all tumors in adulthood with its classic symptomatic triad (flank pain, hematuria, and palpable abdominal mass) occurring only 9% of cases, as does endovascular dissemination from the renal vein and IVC. It is associated with a median survival of 5 months. We emphasize the importance of complete clinical examination and the recognition of poor prognosis predictors of CRCL.

## Clinical Case 01—Cardioembolic stroke with a twist: a case of left ventricular thrombus

Adriana Vazão<sup>1\*†</sup>, Carolina Miguel Gonçalves<sup>2</sup>, Rui Filipe Ribeiro<sup>3</sup>, Ana Catarina Domingues<sup>3</sup>, Margarida Cerqueira<sup>3</sup>, João Filipe Carvalho<sup>2</sup>, Maria de Jesus Banz<sup>2,3</sup>, and João Morais<sup>2</sup>

<sup>1</sup>1st year Cardiology Resident at Centro Hospitalar de Leiria

<sup>2</sup>Cardiology Department, Centro Hospitalar de Leiria

<sup>3</sup>Internal Medicine Department, Centro Hospitalar de Leiria

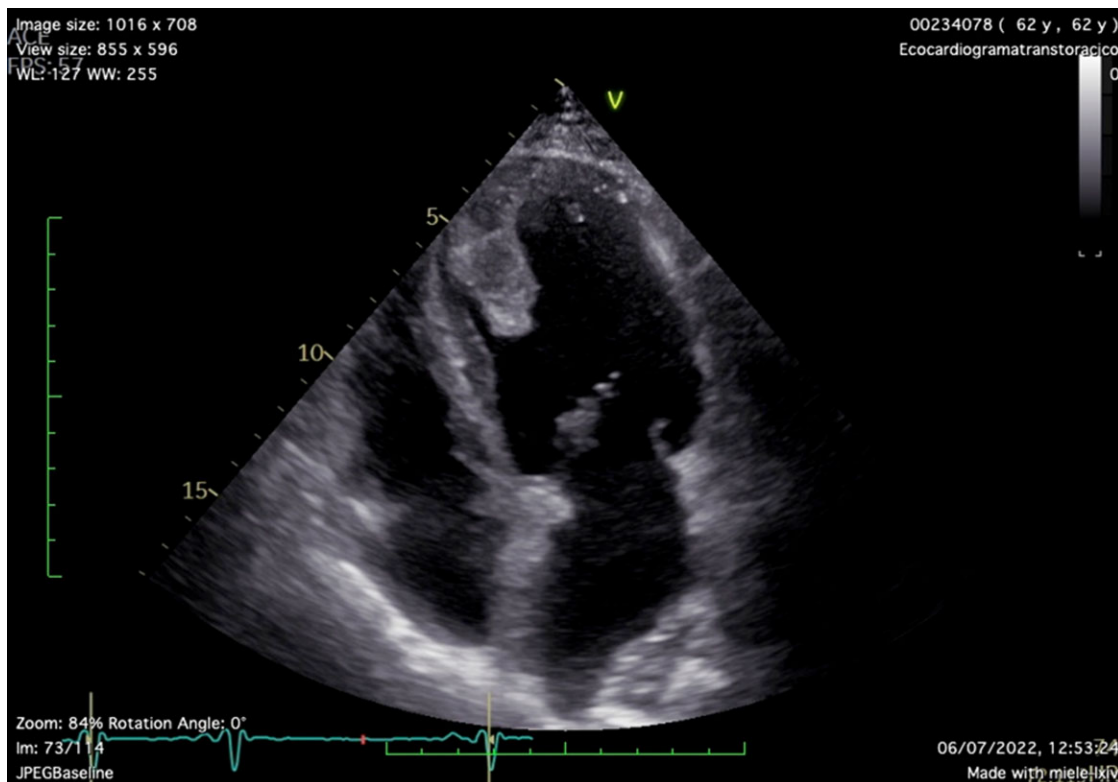
\*Corresponding author. Email: [adrianafvazao@gmail.com](mailto:adrianafvazao@gmail.com)

† The presenting author is less than 40 years old and in clinical training.

**Presentation and diagnosis:** A 62-years old male was brought to the emergency department after being found unconscious, lying on his left side. He was last seen 1 week before. Past medical history revealed ischemic cardiomyopathy with reduced ejection fraction of 35% after ST-segment elevation myocardial infarction 3 months before, subject to coronary angioplasty of 2 vessels (left anterior descending artery with drug-eluting stent and circumflex artery with balloon angioplasty). He had poor therapeutic compliance with missing cardiology appointments. On examination, he was hypothermic and hemodynamically unstable with signs of hypoperfusion. He was admitted for septic shock with origin in a decubitus ulcer on his left-hand dorsum. Head CT-scan revealed sub-acute ischemic stroke in the right middle cerebral artery territory. He started fluid therapy, vasopressors and large spectrum antibiotics with favorable clinical evolution and no heart failure symptoms but remained febrile. Meanwhile, *Proteus hauseri* had grown in blood cultures. An echocardiography was performed excluding infectious endocarditis and revealing a large apical thrombus on the left ventricle.

**Management:** Therapeutic anticoagulation with enoxaparin was initiated and antibiotic was de-escalated according to the antibiogram. Later on, anticoagulation was switched to warfarin (target INR~2.0–3.0). When clinically stable, was discharged home with anticoagulation and clopidogrel, with an echocardiography scheduled after 3 months.

**Learning points:** Left ventricular thrombus is a rare complication of ischemic cardiomyopathy with high risk of adverse outcomes, including ischemic stroke and death. Vitamin K antagonists are usually preferred to direct oral anticoagulants in the management of these patients, but further research is needed.



**Figure 1** Left ventricular thrombus (red arrow) in the apical 4-chamber view of transthoracic echocardiography.

## Clinical Case 03—Coronary subclavian steal syndrome: an unusual cause of acute myocardial infarction

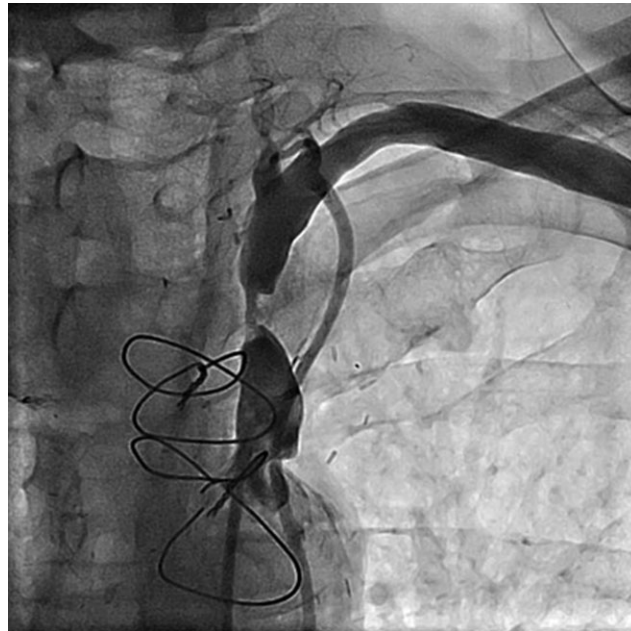
Ana Isabel Pinho<sup>1†</sup>, Miguel Martins de Carvalho<sup>1</sup>, Cátia Oliveira<sup>1</sup>, Luís Daniel Santos<sup>1</sup>, Tânia Proença<sup>1</sup>, Ricardo Alves Pinto<sup>1</sup>, Ana Filipa Amador<sup>1</sup>, Catarina Martins da Costa<sup>1</sup>, João Calvão<sup>1</sup>, André Cabrita<sup>1</sup>, Catarina Marques<sup>1</sup>, Leandro Nóbrega<sup>2</sup>, Lara Dias<sup>2</sup>, Roberto Pinto<sup>1</sup>, Rui André Rodrigues<sup>1</sup>, and Filipe Macedo<sup>1</sup>

<sup>1</sup>Department of Cardiology, São João University Hospital Centre, Porto, Portugal

<sup>2</sup>Department of Vascular Surgery, São João University Hospital Centre, Porto, Portugal

† The presenting author, Ana Isabel Pinho, is less than 40 years old and she is in clinical training (Cardiology resident). There are no conflicts of interest in the presentation of this case.

A 69-year-old male presented with typical angina while showering. He had history of CABG in 2008 (left internal mammary arterial [LIMA] to the first marginal and intermediate arteries and RIMA to the LAD artery), with preserved biventricular systolic function. On physical examination, an upper-arm systolic blood pressure differential >20mmHg and a decreased pulse amplitude on the left side was found. ECG revealed sinus tachycardia with RBBB, ST-segment depression and inverted T-waves in the lateral and inferior leads. Troponin and BNP levels were elevated. Echocardiogram showed reduced left ventricular ejection fraction (22%) and de novo akinesia of the inferior and posterior walls. The diagnosis of non-ST-segment elevation myocardial infarction was assumed. Coronary angiography revealed patent bypass grafts without disease and a 90% stenosis of the left subclavian artery (LSA) proximal to the ostia of the LIMA, with retrograde flow 'stealing' the myocardial blood supply. Ultrasound scan detected systolic reversal of flow in the left vertebral artery, suggesting subclavian-vertebral steal phenomenon. CT-angiography revealed a 14-mm stenosis with a useful lumen of 2 mm in the LSA. A percutaneous balloon angioplasty with stenting of the LSA was performed by the Vascular team, restoring the normal blood supply. Coronary subclavian steal syndrome can manifest as myocardial infarction or heart failure, due to functional LIMA graft failure by inadequate blood supply to the myocardium. Anamnesis and physical examination are fundamental in order not to miss the diagnosis. Subclavian angiography is the gold standard to confirm the diagnosis and can be performed during coronary angiography. Revascularization of the LSA is the definitive treatment.



**Figure 1** Coronary angiography revealed chronic occluded native coronary vessels with patency and no significant disease of the bypass grafts, and high grade (90%) left subclavian artery (LSA) stenosis proximal to the ostia of the LIMA, conditioning the blood flow to the left upper limb and 'stealing' the myocardial blood supply because of retrograde flow in the LIMA graft.



## Clinical Case 04—Percutaneous patent foramen ovale closure after a thrombotic storm: a case report

André Alexandre<sup>1,2\*</sup>†, David Sá Couto<sup>1,2</sup>, André Luz<sup>1,2,3</sup>, António Marinho<sup>1,2</sup>, Filomena Oliveira<sup>1,2</sup>, João Silveira<sup>1,2</sup>, and Severo Torres<sup>1,2</sup>

<sup>1</sup>Centro Hospitalar Universitário do Porto, Porto, Portugal

<sup>2</sup>ICBAS – School of Medicine and Biomedical Sciences, University of Porto, Porto, Portugal

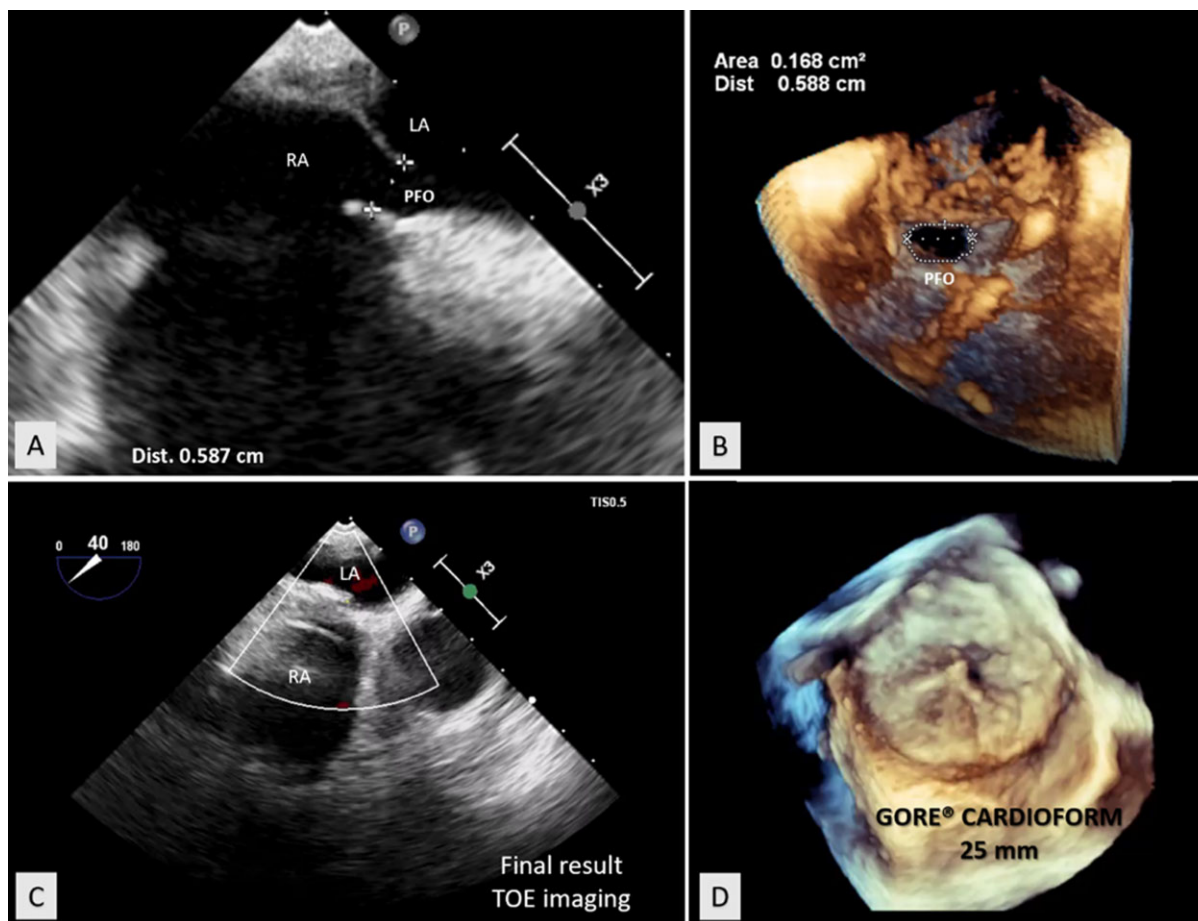
<sup>3</sup>Cardiovascular Research Group at UMIB, ICBAS, University of Porto, Porto, Portugal

\*Corresponding author. Largo do Prof. Abel Salazar, 4099-001, Porto, Portugal, E-mails: [andrealexandre\\_1@msn.com](mailto:andrealexandre_1@msn.com); [u13404@chporto.min-saude.pt](mailto:u13404@chporto.min-saude.pt)

† The corresponding author is a 28-year-old cardiology resident in the above-mentioned institution.

A 38-year-old woman with a 32-week gestation was admitted in the emergency department complaining of acute lower limb pain. She had history of smoking, 1 voluntary interruption of pregnancy, 1 miscarriage at age 34, and family history of antiphospholipid syndrome (APS). At admission, bilateral acute limb ischemia and foetal death were diagnosed. CT angiography revealed acute bilateral thrombotic occlusion of the iliac arteries, left renal artery thrombosis with extension to the distal abdominal aorta, deep vein thrombosis (DVT) of the left iliac vein and distal inferior vena cava, and bilateral pulmonary embolism. The patient started on anticoagulation and underwent caesarean section and axillofemoral bypass. Plasmapheresis and rituximab were attempted due to high clinical suspicion of catastrophic APS. Immunological and neoplastic study were repeatedly negative. The patient was ultimately discharged on vitamin K antagonist (VKA). Further investigation revealed a patent foramen ovale (PFO) with spontaneous right-to-left shunt. Given the risk of paradoxical embolism in this thrombophilic setting of unclear cause, she was referred for percutaneous PFO closure using a GORE® CARDIOFORM 25 mm device. Post-procedure maintenance of antithrombotic therapy with VKA was decided by a multidisciplinary team. Since the event, she had no recurrence of thromboembolic events and continues under investigation in autoimmune disease outpatient clinic. Although simultaneous arterial and venous thrombosis cannot be ruled out, we suspect of left paradoxical embolism following DVT. PFO closure in this setting might be useful for reduction of paradoxical arterial embolism risk on top of systemic anticoagulation.

**Keywords:** Thrombotic storm • Thrombophilia • Hypercoagulability setting • Patent foramen ovale • Paradoxical embolism • Percutaneous patent foramen ovale closure



**Figure 1** Panels A and B show the presence of patent foramen ovale (PFO). Panels C and D show the final result after percutaneous PFO closure using a GORE® CARDIOFORM 25 mm device.

## Clinical Case 06—A fatal dance: a case report of a pulmonary embolism with mobile right ventricular thrombus

Carolina Miguel Gonçalves<sup>1\*†</sup>, Mariana Carvalho<sup>1</sup>, Adriana Vazão<sup>1</sup>, Sara Fernandes<sup>1</sup>, Margarida Cabral<sup>1</sup>, Rita Carvalho<sup>1</sup>, Hélia Martins<sup>1</sup>, Fátima Saraiva<sup>1</sup>, and João Morais<sup>2</sup>

<sup>1</sup>Centro Hospitalar de Leiria

<sup>2</sup>ciTechCare – Center for Innovative Care and Health Technology, Polytechnique of Leiria

\*Email address: [carolinagoncalves9@gmail.com](mailto:carolinagoncalves9@gmail.com)

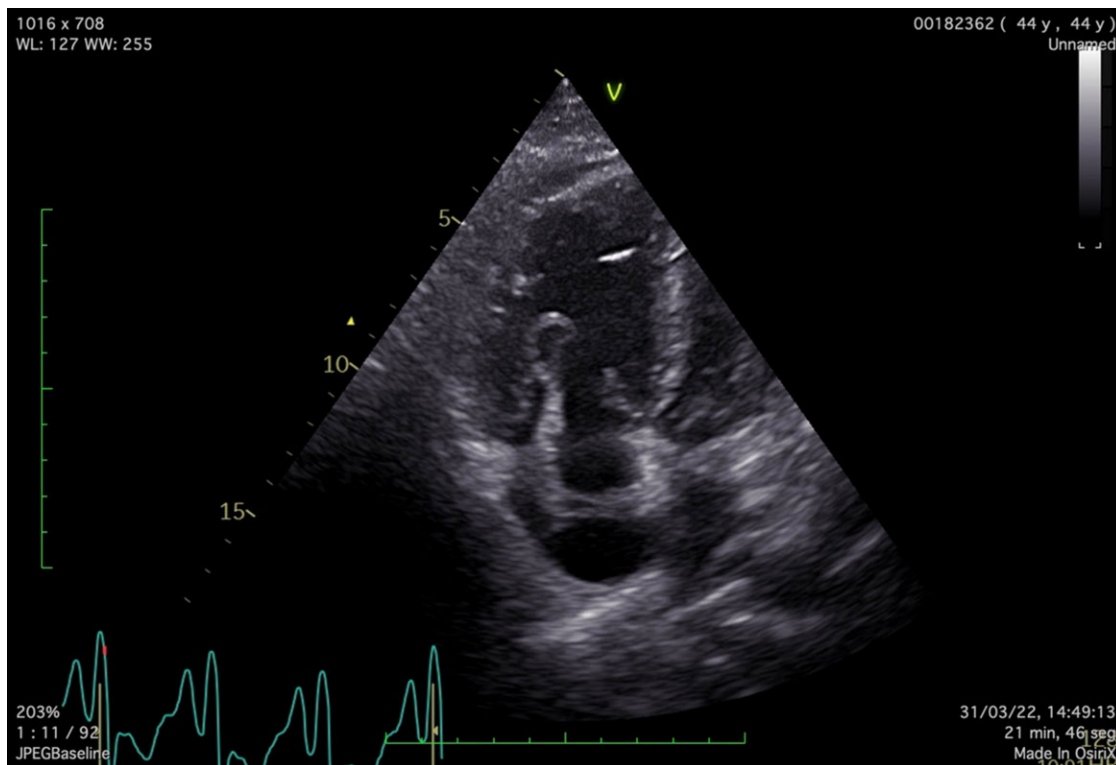
† The presenting author is less than 40 years old and in clinical training..

**Presentation:** We report a case of a 44-year-old woman with past medical history of dyslipidemia under atorvastatin, overweight and depression, that presented to the emergency department with a 1-month history of dyspnea. On physical examination, blood pressure was within normal range, however she was hypoxemic, needing oxygen via nasal cannula, and tachycardic. Pulmonary auscultation revealed basal crackles. Blood workup showed discrete leukocytosis, increased C-reactive protein, mild hypertransaminasemia and increased troponin and NT-proBNP levels. An EKG revealed sinus tachycardia with 123 beats per minute. A D-shaped left ventricle, an enlarged right ventricle and right heart mobile thrombus were observed in a transthoracic echocardiogram.

**Diagnosis:** Scoring 2 points on simplified Wells' Score and with a visible mobile right ventricular thrombus, pulmonary embolism was suspected and further confirmed by computed tomographic pulmonary angiography. Management: In the absence of hemodynamic instability this case fulfils criteria for intermediate-high risk pulmonary embolism. Therefore, anticoagulation with enoxaparin was started under strict electrocardiographic monitoring. Unfortunately, a day later the patient had a sudden cardiac arrest in asystole, with no recuperation after prolonged advanced life support and administration of rescue thrombolysis (alteplase 50mg).

### Learning points:

- The real frequency of right ventricular thrombi in the setting of pulmonary embolism is uncertain, however it appears to be rare.
- According to several observational studies, it is associated with hemodynamic instability at presentation and with worse prognosis.
- Optimal management remains controversial. Thrombolysis or surgical embolectomy may be considered though further research is needed to establish the most appropriated treatment.



**Figure 1** Mobile right ventricular thrombus in transthoracic echocardiography—4- chamber view focusing the right ventricle.

## Clinical Case 07—Acute myocardial infarction due to paradoxical embolism: a difficult and underrecognized diagnosis

Cátia Oliveira†, Tânia Proença, Ana Pinho, Luís Santos, André Cabrita, Catarina Marques, Ana Filipa Amador, João Calvão, Catarina Costa, Miguel Carvalho, Ricardo Pinto, Ana Lebreiro, and Filipe Macedo

Department of Cardiology, São João University Hospital Centre, Porto, Portugal

† The presenting author, Cátia Priscila Santos Oliveira ([catiapsoliveira8@gmail.com](mailto:catiapsoliveira8@gmail.com)), is less than 40 years old and in clinical training (Cardiology resident).

Paradoxical embolism occurs when embolic material crosses from the venous to the arterial circulation through an intracardiac defect, such as a patent foramen ovale (PFO). Although rare, it may be a cause of acute coronary syndrome (ACS), requiring a high degree of clinical suspicion for diagnosis.

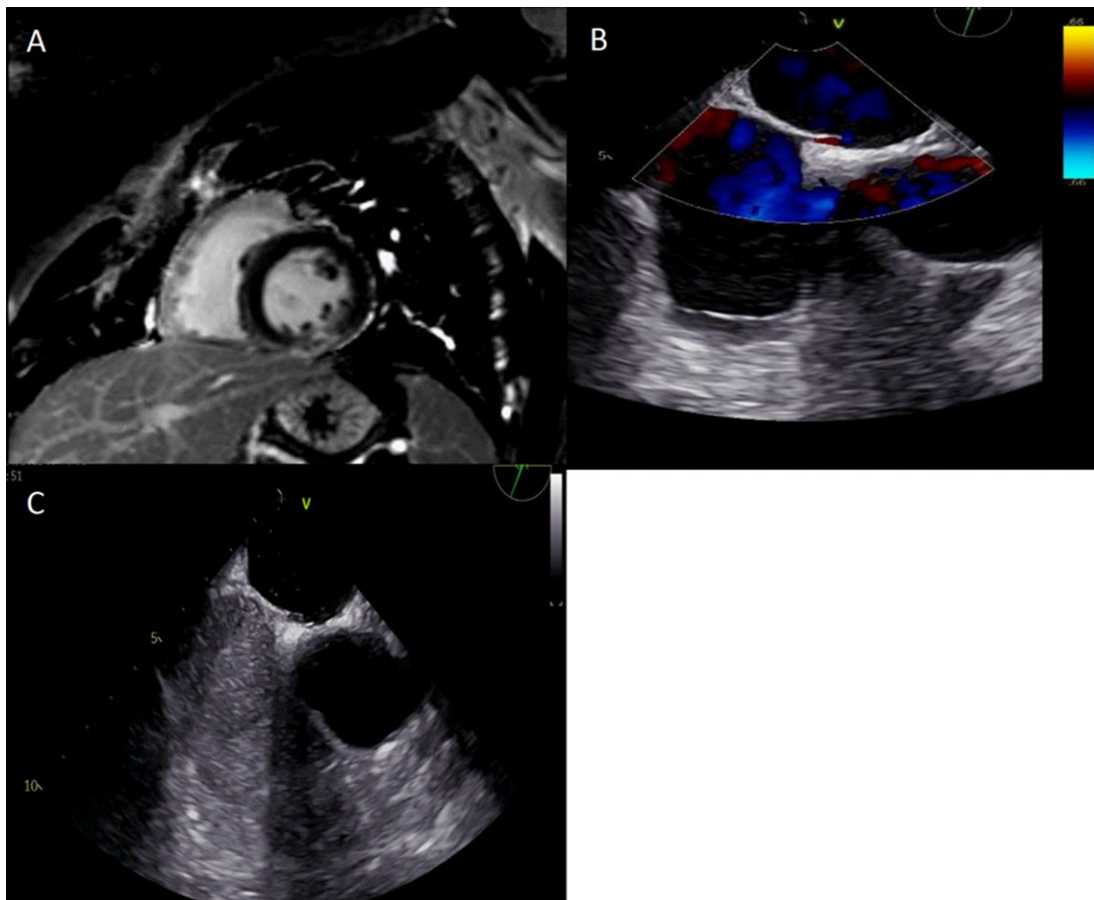
We report a case of a 30-year-old man presenting in the emergency department with prolonged atypical left thoracic pain, electrocardiogram showing sinus rhythm with 1 mm ST-elevation in the inferior leads, and high-sensitivity troponin I elevation (maximum of 20 682 ng/L). The patient underwent emergent coronary angiography which showed apparently normal coronary arteries.

The patient was then submitted to cardiac magnetic resonance that showed a recent transmural infarction of the inferior wall. (*Figure 1*). A right coronary branch was assumed as the culprit.

Additional study was made, with trans-esophageal echocardiogram (TEE) with agitated saline test revealing a PFO with spontaneous right-left shunt (*Figure 1*). No intra-cavitary thrombus or other embolic source were found and the patient remained in sinus rhythm. Thrombophilia and auto-immune panel were negative.

A presumptive diagnosis of paradoxical coronary emboli was made. PFO closure was performed with the Noblestich® system (a suture-based system).

In conclusion, although paradoxical coronary artery embolism is an established cause of ACS, it requires a high degree of clinical suspicion for diagnosis. Recognition of this condition is important as it influences patients' management and prognosis and percutaneous device closure of the PFO should be considered to prevent future embolic events.



**Figure 1** A: Short axis cardiac resonance showing transmural late gadolinium enhancement in the inferior wall. B and C: Trans-esophageal echocardiography with Doppler signal (B) and agitated saline test (C) showing the PFO with shunting.

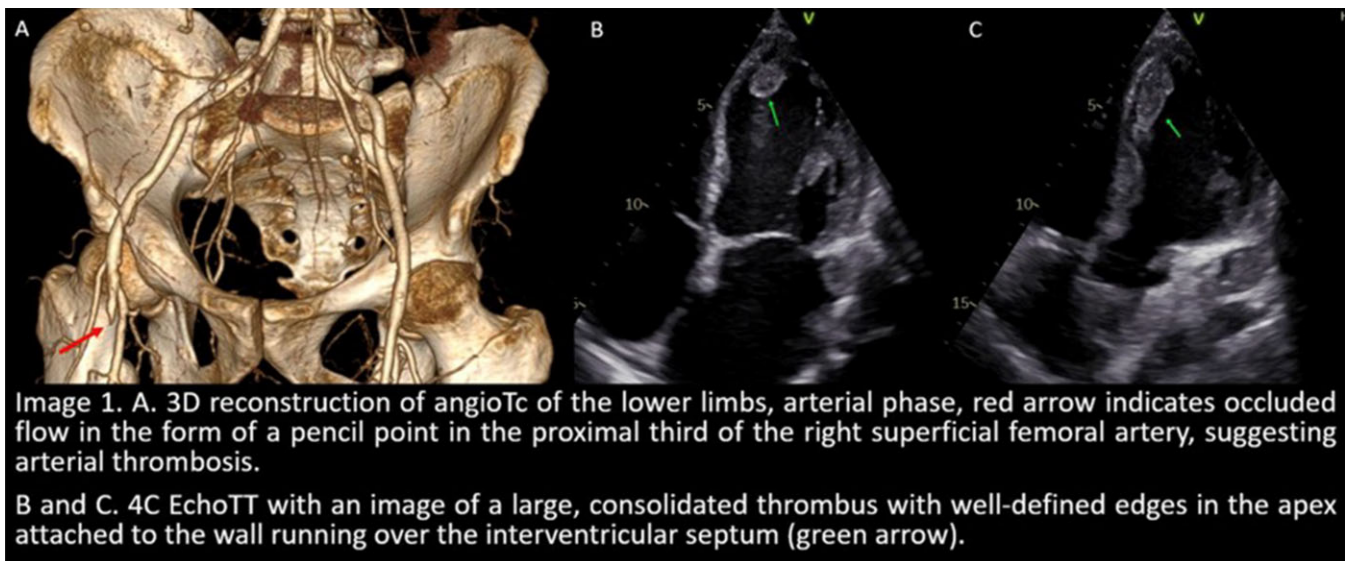
## Clinical Case 08—A challenging clinical case: acute limb ischemia as a presentation of a left ventricular thrombus in a patient with heart failure with reduced ejection fraction

Daniel Eduardo Paz Driotes\* and Veronica Vanesa Gomez Leiva

Instituto Salvadoreño del Seguro Social, El Salvador

\*Corresponding author. Email: [danielpazdriotes@gmail.com](mailto:danielpazdriotes@gmail.com)

A 57-year-old male with arterial hypertension, diabetes mellitus, ischemic heart disease and coronary bypass in 2018, was admitted to the hospital with a 1-day evolution of sudden pain of strong intensity in the lower right limb. On physical examination, lower right limb showed erythrocyanosis, multiple distal ulcers, absence of hair, distal coldness up to the level of the knee, capillary refill >5 seconds, with absence of pedal and popliteal pulses. Arterial echo-Doppler of the lower right limb was performed, which reported common femoral and superficial femoral arterial insufficiency, with no flow in the distal third of the femoral, popliteal, tibial, and peroneal arteries. AngioCT of the lower limbs reported bilateral chronic arterial insufficiency with no flow from the superficial femoral artery to the popliteal and anterior tibial arteries of the right leg. A transthoracic echocardiogram was performed, which reported dilated heart disease with a left ventricular ejection fraction of 16% and an apical thrombus in the left ventricle of approximately 1.2 cm × 4.1 cm. Anticoagulation with unfractionated heparin was started, and thrombectomy of the lower right limb was evaluated, with a high probability of amputation due to irreversibility of ischemia. However, due to a high probability of surgical complications, conservative management was decided. Due to Virchow's triad, patients with ischemic heart disease and heart failure with reduced ejection fraction are at high risk of intraventricular thrombi and subsequent embolization; therefore, the use of prophylactic anticoagulation should be considered to prevent this type of complication despite the evidence is controversial.



**Figure 1** A. 3D reconstruction of AngioCT of the lower limbs, arterial phase, red arrow indicates occluded flow in the form of a pencil point in the proximal third of the right superficial femoral artery, suggesting arterial thrombosis. B and C. 4C EchoTT with an image of a large, consolidated thrombus with well-defined edges in the apex attached to the wall running over the interventricular septum (green arrow).

## Clinical Case 09—Acute pulmonary embolism complicated by acute limb ischemia: a case report on the role of patent foramen ovale closure in thrombophilia

David Sá Couto<sup>1,2\*</sup>, André Alexandre<sup>1,2</sup>, António Marinho<sup>1,2</sup>, Filomena Oliveira<sup>1,2</sup>, André Luz<sup>1,2,3</sup>, and Severo Torres<sup>1,2</sup>

<sup>1</sup>Centro Hospitalar Universitário do Porto, Porto, Portugal

<sup>2</sup>ICBAS – School of Medicine and Biomedical Sciences, University of Porto, Porto, Portugal

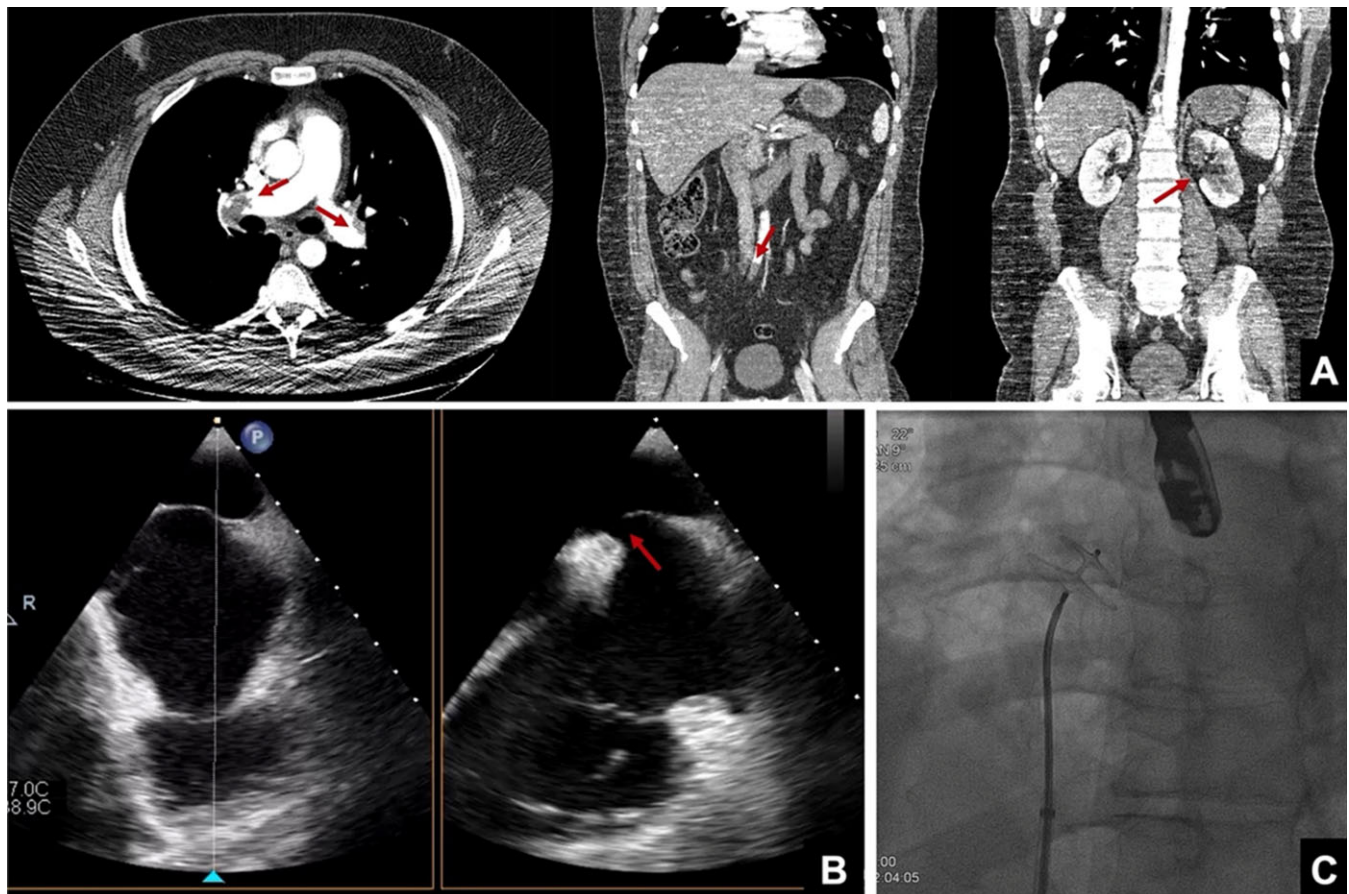
<sup>3</sup>Cardiovascular Research Group at UMIB, ICBAS, University of Porto, Porto, Portugal

\*Corresponding author. Largo do Prof. Abel Salazar, 4099-001, Porto, Portugal, E-mail: [david.sa.couto@gmail.com](mailto:david.sa.couto@gmail.com)

**Case report:** A 40-year-old obese man with hypertension and history of femoro-popliteal deep vein thrombosis (DVT), presented to the emergency department with right lower limb (RLL) ischemia associated with exertional dyspnoea for the past three weeks. Physical examination revealed a cold RLL without peripheral pulses and mild respiratory failure. Angio-CT revealed bilateral acute pulmonary embolism (APE), thrombosis of the right common iliac artery and left renal infarct (*Figure 1A*). Transthoracic echocardiogram revealed signs of pulmonary hypertension (PH), dilated right ventricle and a suspected patent foramen ovale (PFO) with spontaneous high volume right-to-left shunt. A diagnosis of intermediate-low risk APE with concomitant RLL acute ischemia was made. The patient underwent iliac thrombectomy, local fibrinolysis and started anticoagulation. Immunological study was positive for antiphospholipid syndrome. He recovered well and was discharged on Vitamin-K antagonists. Six months later, transoesophageal echocardiogram confirmed the PFO with persistence of right-to-left shunt with a bubble test, and recovery of the right ventricle function without signs of PH (*Figure 1B*). Due to the suspected paradoxical embolic event, resolution of the PH and shunt persistence, the patient underwent percutaneous PFO closure with Amplatzer PFO Occluder (25mm) [Abbott®] (*Figure 1C*). He has had no recurrence of thrombotic events ever since.

**Conclusion:** Concomitant arterial and venous thrombosis should prompt screening for an intracardiac shunt. Despite unclear evidence, PFO closure might reduce the risk for paradoxical embolism recurrence in a thrombophilic setting on top of oral anticoagulation.

**Keywords:** Patent foramen ovale • PFO • acute limb ischemia • acute pulmonary embolism • paradoxical embolism • thrombophilia • antiphospholipid syndrome • percutaneous PFO closure • structural heart intervention



## Clinical Case 10—An unusual case of thrombocytopenia following transfemoral aortic valve implantation

Ana Débora Câmara de Sá<sup>1†</sup>, André Antunes<sup>2</sup>, M. Raquel Santos<sup>1</sup>, Margarida Temtem<sup>1</sup>, João Adriano Sousa<sup>1</sup>, and Bruno Silva<sup>1</sup>

<sup>1</sup>Cardiology Department, Hospital Dr. Nélio Mendonça, Funchal, Portugal

<sup>2</sup>Hematology Department, Hospital Dr. Nélio Mendonça, Funchal, Portugal

\*Corresponding author. E-mail: [anadeboracamarasa@gmail.com](mailto:anadeboracamarasa@gmail.com)

† The presenting author is less than 40 years old and is in a Cardiology Residency Program.

**Clinical Case:** An 85-year-old female patient with diabetes, hypertension, obesity, chronic kidney disease and severe aortic stenosis was submitted to transcatheter aortic valve implantation (TAVI). During procedure unfractionated heparin was administered. Intervention was performed without complications and she was discharged with platelet count of 116,000/ $\mu$ L.

Fifteen days after (day 0), she was readmitted with dyspnea. Arterial blood gas showed hypoxemia and lactate levels of 5,8mmol/L. The ECG showed new-onset atrial fibrillation (AFib) with a rapid ventricular rate. Blood tests showed platelet count of 45,000/ $\mu$ L, D-dimers 2790ng/mL, worsening kidney function and high inflammation markers. An echocardiogram showed normofunctioning transcatheter aortic valve.

Pulmonary embolism (PE) or respiratory infection with new-onset AFib were admitted. The patient started enoxaparin and an antibiotic.

On day 4 the patient was oliguric needing dialysis. A CT Angiography was performed that excluded PE but showed several thrombus on the right atrium and appendix, right ventricle and on the abdominal aorta. Blood results showed hemolytic anemia. On day 8, the platelet count reached the nadir of 11 000/ $\mu$ L.

At that time, differential diagnoses included thrombotic thrombocytopenic purpura (TTP), heparin-induced thrombocytopenia and sepsis-induced disseminated intravascular coagulation (DIC). Laboratory evaluation showed a near-normal coagulation profile and a PF4+ antibody. Enoxaparin was stopped; fondaparinux and plasma therapy were started.

Platelet count took weeks to reach previous levels. The patient was discharged with a DOAC.

It is usual to have some degree of thrombocytopenia after TAVI. In this case we have a complex and challenging scenario, properly handled, and with a good outcome.

## **Clinical Case 11—Acute multivessel coronary artery thrombi: an unusual presentation of STEMI and management dilemma in a young patient with COVID-19**

Emma Higgisson\*† and Carl Vaughan

Mercy University Hospital, Cork, Ireland

\*Corresponding author. E-mail: [emma.higgisson@gmail.com](mailto:emma.higgisson@gmail.com)

† I confirm that the presenting author, Dr. Emma Higgisson, is less than 40 years old and is in clinical cardiology training (Cardiology Higher Specialist Training, Ireland).

Mr DC is a fit and healthy 32-year-old gentleman who presented on day 13 of his mild COVID-19 illness with sudden onset central chest discomfort, diaphoresis and vomiting following exercise. He had no past medical history, no significant cardiovascular risk factors and a normal physical exam. ECG showed ST elevation in anterior and inferior leads.

Mr DC underwent coronary angiogram which revealed a large semi-occlusive thrombus in the proximal LAD and moderate thrombus in the proximal RCA. There was no significant stenosis or plaque in any vessel. The diagnosis was therefore STEMI secondary to multivessel proximal coronary artery thrombi. We hypothesise that the patient's concurrent COVID-19 infection, hypercoagulable state post exercise and possible plaque rupture led to the development of these thrombi.

This is a very unusual case and presented a management dilemma. We decided to manage him conservatively with therapeutic heparin, dual antiplatelet therapy, bisoprolol and high dose statin therapy.

Following one week of conservative management, we performed a repeat coronary angiogram which showed complete resolution of all intracoronary thrombi and yielded an excellent angiographic result.

The patient was discharged to complete 1 year of dual antiplatelet therapy and has done very well.

Learning points include: risk factors and management options for coronary artery thrombosis, successful conservative management strategy, interval of repeat diagnostic imaging, coronary artery thrombosis associated with COVID-19 infection, the potential for mild clinical COVID-19 illness but significant cardiovascular complications, more research needed on anticoagulation and antiplatelet treatment of ACS in the context of COVID-19.

## Clinical Case 12—Thrombus on apical left ventricle: when the clinical suspicion is high

Fabiana Silva Duarte\*†, Inês Coutinho dos Santos, Maria Inês Barradas, Luís Oliveira, Carina Machado, Raquel Dourado, and Dinis Martins

Hospital of Divino Espirito Santo of Ponta Delgada, São Miguel Island, Portugal

\*Corresponding author. E-mail: [f.duarte@campus.ul.pt](mailto:f.duarte@campus.ul.pt)

† The author is under 40 years-old and in clinical training.

**Introduction:** Left ventricular thrombi may develop as a complication of myocardial infarction. Transthoracic echocardiography (TTE) has a low sensitivity for thrombus detection and other imaging methods are usually required.

**Case report:** A 32-years-old man with a past medical history of smoking habits, obesity and a ST-segment elevation myocardial infarction (STEMI) diagnosed on December 2017. Primary angioplasty was performed with stent implantation in the anterior descending coronary artery. TTE revealed severe systolic dysfunction (SD) and an apical aneurysm with thrombus formation. Six months after anticoagulation with warfarin, a cardiac magnetic resonance revealed thrombus resolution and it was decided to stop warfarin. On September 2021, the patient presented to the Emergency Department referring sudden chest pain. The electrocardiogram showed an anterior STEMI and in the Cath Lab a late stent thrombosis was evident. TTE revealed a severe SD and akinesia of apical segments (poor acoustic window).

On the 3rd day of hospital stay, the patient developed backache and Murphy's punch sign.

Imaging workup was suggestive of right renal infarction. At this time, the suspicion of embolic source arises, and the patient underwent contrast echocardiography demonstrating a filling defect suggestive of an apical thrombus. Therapy with warfarin was reinitiated concomitantly with dual antiplatelet therapy.

**Conclusion:** This is a particular case of an apical thrombus formation occurring twice in a young patient. There is a lack of evidence about the adequate screening methods and therapeutic approach. More cases need to be reported to understand the best approach in each case to minimize complications.



## Clinical Case 13—An unusual culprit: challenging diagnosis, easy solution

Fernando Guilherme Ribeiro Mané\*†, Rui Flores, Inês Conde, Rodrigo Silva, Carla Marques Pires, Paulo Medeiros, Cátia Oliveira, João Costa, and Jorge Marques

Hospital de Braga

\*Corresponding author. E-mail: [mane.guilherme@gmail.com](mailto:mane.guilherme@gmail.com)

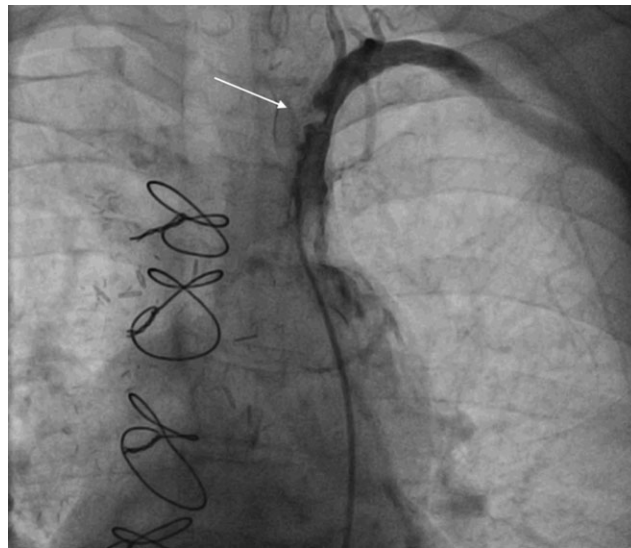
† The presenting author is less than 40 years old and in clinical training.

**Presentation:** A 59-year-old woman, with multiple cardiovascular risk factors, a history of CABG (left internal mammary artery—obtuse marginal artery; right internal mammary artery—left anterior descending artery) and PAD; presented to the emergency department with prolonged thoracic pain (3 hours) associated with dyspnea. She was hypertense at admission, but the remaining physical exam was unremarkable. Initial electrocardiogram showed descendent segment ST depression in the lateral leads (DI, aVL and V4-V6). Blood test showed a rise in troponin I 0.6 → 8.3 ng/mL). Cardiac catheterization demonstrated patency of both bypasses. However, a calcified stenosis (70–80%) of the left subclavian artery proximal to the emergence of the left internal mammary artery was observed.

**Diagnosis:** The findings suggested a possible coronary subclavian steal syndrome (CSSS).

**Management:** The patient was reevaluated and was found to have a systolic blood pressure differential of 18mmHg between the two arms. Despite anti-anginal therapeutic optimization, episodes of angina upon minimal exertion continued. Consequently, she was submitted to percutaneous subclavian artery angioplasty with symptom resolution and was discharged under dual antiplatelet therapy and high-intensity statin.

**Learning points:** CSSS complicates 0.2–6.8% of the patients who have undergone CABG with a left internal mammary graft. Peripheral artery disease is its strongest predictor and atherosclerosis is the main pathogenic mechanism. In patients with suspected CSSS, physical examination is paramount, often showing a systolic blood pressure differential. Subclavian artery angiography should be performed, whenever it is relevant, during the coronary angiography. First-line therapy includes percutaneous angioplasty and optimal medical therapy.



## Clinical Case 15—Warburg effect and pulmonary embolism: a confounding clinical case

Gonçalo Rafael Marques Ferreira<sup>1†</sup>, Joana Correia<sup>1</sup>, João Fiuza<sup>1</sup>, João Miguel Santos<sup>1</sup>, Vanda Neto<sup>1</sup>, Joana Cunha<sup>1</sup>, Filipe Fernandes<sup>2</sup>, Inês Pires<sup>1</sup>, Bruno Marmelo<sup>1</sup>, and Costa Cabral<sup>1</sup>

<sup>1</sup>Centro Hospitalar Tondela Viseu E.P.E

<sup>2</sup>USF Lusitana

† Cardiology Resident at Centro Hospitalar, Tondela Viseu E.P.E, 30 years old, born in 17/07/1992.

**Presentation:** A 61 year old man with a history of multiple lymph node metastasis of unknown primary cancer was admitted in the Emergency Room with sudden dyspnea preceded by left leg swelling. Physical examination revealed a blood pressure of 91/70mmHg, tachycardia, tachypnea and signs of deep vein thrombosis (DVT).

**Diagnosis and management:** Blood analysis showed increased serum lactate (SL) (5,5 mmol/L), a slight increase of cardiac enzymes and hypoglycemia, and imagiologic tests showed signs of bilateral pulmonary embolism (PE) and an increase of the right cardiac chambers. The patient was hospitalized with the diagnosis of intermediate-high risk PE. Because the patient presented persistent elevated SL and borderline hypotension, fibrinolysis was performed. However, the patient maintained high SL levels and hypotensive profile. After receiving the lymph node's biopsy result, which pointed towards a follicular lymphoma, the persistent hyperlactatemia, together with the hypoglycemic profile, was interpreted as a consequence of the Warburg Effect. Luckily, the patient didn't had any side effects of the fibrinolytic treatment.

**Learning points:** Acute high risk PE is marked by the presence of haemodynamic instability at presentation, and the finding of increased SL suggests peripheral hypoperfusion. Systemic thrombolytic therapy is indicated in most of patients with high risk PE. However, there are other causes of hyperlactatemia which the physician must be aware, as it can act as a confounder of PE risk assessment. The Warburg Effect may cause elevated SL in patients with cancer, which in turn are at risk of developing PE.

## Clinical Case 16—Intracoronary thrombus- a fatality to unmask

Isabel Martins da Cruz\*†, Inês Oliveira, Bruno Bragança, Rafaela Lopes, Inês Campos, Rui Santos, and Aurora Andrade

Centro Hospitalar do Tâmega e Sousa, EPE / Hospital Padre Américo, Vale do Sousa, Portugal

\*Corresponding author. E-mail: [isabelmartinscruz@hotmail.com](mailto:isabelmartinscruz@hotmail.com)

† The presenting author is less than 40 years old and in clinical training.

26-years-old man, occasional cannabis smoker, attended the emergency department due to chest pain and epigastralgia for the past 24h, after cannabis consumption. Electrocardiogram revealed ST-segment elevation with Q-waves in V3-V5 and inferior leads. Transthoracic echocardiogram presented: (1) cardiac chamber dilation; (2) severely reduced biventricular systolic function; (3) hypokinesia of left ventricle basal segments of the anterior, lateral and septal walls; (4) scar appearance of the posterior wall and ventricular apex; (5) apical thrombus. Emergent cardiac catheterization showed thrombus located at the medial and distal segments of the left anterior descending artery (LAD), occlusion of the first obtuse marginal (OM) artery and thrombus at the medial and distal segments of the right coronary artery. Angioplasty of the OM was unsuccessful and hypocoagulation was initiated. The patient started veno-arterial ECMO. Immunological study was normal. His clinical condition deteriorated with multiple organ dysfunction, and he died after 20 days. The autopsy revealed coronary atherosclerosis with fibrous plaques causing 80% stenosis of the LAD with two sub-occlusive thrombus, occlusion of the circumflex artery, 70% stenosis of the posterior descending artery, two areas of myocardial infarction and several intracardiac thrombus.

We aim to discuss the possible aetiologies for the thrombus formation. The association between cannabis and acute coronary syndromes has been reported and in cases of young adults with chest pain this diagnosis should be considered. Alternatively, our patient presented dilated cardiac chambers with scar walls and presence of intracardiac thrombus that could be the cause of systemic embolization in an undiagnosed dilated cardiomyopathy.

## Clinical Case 17—A catastrophic case of ischemic stroke and acute myocarditis in a young patient following mRNA COVID-19 vaccination: coincidence or consequence?

Jéni José Sá Quintal<sup>1\*</sup>, Carina Graça<sup>2</sup>, Dúlio Passos<sup>2</sup>, Tiago Camacho<sup>2</sup>, Gonçalo Faro Silva<sup>2</sup>, Susana Chaves<sup>2</sup>, Nicodemos Fernandes<sup>2</sup>, Tiago Catanho<sup>2</sup>, João Adriano Sousa<sup>3</sup>, Diogo Rijo<sup>4</sup>, Joana Caires<sup>5</sup>, and José Júlio Nóbrega<sup>2</sup>

<sup>1</sup>Department of Cardiology, Centro Hospitalar de Setúbal

<sup>2</sup>Hospital Central do Funchal, Intensive Care Unit

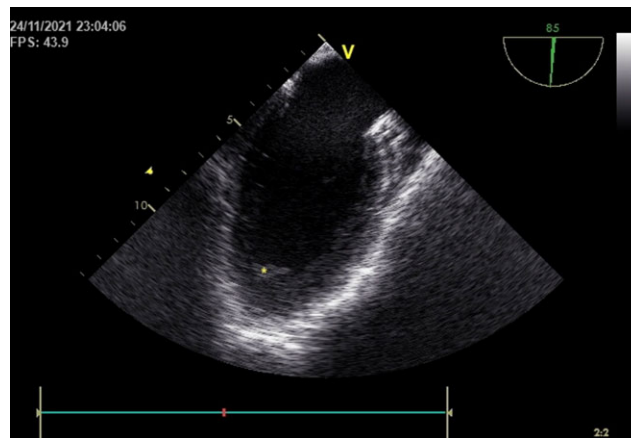
<sup>3</sup>Hospital Central do Funchal, Department of Cardiology

<sup>4</sup>Hospital Central do Funchal, Department of Cardiothoracic Surgery

<sup>5</sup>Unidade de Saúde Local de Guarda, Department of Internal Medicine

\*Corresponding author. E-mail: [jeniquintal@gmail.com](mailto:jeniquintal@gmail.com)

A healthy 32-years-old man was admitted in emergency department after cardiac arrest at home. He had complaints of fatigue and general malaise after Pfizer-BioNTech Coronavirus disease-2019 (COVID-19) first dose vaccine 48 hours earlier. Upon hospital admission, patient scored 3 points in Glasgow Coma Scale. Electrocardiogram showed atrial fibrillation with rapid ventricular response and a point-of-care ultrasound demonstrated severe left ventricular dysfunction with global hypokinesia. Blood tests were remarkable for elevation of high-sensitivity cardiac troponin-T and inflammatory parameters, normal platelet and fibrinogen levels and slightly increased D-dimer. A computed tomography (CT) with angiography of the cerebral arteries revealed acute ischemic posterior circulation stroke with total occlusion of the basilar artery and partial occlusion of the left vertebral artery. Life-saving systemic thrombolysis was performed but there was no clinical benefit. Pulmonary embolism was excluded. Transesophageal echocardiography showed severe left ventricular dysfunction (LVEF 30%), global hypokinesia and an apical thrombus with no other significant abnormalities. De novo multiple ischemic injuries were shown in 24h control brain CT. Once autoimmunity, thrombophilia study, PCR and serologic tests for viral infections including SARS-CoV-2 were negative, cardioembolic stroke following post-vaccinal myocarditis was suspected. Brain stem death was verified 72h later and a post-mortem endomyocardial biopsy was performed, although no signal of myocarditis was found. COVID-19 mRNA vaccination is associated with increased risk of myocarditis. We report the first known case of cardioembolic stroke and probable myocarditis after BNT162b2 first dose. This highlights that, although rare and with a predominantly favorable course, vaccine-related myocarditis can have life-threatening complications.



**Figure 1** Apical left ventricle thrombus on transesophageal echocardiography.

## Clinical Case 18—Management of patient with cancer and confirmed systemic thrombosis and rectal bleeding

Moskalenko Kateryna<sup>1\*†</sup>, Levenko Evgeny<sup>2</sup>, Lysak Zoreslava<sup>1</sup>, Doronina Myroslava<sup>1</sup>, and Yukish Oleh<sup>1</sup>

<sup>1</sup>Medical Center LLC 'Arensia Exploratory Medicine'

<sup>2</sup>Department of Clinical Research, Medical Center LLC 'Arensia Exploratory Medicine'

\*Corresponding author. E-mail: [katcher.work@gmail.com](mailto:katcher.work@gmail.com)

† Date of birth 28 NOV 1988 (33 y.o.).

A 55-year-old patient has been suffering from prostate cancer since February 2020. He received radiotherapy and developed disease progression in June 2021. Pt was started on chemotherapy with positive dynamic per CT scan. There was a worsening of anemia, and erythropoietin was prescribed, with not significant improvement.

During planned CT scan monitoring, pulmonary embolism of medial and distal segments of the left and distal parts of the right pulmonary artery was revealed. Pt had dyspnea on mild exertion, tachycardia at rest and left leg edema (which was present earlier and considered as lymphedema that time). Thrombosis of the left popliteal vein was confirmed. Pt was started on rivaroxaban 15 mg BID. In 5 days, he reported rectal bleeding. Hb was 71 g/l. Rivaroxaban was stopped. Proctological examination was not informative, due to bleeding. Tranexamic acid and IV iron were started. The attempt to add prophylaxis dose of enoxaparin increased bleeding and was stopped immediately. In 5 days, he underwent colonoscopy. Disease progression, severe hemorrhoids were excluded. Findings were considered as radiation proctitis. Sulfasalazine was added. In 2 weeks Hb = 91 g/l, however, patient has episodes of the rectal bleeding 1–2 times per week. He doesn't receive recurrent PE prevention with no worsening of clinical picture. Our strategy is to reassess bleeding risk after 1 month of treatment with sulfasalazine and to start prevention doses of DOACs.

**Conclusion:** In complex clinical situations prevention of thrombosis should be based on patient-related risk factors, must be flexible and reviewed more often and thoroughly.

## Clinical Case 20—Recurrent intracoronary in-stent restenosis in a young woman

Margarida Cabral<sup>1\*</sup>†, Mariana Carvalho<sup>1</sup>, Sara Fernandes<sup>1</sup>, Rita Carvalho<sup>1</sup>, Tiago Teixeira<sup>1</sup>, Catarina Ruivo<sup>1</sup>, Pedro Jerónimo de Sousa<sup>1</sup>, Alexandre Antunes<sup>1,2</sup>, and João Morais<sup>1,2</sup>

<sup>1</sup>Division of Cardiology, Leiria Hospital Centre, Leiria, Portugal

<sup>2</sup>ciTechCare (Centre for Innovative Care and Health Technology), Polytechnique, Leiria, Portugal

\*E-mail: [anamargaridacabral@outlook.pt](mailto:anamargaridacabral@outlook.pt)

† The presenting author is either less than 40 years old and in clinical training.

**Clinical case:** A 39-year-old smoker woman underwent a percutaneous coronary intervention with two Zotarolimus-eluting stents implantation due to right coronary artery occlusion in the context of ST-elevation myocardial infarction (MI). She was medicated with dual antiplatelet therapy and high-intensity statin and stopped smoking.

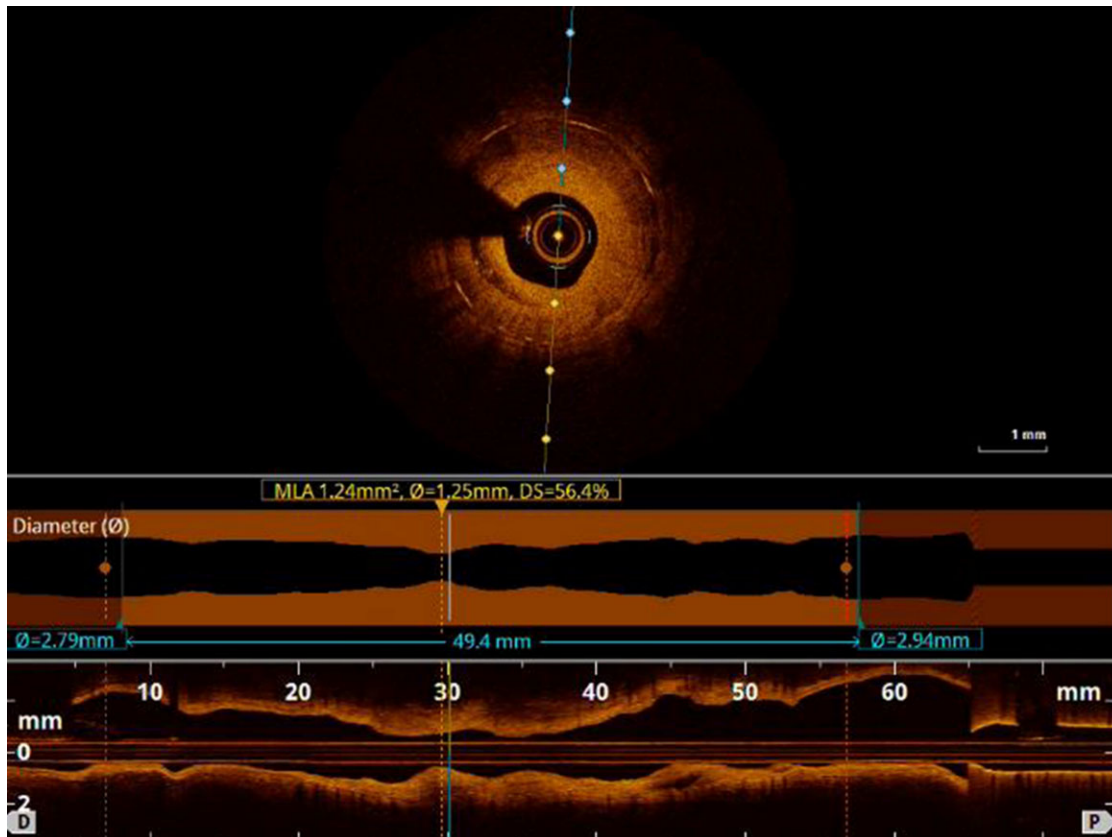
Nine months later, due to angina symptoms, cardiac catheterization with intravascular ultrasound showed severe restenosis, treated with a drug-coated balloon (DCB).

Two months later, she was admitted due to non-ST elevation MI and the cardiac catheterization presented thrombotic occlusion of previously implanted stents, treated with balloon dilatation. After two months, she remained with angina and a dobutamine stress echocardiogram showed inferior wall ischemia. The angiographic revision revealed proximal in-stent restenosis, treated with DCB.

About a year later, a fifth coronary angiography was performed due to recurrence of angina. Diffuse in-stent restenosis by neo-atherosclerosis was identified by optical coherence tomography. The lesion was treated with a cutting balloon and Everolimus-eluting stent implantation. The cholesterol-lowering treatment was optimized and the patient remained stable for some months. However, she is currently reporting recurrence of angina. Clinical management and guidance await Heart Team discussion.

### Learning points:

- The intracoronary in-stent restenosis (ISR) mechanisms include a complex pathological spectrum that can range from smooth muscle cell proliferation to neoatherosclerosis.
- In the drug-eluting stent and drug-coated balloon era, the ISR rate was reduced to <10%.
- ISR often has a challenging diagnosis and management, and is frequently associated with a poor prognosis.



**Figure 1** Optical coherence tomography showing stent neoatherosclerosis with more severe stenosis in the middle segment and a minimal luminal area of 1.2 mm<sup>2</sup>.

## Clinical Case 21—An unusual cause for hypoxemia and breathlessness

Margarida Gancho de Figueiredo<sup>1\*†</sup>, Sofia Paula<sup>1</sup>, Samuel Almeida<sup>1</sup>, Francisco Gomes<sup>2</sup>, Filipa Ferreira<sup>3</sup>, João Luz<sup>3</sup>, Diogo Cunha<sup>3</sup>, Oliveira Baltazar<sup>3</sup>, and Lurdes Almeida<sup>1</sup>

<sup>1</sup>Department of Cardiology, Centro Hospitalar Barreiro Montijo EPE, Barreiro, Portugal

<sup>2</sup>Department of Internal Medicina, Centro Hospitalar Barreiro Montijo EPE, Barreiro, Portugal

<sup>3</sup>Department of Cardiology, Hospital Garcia de Orta EPE, Almada, Portugal

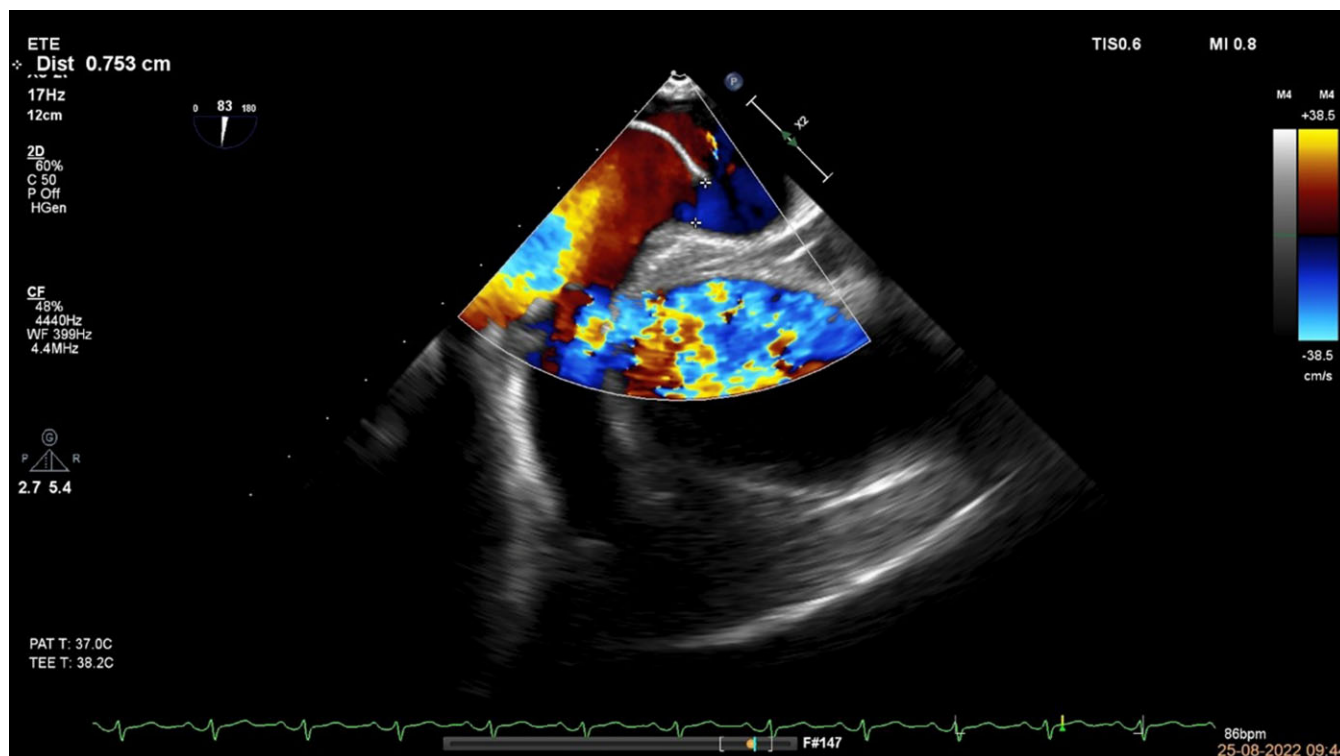
\*Corresponding author. E-mail: [margarida.figueiredo1994@gmail.com](mailto:margarida.figueiredo1994@gmail.com)

† The presenting author is either less than 40 years old and in clinical training.

Thanks to the author's interest, complementary diagnostic tests were performed and the diagnosis was made. The author also made it possible to treat the patient through contact with the colleagues that performed the procedure.

75-year-old woman with past medical history of ischemic stroke in 2019, when complementary diagnostic tests were performed and it was found that the patient had a patent foramen ovale (PFO). Current hospitalization due to COVID-19 pneumonia, which was complicated by bacterial co-infection and intermediate-low risk right main pulmonary artery thromboembolism. The patient was successfully treated, with improvement of the clinical condition and evident imaging resolution of pulmonary cavitations and recanalization of the right pulmonary artery. However, something intriguing was observed: the patient presented dyspnea in the upright position and a decline in transcutaneous oxygen saturation from 96% in the supine position to 85% in orthostatism, with reversal of these findings with the recumbency. This led to the suspicion of platypnea-orthodeoxia syndrome. A transesophageal echocardiogram with bubble test was then performed, revealing an atrial shunt in the supine position without Valsalva maneuver. With these evidences, the diagnosis of platypnea-orthodeoxia syndrome was made. Even though the patient was >60 years, due to important right-to-left shunt, the history of stroke and the current platypnea-orthodeoxia, it was decided to close the PFO. The day after the procedure, the patient was placed in the upright position, maintaining an oxygen saturation of 96%.

This case is an example that the decision of closing PFO must be individualized, not focusing only on patient's age, but also on his medical history and current situation, as indicated in the 2022 Guidelines for the Management of Patent Foramen Ovale.



**Figure 1** Transesophageal echocardiogram showing interatrial communication.

## Clinical Case 22—When the unusual appears

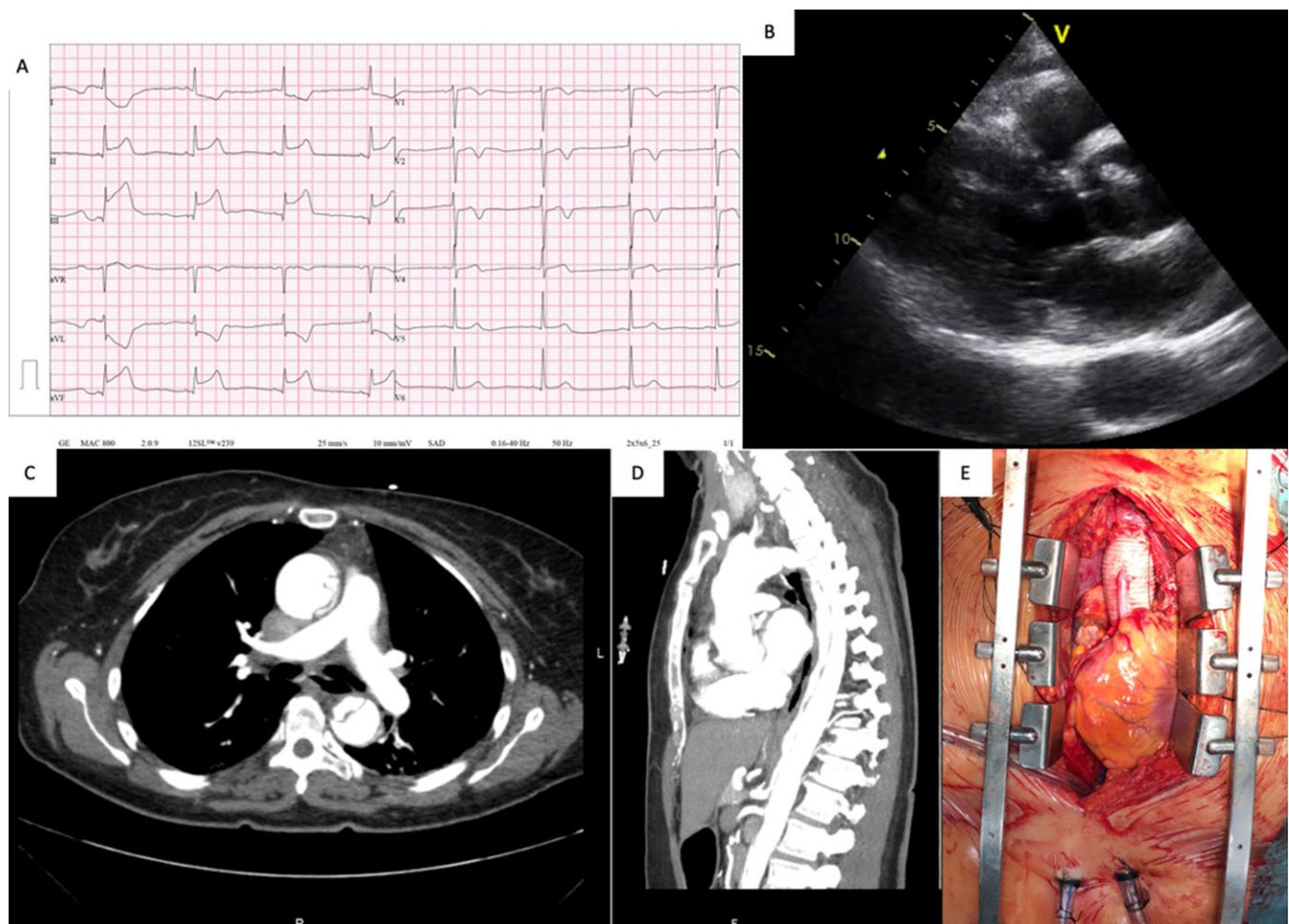
Ana Margarida de Abreu Temtem\*, Débora Sá, Marina Santos, Sofia Leça, Ricardo Rodrigues, Gomes Serrão, Bruno Silva, Graça Caires, António Brazão, João Manuel Rodrigues, and Drumond Freitas

Cardiology Department, Central Hospital of Funchal

\*Corresponding author. E-mail: [ea.margarida.temtem@gmail.com](mailto:ea.margarida.temtem@gmail.com)

**Clinical case:** A 57 years old female, smoker, presented to emergency department with a constrictive chest and epigastric pain lasting for 30 minutes. Admission electrocardiogram showed a sinus bradycardia and ST elevation in the inferior leads. Inferior STEMI was assumed and was referred for primary coronary intervention. Coronary angiography revealed a right coronary artery (RCA) occluded at ostial level and primary angioplasty was performed with drug eluting stent implantation. After angioplasty, the chest pain didn't relief, although the procedure had no complications. Transthoracic echocardiogram revealed a 'flap' on the ascending aorta (AAo), suggesting dissection of the AAo; left ventricular systolic function preserved, with hypokinesia of the inferior wall; right ventricular dysfunction; aortic regurgitation and no pericardial effusion. Emerging angio CT confirmed type A aortic dissection extending to abdominal aorta. The patient was then admitted to the operating room and a supracoronary conduit (hemiarch) and a bypass (saphenous vein/RCA) procedure was done. She had progressive clinical improvement and was discharged on the 17th day.

**Learning points:** Acute aortic dissection is the most common acute aortic syndrome (AAoS), being more prevalent in males and in the elderly, presenting high mortality rate. Acute type A aortic dissection can be difficult to diagnose and can mimic STEMI. RCA is more often involved when myocardial infarction is present. What appeared to be a linear STEMI turned out to be an AAoS that could have a catastrophic outcome. This was a successful case of this unusual diagnosis that surprised the entire team.



**Figure 1** A—Admission electrocardiogram with ST elevation in the inferior leads. B—Echocardiogram showing the 'flap' on the AAo. C and D—Angio TC that confirmed type A aortic dissection extending to abdominal aorta. E—Final result of the surgery showing the supracoronary conduit and bypass (saphenous vein/RCA).



## **Clinical Case 23—Adult-onset recurrent Kawasaki disease complicated by coronary aneurysms and recurrent acute myocardial infarction**

Mariana Margarida Ferreira Carvalho\*†, Carolina Gonçalves, Margarida Cabral, Sara Lopes Fernandes, Rita Ribeiro Carvalho, Jorge Guardado, and João Morais

Centro Hospitalar de Leiria

\*Corresponding author. E-mail: [mmcarvalho93@gmail.com](mailto:mmcarvalho93@gmail.com)

† The presenting author is a cardiology resident/fellow, less than 40 years old and in clinical training.

**Summary of case:** A 67-year-old man presented to the emergency department (ED) with acute chest pain. He had the previous diagnosis of Kawasaki disease (KD) made when he was 51 years-old in a event of a acute myocardial infarction. Upon admission, his blood pressure was 100/70 mm Hg, heart rate was 55 beats/min, afebrile. Clinical examination was unremarkable. Electrocardiogram showed a sinus rhythm without any ST-T alterations. An echocardiogram showed mildly decreased left ventricular function (LVEF) of 44% by the biplane Simpson method, with hypokinesia of anterolateral and inferolateral wall, and enlargement of the ascending aorta and aorta root. Cardiac enzymes were elevated, troponin-I 10.5 ng/mL and NTproBNP of 832 ng/mL. The diagnosis of acute myocardial infarction without ST segment elevation was made. Cardiac catheterization revealed diffuse aneurysmal dilation of the left anterior descending artery and right coronary artery. Circumflex artery was occluded in the mid segment. Thrombotic aspiration was made and a drug-eluting stent was implanted. The patient showed clinical improvement and was discharged 4 days later with ticagrelor and aspirin.

This case illustrates the importance to recognize adult-onset KD as part of the differential diagnosis of chest pain with ST-segment elevation in a adult, even if uncommon. Early recognition is fundamental, permitting correct treatment and prevention of potentially fatal coronary complications.

## Clinical Case 24—Multisite thrombosis in a patient with acute coronary syndrome: when the unlikely becomes reality

Marius Traian Dragoș Marcu<sup>1\*†</sup>, Cristina Andreea Adam<sup>2</sup>, Radu Andy Sascău<sup>1,2</sup>, and Cristian Stătescu<sup>1,2</sup>

<sup>1</sup>University of Medicine and Pharmacy 'Grigore T. Popa' Iași

<sup>2</sup>Institute of Cardiovascular Diseases 'Prof. Dr. George I.M. Georgescu' Iași

\*Corresponding author. E-mail: [dragos.marcu11@yahoo.com](mailto:dragos.marcu11@yahoo.com)

† I hereby confirm that I am under 40 years old; date of birth 11 September 1990.

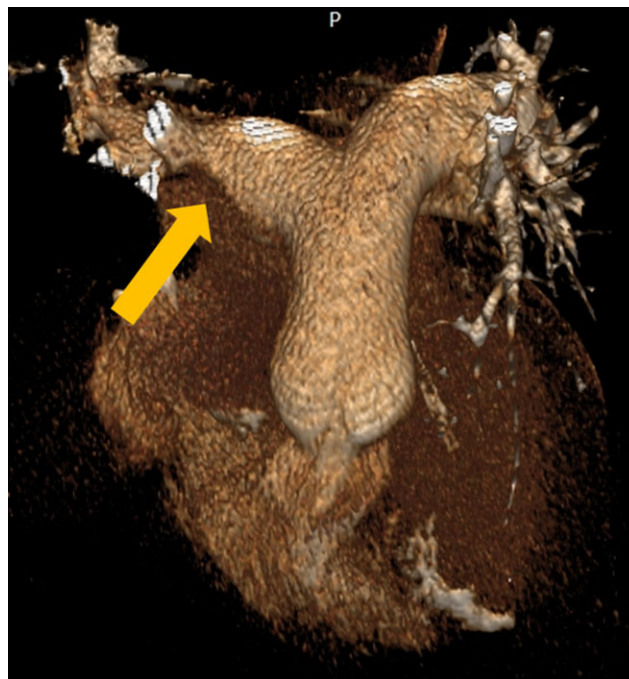We present the case of a 78-year-old patient, admitted for chest pain for 1 week prior to presentation. In the view of the electrocardiographic changes, myocardial cytolysis and severely decreased left ventricular ejection fraction, an acute coronary syndrome was highly likely. Coronary angiography identified a 99% stenosis in the anterior descending artery for which an angioplasty was performed.

Afterwards, the patient becomes dyspneic, hemodynamically unstable, suggesting a pulmonary embolism. The pulmonary CT angiography confirmed the presence of a thrombus in the right pulmonary artery. During thrombolysis, the patient was hemodynamically stable, without complications, achieving improvement of symptoms.

The next day, the patient had pain at the inguinal level and a significant decrease in hemoglobin. A soft tissue ultrasound was performed, showing a partially thrombosed femoral pseudoaneurysm. Vascular Doppler ultrasound revealed multiple occlusive thrombi in the femoral, popliteal and posterior tibial veins. Echocardiography confirms the presence of floating thrombi in the right ventricle.

After a first dose of Apixaban the patient develops erythema. Allergy tests showed intolerance to Apixaban. Considering the associated pro-coagulant status, we performed a series of biological and imaging explorations that showed the presence of a malignant brain neoplasm that induced the complications mentioned above. Unfortunately, the patient died one month after discharge.

The occurrence of pulmonary embolism secondary to revascularized acute myocardial infarction, apparently without risk factors, requires identification of underlying pathologies associated with a pro-coagulant status. Unfortunately, often, behind such events, we discuss about an oncological pathology.



**Figure 1** 3D reconstruction of right pulmonary artery thrombosis.

## **Clinical Case 25—Intrinsic prothrombotic states and his influence on the management of the patient with acute myocardial infarction**

Miguel Carias de Sousa\*†, Bruno Piçarra, Ângela Bento, and Manuel Trinca

Hospital do Espírito Santo de Évora, Portugal

\*Corresponding author. E-mail: [mcarias205@gmail.com](mailto:mcarias205@gmail.com)

† The author is 28 years-old and he is in clinical training.

A 61-year-old man with arterial hypertension (HTA), dyslipidemia, type 2 diabetes mellitus, ischemic stroke, obesity and a former smoker, was admitted to the Cardiology department for Acute Myocardial Infarction (AMI). The patient underwent angioplasty of anterior descending coronary artery. He was medicated with a dual antiplatelet regimen with acetylsalicylic acid (ASA) and Ticagrelor. After 4 days, he was readmitted for extensive previous AMI, which initially progressed to cardiogenic shock. An angiographic review and OCT revealed subacute stent thrombosis and stent malposition. Balloon angioplasty and successful thrombus aspiration were performed. On the following day, due to severe chest pain, the patient was admitted again, with recurrence of acute intrastent thrombosis. Aspiration of thrombus was performed, reestablishing flow and immediate pain relief. At discharge, due to moderate depression of left ventricular function, he started prognosis-modifying medication for heart failure with reduced ejection fraction and maintained dual antiplatelet therapy with ASA and Clopidogrel, associated with Rivaroxaban 15 mg for 3 months. In the following consultations, the therapy for heart failure and control of cardiovascular risk factors was optimized. Clopidogrel was discontinued 2 years after the last acute event, maintaining ASA monotherapy, with no new similar episodes. The analytic study revealed systemic lupus erythematosus and hyperhomocysteinemia. This antithrombotic therapy proved to be a challenge, demonstrating the importance of strict adherence to recommended doses. In addition, it should be noted that each patient may have intrinsic prothrombotic states that may have implications on their management, so the study of thrombophilia is extremely important.

## Clinical Case 26—Is it possible to live with thrombosed left ventricular assist device (LVAD)?

Nina Dračina\*†, Miodrag Golubović, Ranko Zdravković, Aleksandar Redžek, Mirko Todić, and Andrej Preveden

Institute for Cardiovascular Diseases of Vojvodina, Sremska Kamenica, Serbia

\*Corresponding author. E-mail: [ninadracina@gmail.com](mailto:ninadracina@gmail.com)

† We state that the presenting author is 28 years old.

LVAD HeartWare was implanted in a 63-year-old patient with end-stage dilated cardiomyopathy. The postoperative course was complicated by massive gastrointestinal (GI) bleeding that required surgical exploration of the GI tract.

For the next 1.5 years, the patient has significantly improved functional capacity with proper LVAD function. A month before the incident, an alarm indicating a pump malfunction was recorded. The patient presents with congestive symptoms and an altered sound of LVAD. Laboratory indicates seven times elevated LDH values, low HGB and INR 3.03. Thrombophilia tests were negative. Echo examination does not indicate pump thrombosis, but the pump parameters show increased energy consumption (>6 W) and increased flow (>7 L/min). A diagnosis of LVAD thrombosis was made.

Fibrinolytic therapy was contraindicated because of a history of GI bleeding, so a continuous infusion of heparin was started. Despite this, the patient's clinical condition deteriorates, and a decision was made to discontinue the LVAD, to prevent further hemolysis that led to acute kidney injury (AKI). The procedure was performed without endangering the patient.

Massive hemolysis, however, leads to the progressive development of AKI requiring CVVHDF. Global respiratory insufficiency develops and mechanical ventilation was started. After six days of intensive treatment, the patient recovered and was discharged home with a thrombosed pump.

For the next 2.5 years, the patient was in satisfactory condition during follow-ups, the pump was not explanted.

Even sophisticated medical devices carry with them risks for the patient's life despite adequate management.

Treatment of LVAD thrombosis depends on patient characteristics and pump-related factors.

## Clinical Case 28—Hyperacute synchronous cardiocerebral infarction in a patient with new-onset atrial fibrillation: a rare case of MINOCA

Panteleimon E. Papakonstantinou<sup>1</sup>, Konstantinos Manousiadis<sup>1</sup>, Ilianna Bei<sup>1</sup>, Malamati-Eleni Lentza<sup>2</sup>, Maria Panourgia<sup>2</sup>, Dimitra Tachmetzidi-Papoutsis<sup>3</sup>, and Antonios Sideris<sup>1</sup>

<sup>1</sup>Second Cardiology Department, Evangelismos Hospital, Athens, Greece

<sup>2</sup>Neurology Department, Evangelismos Hospital, Athens, Greece

<sup>3</sup>Radiology Department, Evangelismos Hospital, Athens, Greece

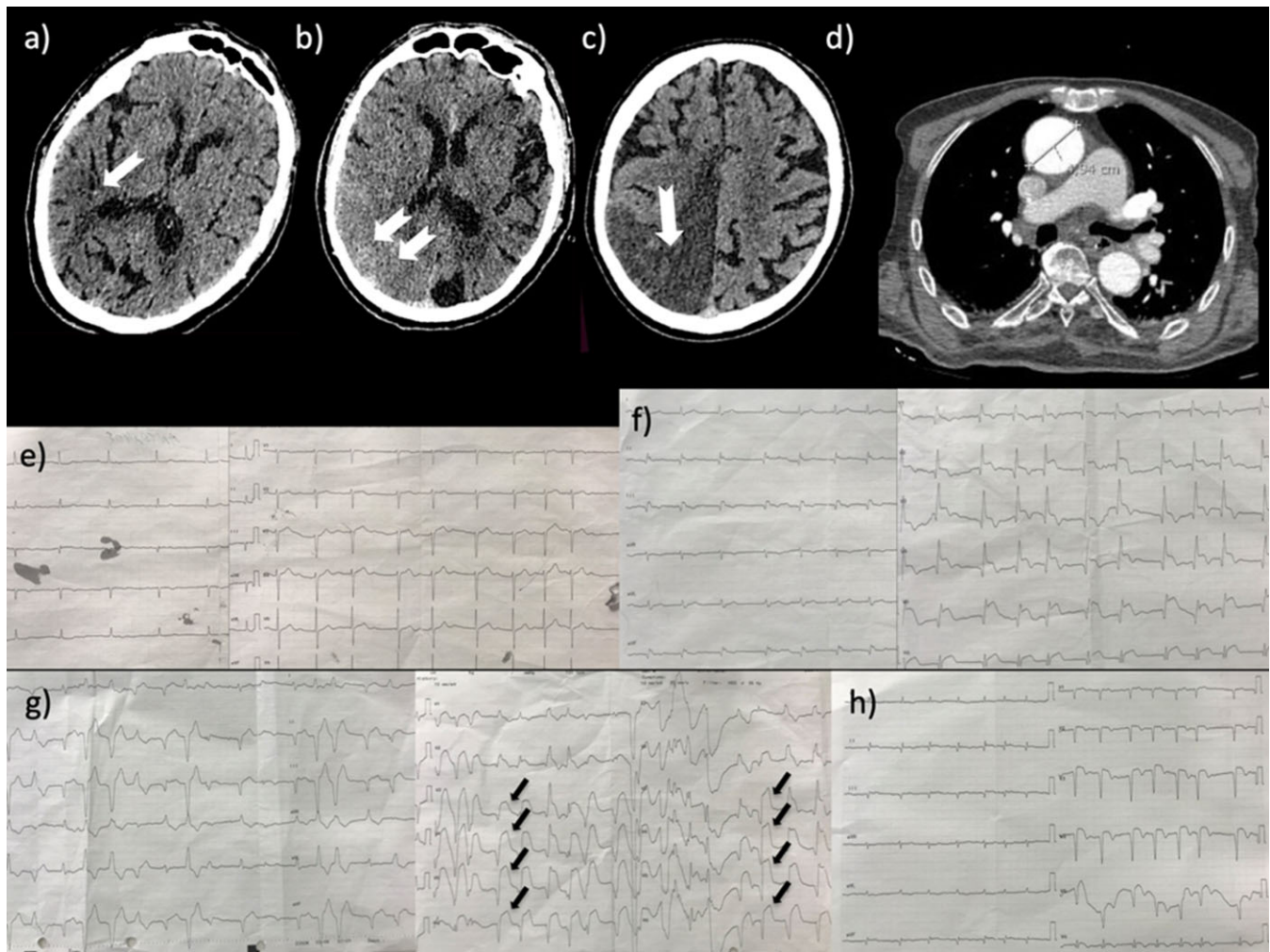
\*Corresponding author: 2nd Cardiology Department, Evangelismos Hospital, Ipsilantou 45-47, 106 76 Athens, Greece. Tel: +30 213 204 1466, fax: +30 213 204 1433, E-mail: [pantelisapakon@gmail.com](mailto:pantelisapakon@gmail.com)

**Introduction:** Hyperacute synchronous cardiocerebral infarction (CCI) is an extremely rare condition with an incidence of 0.009%. Herein, we present a case of hyperacute synchronous CCI in an elderly patient with new-onset atrial fibrillation (AF).

**Case report:** An 80-year-old male patient was referred to our emergency department due to acute onset left hemiparesis and dysarthria. Computed tomography (CT) of the brain showed a hyperdense M3-M4 branch of the right middle cerebral artery. The electrocardiogram (ECG) revealed new-onset AF without specific signs of acute myocardial ischemia. Subsequent ECG revealed AF with Q waves and ST elevation in leads V1-V6, II, III, and aVF, while the patient remained hemodynamically stable, without symptoms indicative of myocardial ischemia. Intravenous tissue plasminogen activator (alteplase) was administered. During the thrombolytic therapy, the patient expressed sudden severe upper back pain, while the ECG showed 'tombstone' ST elevation in leads V1-V6, II, III, and aVF. The thrombolytic therapy was immediately terminated and a CT angiography of the aorta was performed, which did not show any evidence of aortic dissection. Coronary angiography revealed no angiographically significant coronary artery stenosis. ECG evolution, echocardiography, and coronary angiography findings were consistent with myocardial infarction with non-obstructive coronary arteries (MINOCA).

**Discussion:** There are several conditions that lead to simultaneous acute CCI. The precise pathophysiological mechanism that leads to this synchronous CCI is difficult to be identified. In our case, the presence of new-onset AF can partly explain this situation as a source of both cerebral and coronary embolism.

**Keywords:** Cardiocerebral infarction • Atrial fibrillation • Myocardial infarction • Stroke • MINOCA



**Figure 1** A. The hyperdense M3-M4 branch of the right MCA (arrow) was shown on the non-contrast axial CT scan performed shortly after the onset of symptoms. A hyperdense vessel represents an intravascular thrombus and is the earliest sign of acute infarct on non-contrast CT. B. A non-contrast axial CT scan performed 24 hours after the onset of symptoms shows brain swelling with sulcal effacement regarding the right MCA territories (arrows). The above findings are evidence of an acute infarct. C. A non-contrast axial CT shows hypoattenuating brain tissue along with loss of grey-white matter differentiation (arrow), findings consistent with ischemic damage due to infarcts concerning branches of the right MCA. D. Axial CT angiography revealed a fusiform aneurysm of the ascending thoracic aorta measuring approximately 5 cm at the level of the pulmonary artery trunk. E. ECG: AF (~70 bpm) without specific signs of acute myocardial ischemia. F. ECG: AF (~70 bpm) with Q waves and ST elevation in leads V1-V6, II, III, and aVF. G. ECG: AF (~100 bpm) with Q waves and 'tombstone' ST elevation (arrows) in leads V1-V6, II, III, and aVF. H. ECG: AF (~100 bpm) with deep Q waves and ST elevation in leads V1-V6, II, III, and aVF. **CT**: computed tomography; **MCA**: middle cerebral artery; **ECG**: electrocardiogram; **AF**: atrial fibrillation; **bpm**: beats per minute.

## Clinical Case 29—The role of transthoracic echocardiography on patients presenting with shock of unknown etiology

Margarida Gancho de Figueiredo†, Margarida Figueiredo\*, Mariana Santos, Hélder Santos, and Samuel Almeida

\*Corresponding author. E-mail: [margarida.figueiredo1994@gmail.com](mailto:margarida.figueiredo1994@gmail.com)

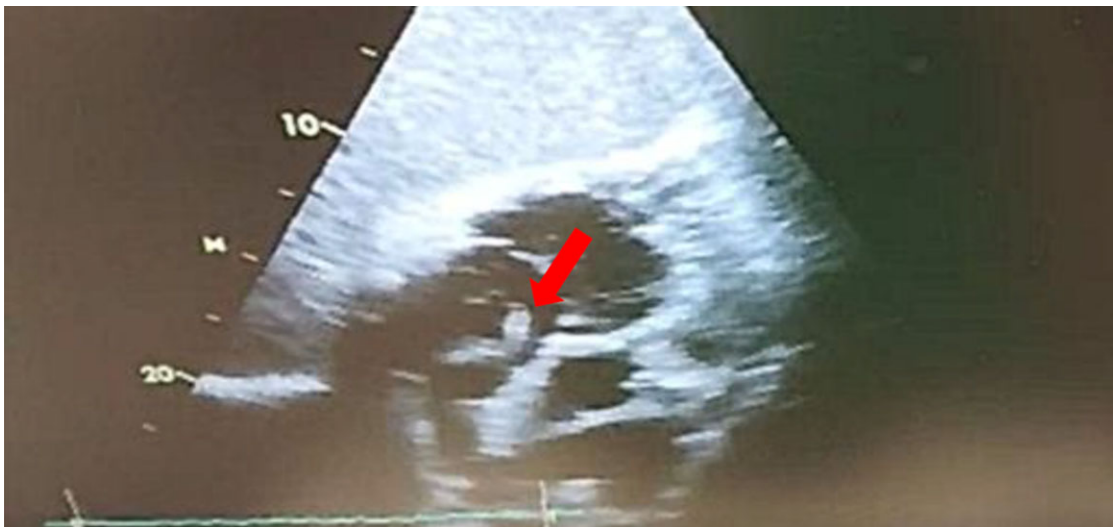† The author is less than 40 years and in clinical training.

Seventy-six-year-old woman, with a previous medical history of arterial hypertension, dyslipidaemia, hypothyroidism and mitral valve plasty (previous rheumatic fever) presents to the emergency department with unspecific complaints of malaise, productive cough and dyspnoea for the past 15 days. At admission, the patient was conscious, afebrile, tachycardic, hypotensive and with peripheral oxygen saturation of 90% (on room air). The patient became haemodynamically unstable and unresponsive.

Electrocardiogram with sinus tachycardia, SIQIII pattern and a slight ST elevation in aVR and ST depression in DI, aVL and precordial leads. TTE revealed right cavities dilatation and the presence of a serpiginous echogenic mass that protruded from the inferior vena cava crossing the right atrium and reaching the right ventricle. Thrombolysis, fluid challenge and vasopressor perfusion were immediately started with a good clinic response.

Haemodynamic stability was achieved 5 hours after the thrombolysis. An unfractionated heparin perfusion was initiated after the thrombolysis and discontinued 24 h after the patient was admitted. The remaining hospitalization was uneventful and the patient was discharged 7 days after on a non-vitamin K antagonist oral anticoagulant. TTE reevaluation before discharge revealed mild dilatation of the right cavities with mild systolic dysfunction of the right ventricle and a normal PSAP.

There is no scientific evidence regarding the best strategy to approach a patient with a migrating thrombus and TTE is of high value in the case of shock due to its high specificity as a rule-in test, especially when the patient cannot undergo other types of exams.



**Figure 1** Transthoracic echocardiography (subcostal 4 chamber view) showing the presence of a serpiginous echogenic mass in the right atrium (red arrow).

## Clinical Case 31—Active gastrointestinal bleeding during STEMI: a management dilemma

Vanessa Filipa de Sousa Lopes\*†, Nádia Moreira, Francisco Gonçalves, and Lino Gonçalves

Coimbra Hospital and University Center

\*Corresponding author. E-mail: [vlopes.pt@gmail.com](mailto:vlopes.pt@gmail.com)

† The presenting author is less than 40 years old and is in clinical training.

A man in his 40s presented to the emergency department with chest pain for 8 hours. ECG showed an anterior wall ST-segment elevation myocardial infarction (MI). He received a loading dose of both aspirin and ticagrelor. Coronary angiography demonstrated occlusion of the proximal left anterior descending artery, and primary percutaneous coronary intervention (PCI) with one drug-eluting stent was performed.

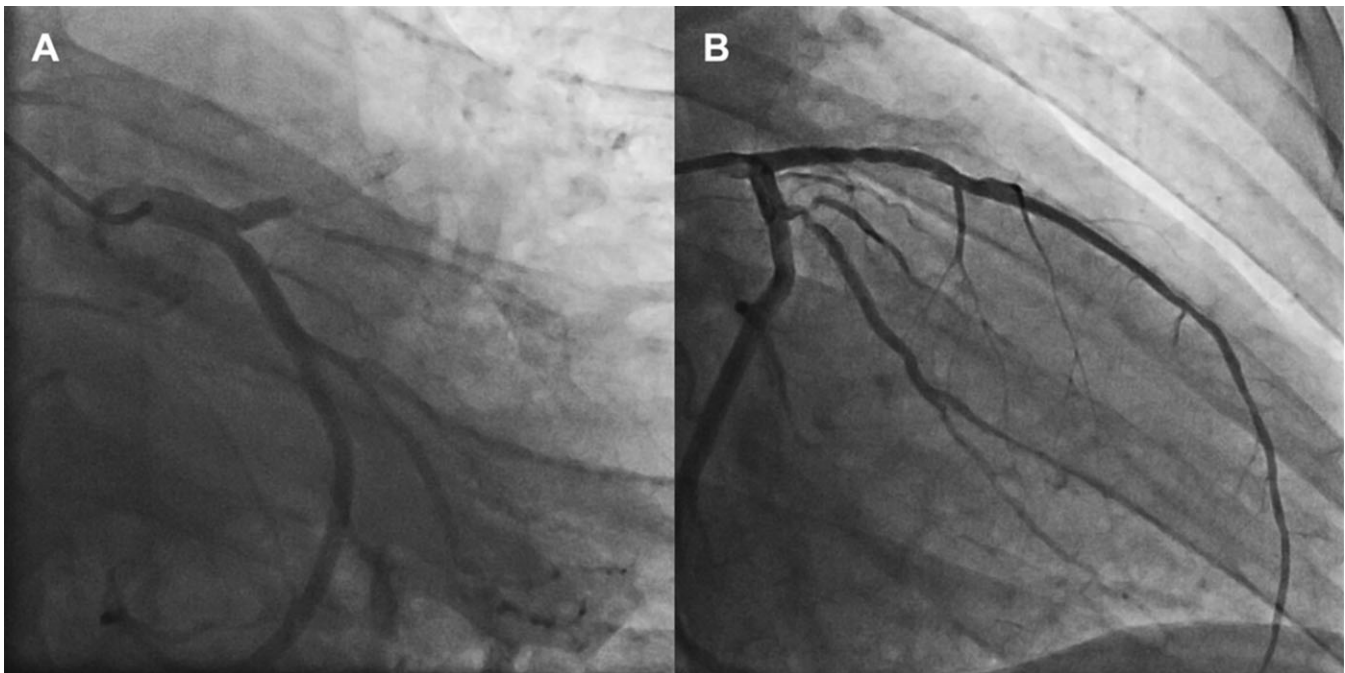
The patient also presented melena for 5 days. At admission, his hemoglobin was 6.3 g/dL and he was stable. He received a blood transfusion and was started on IV pantoprazole. Endoscopic study was postponed due to concerns related to performing such exam in the setting of a recent MI.

The day after PCI, the patient presented major bleeding and hypotension, leading to interruption of the P2Y12 inhibitor. On day 3 of hospitalization, while on single antiplatelet therapy with aspirin, the patient presented new onset of chest pain. He was diagnosed with subacute stent thrombosis (type 4b MI), and thrombus aspiration and balloon angioplasty were performed (*Figure 1A, and B*). Dual antiplatelet therapy was immediately restarted. Echocardiography revealed worsened left ventricular dysfunction (LVEF of 20%). Endoscopy showed tears in the esophagogastric junction (Mallory-Weiss syndrome).

This case challenged clinical decision-making, especially the antithrombotic strategy after primary PCI in a patient with major bleeding.

### Learning points:

- Management of a bleeding patient with acute MI should be individualized. The decision to withhold antithrombotic treatment should weigh the risks related to ongoing bleeding and stent thrombosis.
- Early endoscopy for acute gastrointestinal bleed in recent MI appears to be a safe procedure for hemorrhage control, although evidence is lacking.



**Figure 1** Coronary angiography. *A*—Total occlusion with in-stent thrombus in the proximal left anterior descending artery. *B*—After thrombus aspiration and angioplasty with paclitaxel-coated balloon of stent thrombosis in the proximal left anterior descending artery, remaining a residual lesion of 50–70%, and distal flow TIMI grade 3.



# AUTHOR INDEX

P = Poster presentation O = Oral presentation name/abstract number/(page number)

- Aarnink E. (ii86)  
 Abecasis J. (ii19)  
 Abid L. (ii8)  
 Aboyns V. (ii74), (ii75)  
 Adam C.A. (ii118)  
 Adam Z. (ii22)  
 Adela S.-T. (ii65)  
 Adler\* K. (ii13)  
 Aguiar C. (ii71), (ii73)  
 Albuquerque F. (ii19), (ii73)  
 Alcover S. (ii85)  
 Alegria S. (ii31), (ii78)  
 Alexandre A. (ii101), (ii105)  
 Almeida C. (ii70)  
 Almeida G. (ii72)  
 Almeida J.P. (ii72)  
 Almeida L. (ii115)  
 Almeida M. (ii19)  
 Almeida M.S. (ii73)  
 Almeida S. (ii115), (ii123)  
 Alves A.R. (ii72)  
 Amador A.F. (ii34), (ii100), (ii103)  
 Andrada I.D. (ii64)  
 Andrade A. (ii16), (ii53), (ii70), (ii111)  
 Andreea P. (ii51)  
 Andruskeviciute S. (ii24)  
 Andy Sascão R. (ii118)  
 Anfang V. (ii42)  
 Antunes A. (ii57), (ii95), (ii97), (ii106), (ii114)  
 Appiah J. (ii77)  
 Arachchilage D.R.J. (ii43)  
 Armstrong P.C. (ii26)  
 Arnaud (ii89)  
 Arnesen H. (ii5)  
 Arnoult (ii87), (ii88)  
 Azam S. (ii46)  
 Azevedo J. (ii53)  
 Azzahhafi J. (ii61), (ii93)  
 Baars M. (ii90)  
 Badimon L. (ii85)  
 Bahloul A. (ii8)  
 Balakhonova T. (ii1), (ii7)  
 Ballas C.H. (ii18)  
 Baltazar O. (ii78), (ii115)  
 Banaszkiwicz M. (ii58), (ii59)  
 Bapir M. (ii67)  
 Barmby D. (ii22)  
 Barradas M.I. (ii108)  
 Barwari T. (ii26)  
 Bashiardes E. (ii90)  
 Bei I. (ii121)  
 Belch J.J.F. (ii50)  
 Belkadi (ii87)  
 Beltran J. (ii14)  
 Benke K. (ii90)  
 Bento Â. (ii119)  
 Bentur O. (ii10)  
 Berg J.T. (ii61)  
 Bernlochner I. (ii13)  
 Bhupal V.S.R. (ii46)  
 Bianca C. (ii51)  
 Bil-Lula I. (ii58), (ii59)  
 Bjorck E. (ii90)  
 Boersma L.V.A. (ii86)  
 Boileau (ii89)  
 Bor W. (ii10), (ii93)  
 Borges S. (ii11), (ii12), (ii62)  
 Boukhris M. (ii74), (ii75)  
 Braga P. (ii23), (ii25), (ii66)  
 Bragança B. (ii16), (ii53), (ii70), (ii111)  
 Branca L. (ii86)  
 Brandão M. (ii23), (ii25), (ii66)  
 Bratseth V. (ii5)  
 Brazão A. (ii116)  
 Briosas A. (ii78)  
 Budianto W. (ii44)  
 Caboor L. (ii92)  
 Cabral C. (ii110)  
 Cabral J.M. (ii96)  
 Cabral M. (ii9), (ii17), (ii55), (ii56), (ii57), (ii95), (ii97), (ii102), (ii114), (ii117)  
 Cabrita A. (ii34), (ii100), (ii103)  
 Caires G. (ii116)  
 Caires J. (ii112)  
 Calé R. (ii30), (ii31), (ii78)  
 Calvão J. (ii34), (ii100), (ii103)  
 Camacho T. (ii112)  
 Campagnolo P. (ii67)  
 Campos D. (ii72)  
 Campos G. (ii72)  
 Campos I. (ii53), (ii111)  
 Campos I.G. (ii70)  
 Carmo F. (ii96)  
 Caruana M. (ii90)  
 Carvalho D. (ii17)  
 Carvalho J.F. (ii99)  
 Carvalho M. (ii9), (ii17), (ii55), (ii56), (ii57), (ii102), (ii103), (ii114)  
 Carvalho M.F. (ii95), (ii97)  
 Carvalho M.M. (ii34)  
 Carvalho M.M.F. (ii117)  
 Carvalho R. (ii55), (ii56), (ii102), (ii114)  
 Carvalho R.R. (ii95), (ii97), (ii117)  
 Cassama A. (ii98)  
 Castro A. (ii70)  
 Catanho T. (ii112)  
 Catrina B. (ii45)  
 Cavalca V. (ii36)  
 Cepas P.L. (ii86)  
 Cerqueira M. (ii99)  
 Chan M.V. (ii26)  
 Charfeddine S. (ii8)  
 Chaudhuri S. (ii46)  
 Chaves S. (ii112)  
 Chaziri I. (ii6)  
 Chenard P. (ii74), (ii75)  
 Chiminazzo V. (ii80)  
 Ciapiene I. (ii24)  
 Cilla M. (ii32)  
 Cláudio F. (ii21)  
 Câmara de Sá A.D. (ii106)  
 Codreanu A. (ii90)  
 Coelho C.G. (ii94)  
 Collaku L. (ii41)  
 Coller B. (ii10)  
 Conde I. (ii109)  
 Conway D. (ii22)  
 Cornet B.I. (ii51)  
 Correia J. (ii110)  
 Cortenbach K. (ii76)  
 Costa C. (ii34), (ii103)  
 Costa G. (ii3), (ii38), (ii72)  
 Costa J. (ii109)  
 Cotrim N. (ii30)  
 Couto D.S. (ii101), (ii105)  
 Cozma A. (ii65)  
 Cruz C. (ii34)  
 Cruz I. (ii16), (ii53), (ii70)  
 Cuellar-Calabria H. (ii79)  
 Cunha D. (ii115)  
 Cunha D.S. (ii78)  
 Cunha G. (ii3), (ii37), (ii38), (ii71), (ii72)  
 Cunha J. (ii10)  
 da Costa C.M. (ii100)  
 da Cruz I.M. (ii111)  
 Dana P. (ii64)  
 Davies S.W. (ii43)  
 de Almeida A.R. (ii20), (ii21)  
 de Araújo Gonçalves P. (ii71)  
 de Backer J. (ii90), (ii91), (ii92)  
 de Carvalho M.M. (ii100)  
 de Figueiredo M.G. (ii115), (ii123)  
 de Figueiredo M.P. (ii60)  
 de Jesus Banz M. (ii99)  
 de Jesus M. (ii54)  
 de Leeuw V. (ii91)  
 de Moya Rubio E. (ii90)  
 de Ruiten M. (ii76)  
 de Rycke K. (ii92)  
 de Sousa M.C. (ii119)  
 de Sousa P.J. (ii114)  
 Dekleva M. (ii27)  
 Del Río-García Á. (ii80), (ii81)  
 Delerue F. (ii30)  
 Delhomme (ii87)  
 Delia M. (ii65)  
 di Maio N. (ii93)  
 Dias L. (ii100)  
 Dimakopoulos G.E. (ii18)  
 Diogo A.C. (ii98)  
 Dirven M. (ii76)  
 Djamandi J. (ii41)  
 Dobrovolsky A. (ii1), (ii7)  
 Domanovits H. (ii33)  
 Domingues A.C. (ii99)  
 Dos Santos I.C. (ii48), (ii49)  
 Dourado R. (ii48), (ii49), (ii108)  
 Dousset B. (ii75)  
 Dragani A. (ii36)  
 Dračina N. (ii120)  
 Drumond A. (ii11), (ii12), (ii62)  
 Duarte F. (ii48), (ii49)  
 Duarte F.S. (ii108)  
 Duerschmied D. (ii42)  
 Dumfarth J. (ii90)  
 Dumitru Z. (ii64)  
 Duncan A. (ii43)  
 Dux-Santoy L. (ii32), (ii79), (ii84)  
 Earls J. (ii63)  
 Eibensteiner F. (ii33)  
 Elamin N. (ii22)  
 Eliahou (ii87), (ii88), (ii89)  
 Ellouze T. (ii8)  
 Evangelista A. (ii32), (ii79), (ii84), (ii90)  
 Evgeny L. (ii113)  
 Farag M.F. (ii4)  
 Faria R. (ii17)  
 Fazio G. (ii69)  
 Fernandes D. (ii3), (ii38), (ii72)  
 Fernandes F. (ii110)  
 Fernandes N. (ii112)  
 Fernandes R. (ii3), (ii37), (ii38), (ii72)  
 Fernandes S. (ii9), (ii55), (ii56), (ii102), (ii114)  
 Fernandes S.L. (ii95), (ii97), (ii117)  
 Fernández M.M. (ii80), (ii81)  
 Ferreira B. (ii78)  
 Ferreira F. (ii30), (ii31), (ii78), (ii115)  
 Ferreira G.R.M. (ii110)  
 Ferreira J. (ii29), (ii38), (ii71), (ii73)  
 Ferreira J.B. (ii57)  
 Ferreira J.M. (ii72)  
 Ferreira M. (ii30), (ii31)  
 Ferreira N. (ii17), (ii23)  
 Ferreira R.C. (ii63)  
 Ferreira W. (ii17), (ii23)  
 Ferreira-Gonzalez I. (ii32), (ii79), (ii84)  
 Fevereiro S. (ii71)  
 Figueiredo L. (ii63)  
 Figueiredo M. (ii21), (ii123)  
 Fitton C.A. (ii50)  
 Fiuza J. (ii110)  
 Flores R. (ii109)  
 Florina F. (ii64)  
 Fonseca A.G. (ii30)  
 Fontes-Carvalho R. (ii23), (ii25), (ii66)  
 Freitas A.I. (ii62)  
 Freitas D. (ii116)  
 Freitas S. (ii11), (ii12), (ii62)  
 Freixa X. (ii86)  
 Galian L. (ii32), (ii84)  
 Galian-Gay L. (ii79)

- Ganea A. (ii65)  
 Garcia-Duran A. (ii79)  
 Gargouri R. (ii8)  
 Garrido-Oliver J. (ii32), (ii79), (ii84)  
 Gasnier A. (ii74)  
 Gawaz M. (ii13)  
 Ghrab A. (ii8)  
 Giannou S.O. (ii18)  
 Giaretta A. (ii36)  
 Gibson C. (ii10)  
 Gisca E. (ii30)  
 Gjata M. (ii41)  
 Gjermeni D. (ii42)  
 Golubović M. (ii120)  
 Gomes A. (ii30), (ii31)  
 Gomes A.R. (ii72)  
 Gomes D. (ii71), (ii73)  
 Gomes F. (ii115)  
 Gonçalves C. (ii9), (ii95), (ii97), (ii117)  
 Gonçalves C.M. (ii55), (ii56), (ii99), (ii102)  
 Gonçalves F. (ii3), (ii37), (ii38), (ii124)  
 Gonçalves H. (ii66)  
 Gonçalves L. (ii3), (ii37), (ii38), (ii72), (ii124)  
 Gonzalez F. (ii31)  
 Gonzalez-Alujas T. (ii84)  
 Gorog D.A. (ii4), (ii40), (ii43)  
 Gourceyrol A. (ii74)  
 Gouya (ii89)  
 Graça C. (ii112)  
 Granger C. (ii10)  
 Grilo V. (ii30)  
 Groenink M. (ii90)  
 Guala A. (ii32), (ii79), (ii84)  
 Guardado J. (ii95), (ii97), (ii117)  
 Gue Y. (ii35)  
 Gue Y.X. (ii4), (ii40)  
 Guerra G. (ii62)  
 Guerreiro C. (ii23), (ii25), (ii66)  
 Guimarães J. (ii3), (ii38), (ii72)  
 Gunn J.P. (ii22)  
 Gutierrez L. (ii79), (ii84)  
 Gutmann C. (ii26)  
 Habib A. (ii36)  
 Hall I. (ii22)  
 Hammami R. (ii8)  
 Hanna (ii89)  
 Hanson J. (ii22)  
 Hasan O.M. (ii46)  
 Hatem D. (ii36)  
 Hein-Rothweiler R. (ii13)  
 Heiss C. (ii67)  
 Henriques E. (ii11), (ii12), (ii62)  
 Hesselbarth D. (ii42)  
 Hesselink J.R. (ii90)  
 Higginson E. (ii107)  
 Hoxha E. (ii41)  
 Ilchyshyn N. (ii78)  
 Inês Barradas M. (ii48), (ii49)  
 Ioachim P.M. (ii64)  
 Ioannou M. (ii6)  
 Iqbal J. (ii22)  
 Jabeur M. (ii8)  
 Jacinto S. (ii63)  
 Jadoui (ii87)  
 Januário F. (ii57)  
 Jeelani M.S. (ii47)  
 Jenniskens S. (ii76)  
 Johnson K. (ii79), (ii84)  
 Jondeau G. (ii87), (ii88), (ii89), (ii90)  
 Joshi A. (ii26)  
 Jouadi (ii89)  
 Judas T. (ii30), (ii31)  
 Juelch C. (ii42)  
 Junco-Vicente A. (ii81)  
 Kallenbach K. (ii90)  
 Kalogeras P.E. (ii18)  
 Kalstad A.A. (ii5)  
 Kanji R. (ii4), (ii40), (ii43)  
 Kanjilal S. (ii46)  
 Kardakari O.L. (ii18)  
 Kastrati A. (ii13)  
 Kateryna M. (ii113)  
 Katsouras C.S. (ii18)  
 Kempers M. (ii90)  
 Keravnu A. (ii90)  
 Kharche P. (ii46)  
 Kiechl S. (ii26)  
 Komarov A. (ii1), (ii7)  
 Konstantinidis A.T.H. (ii18)  
 Korac N. (ii27)  
 Korobkova V. (ii7)  
 Krishnamurthy A. (ii22)  
 Krivosheeva E. (ii1), (ii7)  
 Krzywonos-Zawadzka A. (ii59)  
 Kuka S. (ii41)  
 Kumar P.R. (ii46)  
 Kuriakose J. (ii47)  
 Ladeiras-Lopes R. (ii17)  
 Lahu\* S. (ii13)  
 Lakkas L.A. (ii18)  
 Lambrinou E.K. (ii18)  
 Lansac (ii88)  
 Laugwitz K.-L. (ii13)  
 Lazar A. (ii65)  
 Leça S. (ii116)  
 Lebreiro A. (ii103)  
 Leggewie S. (ii42)  
 Leiva V.V.G. (ii104)  
 Lentza M.-E. (ii121)  
 Leonidou E. (ii6)  
 Lesauskaite V. (ii24)  
 Lim A.U.Y. (ii54)  
 Lima M.R. (ii19)  
 Lim-Cooke M.-S. (ii77)  
 Lobatto R. (ii10)  
 Loeys B. (ii90)  
 Logghe G. (ii91)  
 Lohmann C. (ii31)  
 Lopes J. (ii37)  
 Lopes P. (ii98)  
 Lopes R. (ii16), (ii53), (ii111)  
 Lopes R.G. (ii70)  
 Lopes V. (ii3), (ii37), (ii38), (ii72)  
 Lopes V.F.d.S. (ii124)  
 Loureiro C. (ii72)  
 Loureiro M.F. (ii9)  
 Loureiro M.J. (ii31), (ii78)  
 López S. (ii85)  
 López-Larrea C. (ii80)  
 Lu M. (ii77)  
 Luís J. (ii94)  
 Luscher T.F. (ii43)  
 Luz A. (ii101), (ii105)  
 Luz J. (ii115)  
 Luz J.M. (ii78)  
 Macedo F. (ii34), (ii100), (ii103)  
 Machado C. (ii48), (ii49), (ii108)  
 Mackley R. (ii39)  
 Magalhães L. (ii96)  
 Makni A. (ii8)  
 Malinescu V. (ii65)  
 Mallek S. (ii8)  
 Maly M. (ii52)  
 Mani N. (ii61)  
 Manousiadis K. (ii121)  
 Marcu M.T.D. (ii118)  
 Marinho A. (ii101), (ii105)  
 Marinho V. (ii3), (ii37), (ii38)  
 Marmelo B. (ii110)  
 Marques C. (ii34), (ii100), (ii103)  
 Marques H. (ii63)  
 Marques J. (ii109)  
 Martinez M. (ii54)  
 Martinho M. (ii30), (ii31), (ii78)  
 Martinho S. (ii72)  
 Martins C. (ii31)  
 Martins D. (ii48), (ii49), (ii108)  
 Martins H. (ii56), (ii102)  
 Martins P. (ii72)  
 Martins V.P. (ii94)  
 Martínez M. (ii32)  
 Masi (ii88)  
 Massberg S. (ii13)  
 Mayer K. (ii13)  
 Mayr M. (ii26)  
 Medeiros P. (ii109)  
 Meek J. (ii76)  
 Melica B. (ii23), (ii25), (ii66)  
 Memtsas V.P. (ii40)  
 Mendes M. (ii19), (ii29), (ii71), (ii73)  
 Mendes S.L. (ii94)  
 Mendonça M.I. (ii11), (ii12), (ii62)  
 Mendonça T. (ii63)  
 Meskauskaite U. (ii24)  
 Michalis L.K. (ii18)  
 Middle J. (ii22)  
 Mihaela M. (ii65)  
 Milleron (ii87), (ii88), (ii89)  
 Milner J. (ii3), (ii37), (ii38)  
 Mirsadraee S.S. (ii43)  
 Münch G. (ii13)  
 Mohaissen T. (ii28)  
 Mohamedi Y. (ii80)  
 Moine B. (ii87)  
 Molié C.D. (ii74)  
 Molnár T. (ii15)  
 Monteiro E. (ii3), (ii38), (ii72)  
 Monteiro J.P. (ii70)  
 Monteiro P. (ii3), (ii37), (ii38)  
 Monteiro S. (ii3), (ii37), (ii38)  
 Morais J. (ii9), (ii55), (ii56), (ii57), (ii95), (ii97), (ii99), (ii102), (ii114), (ii117)  
 Moreira N. (ii3), (ii37), (ii38), (ii124)  
 Morgado G. (ii31)  
 Morgan K. (ii22)  
 Morris P. (ii22)  
 Moris C. (ii81)  
 Mosquera L.M. (ii90), (ii91)  
 Mouzarou A. (ii6)  
 Moyle B. (ii22)  
 Mpouratzis B.A. (ii18)  
 Mt A. (ii46)  
 Mundhekar A. (ii46)  
 Muñoz A.R. (ii32), (ii79)  
 Musabelliu J. (ii41)  
 Mutch N.J. (ii4)  
 Myhr P.L. (ii5)  
 Myroslava D. (ii113)  
 Nagi E. (ii90)  
 Naka K.K. (ii18)  
 Nóbrega J.J. (ii112)  
 Nóbrega L. (ii100)  
 Ndrepepa G. (ii13)  
 Nelson T.A. (ii22)  
 Neto V. (ii110)  
 Neves D. (ii21)  
 Neves J. (ii71)  
 Nistri S. (ii90)  
 Oana S. (ii45), (ii51)  
 Oblinado M. (ii91)  
 Ok K.B. (ii68)  
 Oleh Y. (ii113)  
 Olejnik A. (ii58), (ii59)  
 Oliveira A.F. (ii19)  
 Oliveira C. (ii34), (ii100), (ii103), (ii109)  
 Oliveira F. (ii101), (ii105)  
 Oliveira I. (ii16), (ii111)  
 Oliveira I.P. (ii53), (ii70)  
 Oliveira J. (ii23)  
 Oliveira L. (ii48), (ii49), (ii108)  
 Oliveira M. (ii66)  
 Olivier C.B. (ii42)  
 Oppenauer J. (ii33)  
 Ornelas I. (ii11), (ii12), (ii62)  
 Ou (ii88)  
 Ouadi O. (ii88)  
 Ouali O. (ii89)  
 Ow K.W. (ii22)  
 Pais J. (ii60)  
 Paiva M.S. (ii71)  
 Palma Dos Reis R. (ii62)  
 Panchenko E. (ii1), (ii7)  
 Panoulas V.F. (ii43)  
 Panourgia M. (ii121)  
 Papaioannou E.F. (ii18)  
 Papakonstantinou P.E. (ii121)  
 Paray N.B. (ii47)  
 Parker W.A.E. (ii22)  
 Passos D. (ii112)  
 Patel R. (ii76)  
 Patrono C. (ii36)  
 Paul (ii88)  
 Paula S. (ii115)  
 Paz Driotes D.E. (ii104)  
 Peña E. (ii32)

- Pellenc (ii88)  
 Pepe G. (ii90)  
 Peper J. (ii93)  
 Pereira A.R. (ii31), (ii78)  
 Pereira E. (ii31)  
 Pereira H. (ii30), (ii31), (ii78)  
 Pereira V. (ii98)  
 Pernencar S. (ii9)  
 Petrucci G. (ii36)  
 Piçarra B. (ii60), (ii119)  
 Pinho A. (ii34), (ii103)  
 Pinho A.I. (ii100)  
 Pinto R. (ii100), (ii103)  
 Pinto R.A. (ii100)  
 Pinto R.J.R.A. (ii34)  
 Pires C.M. (ii109)  
 Pires I. (ii110)  
 Pires-Morais G. (ii23), (ii25), (ii66)  
 Pitta M.L. (ii94)  
 Polzin A. (ii86)  
 Porro B. (ii36)  
 Posas F.E. (ii54)  
 Postma S. (ii10)  
 Prakash S. (ii76)  
 Presume J. (ii29), (ii73)  
 Preveden A. (ii120)  
 Primo J. (ii66)  
 Proença T. (ii34), (ii100), (ii103)  
 Puia A. (ii45)  
 Póvoa J. (ii98)  
 Queirós C. (ii16)  
 Queirós P.R. (ii25), (ii66)  
 Quintal J. (ii98)  
 Quintal J.J.S. (ii112)  
 Radajewska A. (ii58)  
 Raffoul (ii87), (ii88)  
 Raluca I. (ii65)  
 Ramos R. (ii63)  
 Ranalli P. (ii36)  
 Raposo L. (ii19)  
 Rayhi S. (ii93)  
 Redžek A. (ii120)  
 Reis J.F. (ii63)  
 Reis R.P.D. (ii11), (ii12)  
 Repolho D. (ii31), (ii78)  
 Réger B. (ii15)  
 Ribeiras R. (ii29)  
 Ribeiro Mané F.G. (ii109)  
 Ribeiro R.F. (ii99)  
 Richardson J. (ii22)  
 Rijo D. (ii112)  
 Rikken S.A.O.F. (ii10)  
 Riksen N. (ii76)  
 Rista E. (ii41)  
 Rocca B. (ii36)  
 Rocca D.G.D. (ii86)  
 Rocha B.M.L. (ii71)  
 Rocha R. (ii21)  
 Rodríguez I. (ii80), (ii81)  
 Rodrigues A. (ii23), (ii25), (ii66)  
 Rodrigues I. (ii23)  
 Rodrigues J.M. (ii116)  
 Rodrigues M. (ii11), (ii12), (ii62)  
 Rodrigues R. (ii116)  
 Rodrigues R.A. (ii100)  
 Rodrigues-Díez R. (ii80)  
 Rodríguez-Palomares J. (ii32), (ii79), (ii84)  
 Rodwell L. (ii76)  
 Rolle-Sóñora V. (ii81)  
 Ropers (ii89)  
 Rosa J.B. (ii72)  
 Rothman A. (ii22)  
 Ruivo C. (ii9), (ii57), (ii114)  
 Ruiz-Muñoz A. (ii84)  
 Ruiz-Ortega M. (ii80)  
 Ruml T. (ii52)  
 Sá D. (ii11), (ii12), (ii62), (ii116)  
 Sakai L. (ii91)  
 Samara I.O. (ii18)  
 Sampaio F. (ii23)  
 Santos A.R. (ii60)  
 Santos H. (ii123)  
 Santos I.C.d. (ii108)  
 Santos J. (ii14)  
 Santos J.G. (ii78)  
 Santos J.M. (ii110)  
 Santos L. (ii23), (ii25), (ii34), (ii66), (ii103)  
 Santos L.D. (ii100)  
 Santos M. (ii11), (ii12), (ii62), (ii116), (ii123)  
 Santos M.R. (ii71), (ii106)  
 Santos P. (ii31)  
 Santos R. (ii16), (ii57), (ii111)  
 Santos R.R. (ii71)  
 Santos-Ferreira D. (ii25), (ii66)  
 Sanyal J. (ii46)  
 Sao-Aviles A. (ii32), (ii84)  
 Saraiva F. (ii55), (ii56), (ii102)  
 Saraiva M. (ii94)  
 Schiller T. (ii39)  
 Schlager O. (ii33)  
 Schnaubelt S. (ii33)  
 Schrick D. (ii15)  
 Schulte C. (ii26)  
 Segers P. (ii91)  
 Seljeflot I. (ii5)  
 Serrão G. (ii116)  
 Setiawan B. (ii44)  
 Shah J. (ii46)  
 Siaravas K.O. (ii18)  
 Sideris A. (ii121)  
 Silva B. (ii106), (ii116)  
 Silva G.F. (ii112)  
 Silva G.S. (ii23), (ii25), (ii66)  
 Silva M.R. (ii23), (ii25), (ii66)  
 Silva R. (ii109)  
 Silveira J. (ii101)  
 Singh B. (ii26)  
 Singh S.B. (ii46)  
 Sioros S.P. (ii18)  
 Sips P. (ii91), (ii92)  
 Skene S.S. (ii67)  
 Solache-Berrocal G. (ii81)  
 Solheim S. (ii5)  
 Sousa A.C. (ii11), (ii12), (ii62)  
 Sousa J.A. (ii106), (ii112)  
 Sousa J.P. (ii37)  
 Sousa M.C. (ii21)  
 Sousa-Uva M. (ii71)  
 Spinthakis N. (ii47)  
 Spoon D. (ii86)  
 Sporis D. (ii65)  
 Stamou I.L. (ii18)  
 Stampanoni M. (ii91)  
 Storey R.F. (ii22)  
 Stránská M. (ii52)  
 Stătescu C. (ii118)  
 Suárez-Álvarez B. (ii80)  
 Szabo S. (ii42)  
 Szabolcs Z. (ii90)  
 Tachmetzidi-Papoutsis D. (ii121)  
 Takeuchi H. (ii82), (ii83)  
 Tatarunas V. (ii24)  
 Tavares A. (ii48)  
 Tchitchinadze (ii89)  
 Teixeira R. (ii63)  
 Teixeira T. (ii114)  
 Teixido G. (ii90)  
 Teixido-Turà G. (ii32), (ii79), (ii84)  
 Tejera-Muñoz A. (ii80)  
 Temtem A.M.d.A. (ii116)  
 Temtem M. (ii11), (ii12), (ii62), (ii106)  
 Ten Berg J. (ii10)  
 Ten Berg J.M. (ii93)  
 Teodoru M. (ii45)  
 Theofilatos K. (ii26)  
 Timmermans J. (ii90)  
 Titaeva E. (ii1), (ii7)  
 Todić M. (ii120)  
 Tokés-Füzesi M. (ii15)  
 Torres S. (ii101), (ii105)  
 Trabulo M. (ii71)  
 Tremoli E. (ii36)  
 Trenk D. (ii42)  
 Triki F. (ii8)  
 Trinca M. (ii21), (ii119)  
 Tripoten M. (ii7)  
 Tveit A. (ii5)  
 Uva M.S. (ii73)  
 Valente F. (ii79), (ii84)  
 Van de Laar I. (ii90)  
 Van Den Broek W.W.A. (ii61)  
 Van Der Sange N.M.R. (ii93)  
 Van Impe M. (ii91)  
 Van Kimmenade R. (ii90)  
 Van Kimmenade R.R.J. (ii76)  
 Van 't Hof A.W.J. (ii10)  
 Vanhomwegem M. (ii91)  
 Vaughan C. (ii107)  
 Vazão A. (ii55), (ii56), (ii99), (ii102)  
 Veiga R. (ii17)  
 Vermassen P. (ii92)  
 Verstraeten A. (ii90)  
 Vetter H.T. (ii42)  
 Viegas J.M. (ii63)  
 Viktorová J. (ii52)  
 Vilahur G. (ii85)  
 Viro P. (ii74), (ii75)  
 Von Kodolitsch Y. (ii90)  
 Warlo E.M.K. (ii5)  
 Warner T.D. (ii26)  
 Wieven O. (ii79), (ii84)  
 Willeit J. (ii26)  
 Yosofi B. (ii76)  
 Zagoni C. (ii45)  
 Zampelaki A. (ii26)  
 Zdravković R. (ii120)  
 Zheng K. (ii10)  
 Zheng K.L. (ii2)  
 Zoreslava L. (ii113)